



**HAL**  
open science

## Pyogenic sacroiliitis in a 13-month-old child a case report and literature review

Julien Leroux, Isabelle Bernardini, Lucie Grynberg, Claire Grandguillaume, Paul Michelin, Mourad Ould Slimane, Eric Nectoux, François Deroussen, Richard Gouron, Audrey Angelliaume, et al.

### ► To cite this version:

Julien Leroux, Isabelle Bernardini, Lucie Grynberg, Claire Grandguillaume, Paul Michelin, et al.. Pyogenic sacroiliitis in a 13-month-old child a case report and literature review. *Medicine*, 2015, 94 (42), 10.1097/MD.0000000000001581 . hal-02527566

**HAL Id: hal-02527566**

**<https://hal.univ-lille.fr/hal-02527566v1>**

Submitted on 1 Apr 2020

**HAL** is a multi-disciplinary open access archive for the deposit and dissemination of scientific research documents, whether they are published or not. The documents may come from teaching and research institutions in France or abroad, or from public or private research centers.

L'archive ouverte pluridisciplinaire **HAL**, est destinée au dépôt et à la diffusion de documents scientifiques de niveau recherche, publiés ou non, émanant des établissements d'enseignement et de recherche français ou étrangers, des laboratoires publics ou privés.



Distributed under a Creative Commons Attribution 4.0 International License

# Pyogenic Sacroiliitis in a 13-Month-Old Child

## *A Case Report and Literature Review*

Julien Leroux, MD, PhD, Isabelle Bernardini, MS, Lucie Grynberg, MS, Claire Grandguillaume, MD, Paul Michelin, MD, Mourad Ould Slimane, MD, Eric Nectoux, MD, François Deroussen, MD, Richard Gouron, MD, PhD, Audrey Angelliaume, MS, Brice Ilharberde, MD, PhD, and Mariette Renaux-Petel, MD

**Abstract:** Pyogenic sacroiliitis is exceptional in very young children. Diagnosis is difficult because clinical examination is misleading. FABER test is rarely helpful in very young children. Inflammatory syndrome is frequent. Bone scintigraphy and MRI are very sensitive for the diagnosis. Joint fluid aspiration and blood cultures are useful to identify the pathogen. Appropriate antibiotic therapy provides rapid regression of symptoms and healing. We report the case of pyogenic sacroiliitis in a 13-month-old child.

Clinical, biological, and imaging data of this case were reviewed and reported retrospectively.

A 13-month-old girl consulted for decreased weight bearing without fever or trauma. Clinical examination was not helpful. There was an inflammatory syndrome. Bone scintigraphy found a sacroiliitis, confirmed on MRI. Aspiration of the sacroiliac joint was performed. Empiric intravenous antibiotic therapy was started. Patient rapidly recovered full weight bearing. On the 5th day, clinical examination and biological analysis returned to normal. Intravenous antibiotic therapy was switched for oral. One month later, clinical examination and biological analysis were normal and antibiotic therapy was stopped.

Hematogenous osteoarticular infections are common in children but pyogenic sacroiliitis is rare and mainly affects older children. Diagnosis can be difficult because clinical examination is poor. Moreover, limping and decreased weight bearing are very common reasons for consultation. This may delay the diagnosis or refer misdiagnosis. Bone scintigraphy is useful to locate a bone or joint disease responsible for limping. In this observation, bone scintigraphy located the infection

at the sacroiliac joint. Given the young age, MRI was performed to confirm the diagnosis. Despite the very young age of the patient, symptoms rapidly disappeared with appropriate antibiotic therapy.

We report the case of pyogenic sacroiliitis in a 13-month-old child. It reminds the risk of misdiagnosing pyogenic sacroiliitis in children because it is exceptional and clinical examination is rarely helpful. It also highlights the usefulness of bone scintigraphy and MRI in osteoarticular infections in children.

(*Medicine* 94(42):e1581)

**Abbreviations:** FABER test = pain caused or exacerbated at the sacroiliac joint when positioning the contralateral hip in flexion (F), abduction (AB) and external rotation (ER), MRI = magnetic resonance imaging, PCR = protein C reactive, SPECT = single-photon emission computed tomography.

## INTRODUCTION

Pyogenic sacroiliitis is an osteoarticular infection particularly rare in children and exceptional in very young children. It reaches then preferably older children.<sup>1-5</sup>

Clinical presentation may be poor and misleading, especially in young children, so that diagnosis can be difficult.<sup>6</sup> Most often, children consult for pain or functional impairment. Fever is inconstant. The most sensitive clinical sign is the FABER test: pain is caused or exacerbated at the sacroiliac joint when positioning the contralateral hip in flexion (F), abduction (AB), and external rotation (ER).<sup>3,7</sup>

There is most often an inflammatory syndrome with moderate increased protein C reactive (PCR).

X-rays are usually normal.<sup>6</sup>

Bone scintigraphy and magnetic resonance imaging (MRI) are particularly sensitive for the diagnosis of sacroiliitis but MRI has the advantage of being helpful to search an abscess that should be drained.<sup>4,5,8-14</sup>

Joint fluid aspiration and blood cultures are useful to identify the pathogen.<sup>1,7</sup> *Staphylococcus aureus* is the main pathogen responsible for pyogenic sacroiliitis.<sup>1</sup>

Appropriate antibiotic therapy provides rapid regression of symptoms and healing.<sup>8</sup> This observation reports a rare case of pyogenic sacroiliitis in a very young child. It focuses on difficulties to make the diagnosis in young children, reminds the risk of misdiagnosis, and highlights the usefulness of bone scintigraphy and MRI in osteoarticular infection in children.

No ethical approval was necessary since we report a retrospective case report but informed consent was given by parents.

## CASE REPORT

A 13-month-old girl consulted the pediatric emergency for decreased weight bearing on her right lower limb worsening for

Editor: Victor Asensi.

Received: July 8, 2015; revised: August 18, 2015; accepted: August 20, 2015.

From the Clinique Chirurgicale Infantile, CHU de Rouen, Hôpital Charles Nicolle, Rouen cedex (JL, IB, LG, MR-P); Université de Rouen, Mont-Saint-Aignan (JL, IB, LG, CG, MR-P, MOS); Département d'Anesthésie et Réanimation, CHU de Rouen, Hôpital Charles Nicolle (CG); Service de Radiologie, CHU de Rouen, Hôpital Charles Nicolle (PM); Service de Chirurgie Orthopédique et Traumatologique, CHU de Rouen, Hôpital Charles Nicolle, Rouen cedex (MOS); Service de Chirurgie et d'Orthopédie de l'Enfant, CHRU de Lille, Lille cedex (EN); Université Lille 2 Droit et Santé, Lille (EN); Service de Chirurgie de l'Enfant, CHU Amiens-Picardie site sud, Amiens cedex 1 (FD, RG); Université de Picardie, Amiens (FD, RG); Service de Chirurgie Infantile, CHU de Bordeaux, Hôpital des Enfants, place Amélie Raba-Léon Bordeaux (AA); Université de Bordeaux, Collège Sciences de la Santé, Bordeaux cedex (AA); Service d'Orthopédie Pédiatrique, Assistance Publique des Hôpitaux de Paris, Hôpital Robert Debré, Paris (BI); and Université Paris Diderot Paris 7, Paris, France (BI). Correspondence: Julien Leroux, Clinique Chirurgicale Infantile, Hôpital Charles Nicolle, 1 rue de Germont, 76031 Rouen cedex, France (e-mail: Julien.Leroux@chu-rouen.fr).

The authors have no funding and conflicts of interest to disclose.

Copyright © 2015 Wolters Kluwer Health, Inc. All rights reserved.

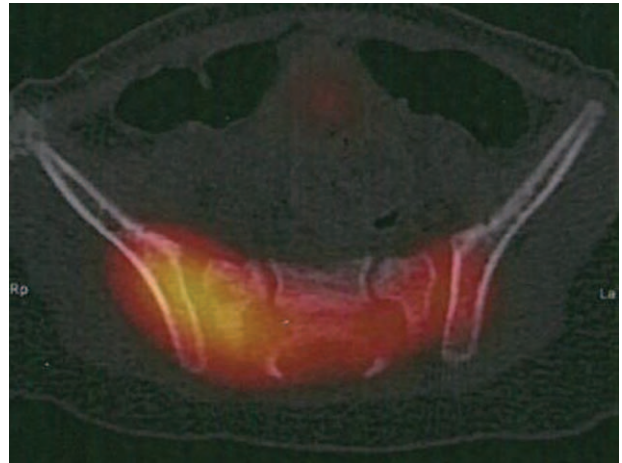
This is an open access article distributed under the Creative Commons Attribution License 4.0, which permits unrestricted use, distribution, and reproduction in any medium, provided the original work is properly cited. ISSN: 0025-7974

DOI: 10.1097/MD.0000000000001581



**FIGURE 1.** Posterior view of bone scintigraphy. Hypermetabolism of the right sacroiliac joint.

4 days without fever or trauma. She had no noticeable antecedent. Temperature was 37.6°C. There was neither reduction of range of motion of hips or knees, nor pain on palpation of femoral or tibial metaphysis, nor spinal stiffness. The FABER

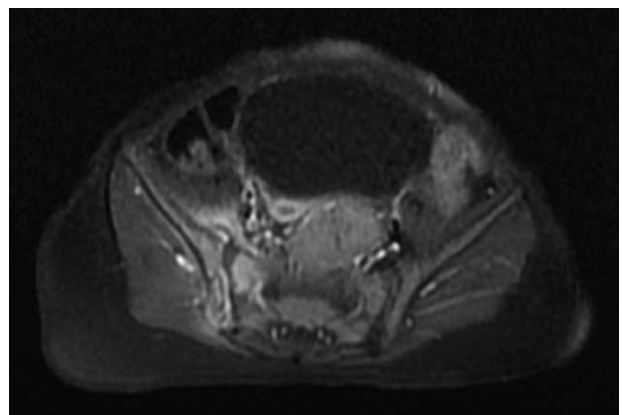


**FIGURE 2.** Axial view of SPECT. Hypermetabolism of the right sacroiliac joint.

test did not provide information given the very young age of the patient. Antero-posterior (AP) X-ray of the pelvis was normal. Biology found an inflammatory syndrome with a PCR = 38 mg/L and leukocytes = 18.8 G/L with 47% of polynuclear neutrophils.

Because of the functional impairment, the inflammatory syndrome, and the absence of painful site, a bone scintigraphy (Fig. 1) completed with a single-photon emission computed tomography (SPECT) (Fig. 2) was performed and found a right sacroiliitis. Given the young age of the patient, an MRI was performed to confirm the diagnosis. Inflammation of ilium and sacrum on each side of the right sacroiliac joint and effusion were suggestive of sacroiliitis (Fig. 3). An aspiration of the right sacroiliac joint was performed to try to identify the pathogen. An empiric intravenous biantibiotic therapy with cefotaxim and gentamycin was started. The next day, the patient recovered full weight bearing on the right lower limb. Bacteriological analysis found a *Staphylococcus aureus* susceptible to methicillin.

On the 5th day, clinical examination was normal and there was no inflammatory syndrome with a PCR <5 mg/L. Intravenous antibiotic therapy was switched for oral antibiotic therapy



**FIGURE 3.** Axial T1 weighted with gadolinium of the pelvis. Hyperintense signal of ilium and sacrum on each side of the right sacroiliac joint and effusion (more noticeable at the anterior aspect of the sacroiliac joint) are typical of sacroiliitis.

**TABLE 1.** History, Clinical Findings, Imagery, Biology, Bacteriology, Treatment, and Outcome of 78 Children With Pyogenic Sacroiliitis, Based on a Recent Review of Literature

	Taylor et al. <sup>5</sup>	Pérez et al. <sup>18</sup>	Wada et al. <sup>16</sup>	Wu et al. <sup>17</sup>	Ford et al. <sup>2</sup>	Letts et al. <sup>19</sup>	Vic et al. <sup>20</sup>	Tokuda et al. <sup>4</sup>	Lenfant et al. <sup>3</sup>	Aprin et al. <sup>7</sup>	Sueoka et al. <sup>4</sup>
Year	2010	2008	2008	2007	2004	1999	1998	1997	1997	1993	1985
Number of patients	15	1	8	11	1	1	1	11	11	7	2
Patients	10.5 [8.1–13]	4	11.3 [4.3–15.3]	10.8 [NR]	12	11.5	11	12.8 [10 mths–16]	7.75 [12 mths–14]	9.5 [2–16]	1 [9–15 mths]
Age (yr)	NR	1/0	5/3	6/5	0/1	NR	0/1	NR	7/4	2/5	0/2
Male/female	NR	1/0	6/2	9/4 (2 bilateral)	0/1	0/1	1/0	NR	NR	NR	1/1
Right/left	NR	NR	0	2	NR	NR	NR	NR	NR	7	NR
History											
Predisposing condition		1									
Abortion		1									
Respiratory infection				2						1	
Preceding trauma										2	
Leukemia										2	
Skin lesion										1	
Injection in the buttock										1	
Onset to presentation (days)	NR	2	7 [4–10]	NR	2	4	2	NR	NR [2–2 yrs]	14 [4–28]	4.5 [2–7]
Clinical feature	NR	37.7	38.2 [36.8–39.3]	Fever in 11	38.8	38.1	39	Fever in 20	38.4 [37–40]	38.2 [37.2–39]	38.6 [38.3–38.9]
Temperature (°C)	NR	1	8	10	1	1	1	20	11	7	2
Pain	NR	NR									
Functional status	NR	0	8	10	1	0	0	NR	11	7	NA
Limp	NR	1	0	0	0	1	1	NR	0	0	NA
Inability to walk	NR	NR	7/8	NR	NR	NR	NR	NR	11/11	7/7	NR
FABER test (+/realized)	NR	NR									
Biology											
ESR (mm/hr)	NR	31	58 [35–84]	NR	NR	50	53	68 [6–130]	64 [21–115]	58 [39–84]	59.5 [56–63]
PCR (mg/L)	NR	8	114 [30–190]	NR	198	NR	110	113.5 [25–219]	NR	NR	NR
IMAGERY											
X-rays (+/realized)	NR	NR	0/8	2/11	0/1	0/1	0/1	NR	9/11	1/7	0/2
CT (+/realized)	NR	1/1	NR	0/1	NR	NR	NR	6/11	5/5	5/7	NR
MRI (+/realized)	NR	1/1	8/8	0/1	NR	NR	NR	6/6	NR	NR	NR
Bone scintigraphy (+/realized)	NR	NR	NR	9/11	1/1	1/1	1/1	16/16	11/11	6/7	2/2
Bacterio											
Blood culture (+/realized)	5/15	1/1	3/8	5/11	1/1	1/1	1/1	9/NR	3/11	4/7	NR
Joint fluid (+/realized)	3/4	0	0	0	1/1	0	0	1/NR	1/2	2/2	1/1
Pathogen											
Staphylococcus aureus	7		3	4	1 (Methi S)			9	2	4	
Staphylococcus epidermidis											1
Streptococcus pneumoniae		1					1	1	1	1	
Streptococcus groups A											
Citrobacter freundii				1							
Salmonella spp.								1	1	1	
Escherichia coli											
Other	1										
Treatment											
Antibiotherapy (days)											
Intravenous	49 [28–90] (IV + PO)	32	29 [16–34]	NR [14–42]	17	NR	15	20.9 [10–48]	21 [NR]	21 [NR]	21 [14–28]
Oral		14	32 [28–38]	NR [14–21]	42	NR	28	NR	90 [NR]	21 [NR]	14 [0–28]
Incision and drainage	2	0	0	0	0	0	0	0	5	2	0
Cast immobilization	0	0	0	0	0	0	1	0	6	0	0

TABLE 1. (Continued)

	Taylor et al. <sup>15</sup>	Pérez et al. <sup>18</sup>	Wada et al. <sup>16</sup>	Wu et al. <sup>17</sup>	Ford et al. <sup>2</sup>	Letts et al. <sup>19</sup>	Vic et al. <sup>20</sup>	Tokuda et al. <sup>4</sup>	Lenfant et al. <sup>3</sup>	Aprin et al. <sup>7</sup>	Sueoka et al. <sup>14</sup>
Outcome											
Last follow-up delay (mo)	NR [1–12] (N = 8/15)	NR	1.6 [4.8–36]	NR	NR	NR	3	NR	50 [8–99]	39 [6–71]	NR
Ambulatory	8/8		8			1	1		11	7	
Activity											
Full	7/8	NR	8	NR	NR	1	1	NR	11	7	NR
Limitation	1/8	NR	0	NR	NR	0	0	NR	0	0	NR
X-rays abnormalities	NR	NR	NR	NR	NR	NR	NR	NR	8	4	NR
Relapse	0	NR	0	0	NR	0	0	7	0	0	NR

CT = computed tomography; ESR = erythrocyte sedimentation rate; FABER test = pain caused or exacerbated at the sacroiliac joint when positioning the contralateral hip in flexion (F), abduction (AB), and external rotation (ER); IV = intravenous; Methi S = susceptible to methicillin; MRI = magnetic resonance imaging; mths = months; N = number; NR = not reported; PCR = protein C reactive; PO = oral; yrs = years.

with amoxicillin and clavulanic acid for 4 weeks. At 1 month of starting the treatment, clinical examination and biological analysis were normal and antibiotic therapy was stopped.

DISCUSSION AND REVIEW OF LITERATURE

In 1980, Schaad et al made a large review of literature about pyogenic sacroiliitis in 77 children. But nowadays, pathogens, imagery, and treatment have changed so that we realized a new review of cases and series published since 1980 to discuss this report. We find 11 articles that represent 78 patients (Table 1).<sup>2–4,7,14–20</sup>

While hematogenous osteoarticular infections are common in children, pyogenic sacroiliitis is specially rare and mainly affects older children.<sup>1–5</sup> It is quite exceptional at the age of 13 months. Only 3 cases of pyogenic sacroiliitis in children younger than 13 years have been reported in our review of the literature. They were aged of 9, 10, and 12 months.<sup>3,4,14</sup>

Onset to presentation of our patient was 4 days. It is likely similar to the delay we found in the literature since most patients consulted between 2 and 7 days after the beginning of the symptoms. The patient of the series of Lenfant et al<sup>3</sup> who presented at 2 years had been unsuccessfully treated in another hospital before. It seems that the early age of our patient did not delay the onset to presentation.

In very young children, clinical and epidemiological characteristics complicate the diagnosis. Indeed, clinical examination is particularly difficult and sometimes does not help the clinician, particularly when the child does not speak yet. FABER test is rarely feasible. Moreover, children with pyogenic sacroiliitis consult most often for limping or decreased weight bearing. But these symptoms are very common reasons for consultation in young children and main etiologies are hematogenous osteoarticular infections localized to the knee or the hip and trauma. These difficulties may delay the diagnosis or refer misdiagnosis.<sup>2,5,6,9,14</sup> Cases of patients who have been wrongly operated on for an appendicitis whereas they had a sacroiliitis have been reported.<sup>21,22</sup>

Bone scintigraphy is useful in young children to locate a bone or joint disease responsible for limping. In this observation, the combination of decreased weight bearing and inflammatory syndrome suspected an osteoarticular infection. It is the bone scintigraphy that located the infection at the right sacroiliac joint. The review of the literature confirms the high sensitivity of bone scintigraphy for the diagnosis of pyogenic sacroiliitis since it made the diagnosis in all but 2 of the 50 patients who had a bone scintigraphy.<sup>2–4,7,14,17,19,20</sup> But given the unusually young age of our patient, we performed an MRI to confirm the diagnosis, to see the extent of inflammation, to search an etiology and to eliminate a complication such as an abscess. The review of the literature confirms that MRI has a good sensitivity for the diagnostic of pyogenic sacroiliitis since it was positive in all but 1 of the 16 patients who had an MRI.

The *Staphylococcus aureus* isolated in the joint aspiration is the main pathogen in our review of the literature since it represented 30 of the 41 pathogens identified. Prevalence of resistance to methicillin was not clearly detailed but it seemed that *Staphylococcus aureus* susceptible to methicillin was very more frequent.<sup>15</sup> Other cases of sacroiliitis due to *Staphylococcus epidermidis*, *Streptococcus* (Groups A and pneumoniae), *Citrobacter freundii*, *Salmonella* spp., *Bacillus subtilis*, and *Escherichia coli* have been reported in children.<sup>1,3,4,7,14,17,20,23,18</sup>

Despite the very young age of the patient and the delayed start of treatment, symptoms rapidly disappeared with appropriate antibiotic therapy.

### CONCLUSIONS

This observation reports a very rare case of pyogenic sacroiliitis in a 13-month-old child. It reminds the risk of misdiagnosing pyogenic sacroiliitis in very young children because it is exceptional. It also highlights the difficulty to diagnose it in children and the usefulness of bone scintigraphy and MRI in osteoarticular infections in children.

### REFERENCES

- Schaad UB, McCracken GH, Nelson JD. Pyogenic arthritis of the sacroiliac joint in pediatric patients. *Pediatrics*. 1980;66:375–379.
- Ford LS, Ellis AM, Allen HW, et al. Osteomyelitis and pyogenic sacroiliitis: a difficult diagnosis. *J Paediatr Child Health*. 2004;40:317–319.
- Lenfant J, Journeau P, Touzet P, et al. Sacro-iliites à pyogène de l'enfant. A propos de 11 cas. *Rev Chir Orthopédique Réparatrice Appar Mot*. 1997;83:139–147.
- Tokuda K, Yoshinaga M, Nishi J, et al. Three cases of pyogenic sacro-iliitis, and factors in the relapse of the disease. *Acta Paediatr Jpn Overseas Ed*. 1997;39:385–389.
- Chiu CH, Lin TY, Hung PC, et al. Pyogenic sacroiliitis in children: report of three cases. *Zhonghua Minguo Xiao Er Ke Yi Xue Hui Za Zhi J Zhonghua Minguo Xiao Er Ke Yi Xue Hui*. 1992;33:313–321.
- Abbott GT, Carty H. Pyogenic sacroiliitis, the missed diagnosis? *Br J Radiol*. 1993;66:120–122.
- Aprin H, Turen C. Pyogenic sacroiliitis in children. *Clin Orthop*. 1993;98–106.
- Doita M, Yoshiya S, Nabeshima Y, et al. Acute pyogenic sacroiliitis without predisposing conditions. *Spine*. 2003;28:E384–E389.
- Shanahan MD, Ackroyd CE. Pyogenic infection of the sacro-iliac joint. A report of 11 cases. *J Bone Joint Surg Br*. 1985;67:605–608.
- McPhee E, Eskander JP, Eskander MS, et al. Imaging in pelvic osteomyelitis: support for early magnetic resonance imaging. *J Pediatr Orthop*. 2007;27:903–909.
- Bigot J, Loeuille D, Chary-Valckenaere I, et al. Détermination des meilleurs critères diagnostiques des sacro-iliites en IRM. *J Radiol*. 1999;80:1649–1657.
- Haliloglu M, Kleiman MB, Siddiqui AR, et al. Osteomyelitis and pyogenic infection of the sacroiliac joint. MRI findings and review. *Pediatr Radiol*. 1994;24:333–335.
- Miller JH, Gates GF. Scintigraphy of sacroiliac pyarthrosis in children. *JAMA*. 1977;238:2701–2704.
- Sueoka BL, Johnson JF, Enzenauer R, et al. Infantile infectious sacroiliitis. *Pediatr Radiol*. 1985;15:403–405.
- Taylor ZW, Ryan DD, Ross LA. Increased incidence of sacroiliac joint infection at a children's hospital. *J Pediatr Orthop*. 2010;30:893–898.
- Wada A, Takamura K, Fujii T, et al. Septic sacroiliitis in children. *J Pediatr Orthop*. 2008;28:488–492.
- Wu M-S, Chang S-S, Lee S-H, et al. Pyogenic sacroiliitis: a comparison between paediatric and adult patients. *Rheumatol Oxf Engl*. 2007;46:1684–1687.
- Perez A, Padilla E, Marco A, et al. Pneumococcal sacroiliitis in a 4-year-old boy. *Scand J Rheumatol*. 2008;37:310–312.
- Letts M, Lalonde F, Davidson D, et al. Atrial and venous thrombosis secondary to septic arthritis of the sacroiliac joint in a child with hereditary protein C deficiency. *J Pediatr Orthop*. 1999;19:156–160.
- Vic P, Blondin G, Toullec E, et al. [Neuropathic pain associated with septic sacroiliitis]. *Arch Pédiatrie Organe Off Société Fr Pédiatrie*. 1998;5:577–578.
- Cohn SM, Schoetz DJ. Pyogenic sacroiliitis: another imitator of the acute abdomen. *Surgery*. 1986;100:95–98.
- Coy JT, Wolf CR, Brower TD, et al. Pyogenic arthritis of the sacroiliac joint. Long-term follow-up. *J Bone Joint Surg Am*. 1976;58:845–849.
- Komatsu H, Nojiri H, Sogo T, et al. Sacroiliitis infected with group A streptococcus in a child presenting with confusion and combativeness. *J Infect Chemother Off J Jpn Soc Chemother*. 2009;15:328–330.