



Congenital disorders of glycosylation (CDG): Quo vadis ?

Romain Péanne, Pascale de Lonlay, Francois Foulquier, Uwe Kornak, Dirk J. Lefeber, Eva Morava, Belén Pérez, Nathalie Seta, Christian Thiel, Emile van Schaftingen, et al.

► To cite this version:

Romain Péanne, Pascale de Lonlay, Francois Foulquier, Uwe Kornak, Dirk J. Lefeber, et al.. Congenital disorders of glycosylation (CDG): Quo vadis ?. European Journal of Medical Genetics, 2018, 61 (11), pp.643-663. 10.1016/j.ejmg.2017.10.012 . hal-03181211

HAL Id: hal-03181211

<https://hal.univ-lille.fr/hal-03181211>


Submitted on 25 Mar 2021

HAL is a multi-disciplinary open access archive for the deposit and dissemination of scientific research documents, whether they are published or not. The documents may come from teaching and research institutions in France or abroad, or from public or private research centers.

L'archive ouverte pluridisciplinaire **HAL**, est destinée au dépôt et à la diffusion de documents scientifiques de niveau recherche, publiés ou non, émanant des établissements d'enseignement et de recherche français ou étrangers, des laboratoires publics ou privés.



Distributed under a Creative Commons Attribution 4.0 International License



Congenital disorders of glycosylation (CDG): Quo vadis?

Romain Péanne^{a,k}, Pascale de Lonlay^b, François Foulquier^{c,1}, Uwe Kornak^d, Dirk J. Lefeber^e, Eva Morava^f, Belén Pérez^g, Nathalie Seta^h, Christian Thielⁱ, Emile Van Schaftingen^j, Gert Matthijs^{a,k,*}, Jaak Jaeken^f

^a Center for Human Genetics, KU Leuven, Leuven, Belgium

^b APHP, Hôpital Necker Enfants Malades, Service et Centre de Référence des Maladies Métaboliques, Université Paris Descartes, Institut Imagine, Paris, France

^c Université de Lille, Unité de Glycobiologie Structurale et Fonctionnelle, Villeneuve D'Ascq, France

^d Institut für Medizinische Genetik und Humangenetik, and Berlin-Brandenburg Centre for Regenerative Therapies, Charité University, Berlin, Germany

^e Department of Neurology, Translational Metabolic Laboratory, Radboud University Medical Center, Nijmegen, The Netherlands

^f Center for Metabolic Diseases, KU Leuven, Leuven, Belgium

^g Centro de Diagnostico de Enfermedades Moleculares, Centro de Biología Molecular-SO UAM-CSIC, Centro de Investigación Biomédica en Red de Enfermedades Raras (CIBERER), IdiPaz, Universidad Autónoma de Madrid, Madrid, Spain

^h AP-HP, Hôpital Bichat, Biochemistry Laboratory, Paris, France

ⁱ Stoffwechselzentrum, Universitäts-Kinderklinik, Heidelberg, Germany

^j Laboratory of Biochemistry, de Duve Institute, University of Louvain, Brussels, Belgium

^k LIA GLYCOLAB4CDG France/Belgium (International Associated Laboratory “Laboratory for the Research on Congenital Disorders of Glycosylation – from cellular mechanisms to cure”, France)

¹ LIA GLYCOLAB4CDG France/Belgium (International Associated Laboratory “Laboratory for the Research on Congenital Disorders of Glycosylation – from cellular mechanisms to cure”, Belgium)

A B S T R A C T

The survey summarizes in its first part the current status of knowledge on the Congenital Disorders of Glycosylation (CDG) with regard to their phenotypic spectrum, diagnostic and therapeutic strategies, and pathophysiology. It documents the clinical and basic research activities, and efforts to involve patients and their families. In the second part, it tries to look into the future of CDG. More specific biomarkers are needed for fast CDG diagnosis and treatment monitoring. Whole genome sequencing will play an increasingly important role in the molecular diagnosis of unsolved CDG. Epigenetic defects are expected to join the rapidly expanding genetic and allelic heterogeneity of the CDG family. Novel treatments are urgently needed particularly for PMM2-CDG, the most prevalent CDG. Patient services such as apps should be developed e.g. to document the natural history and monitor treatment. Networking (EURO-CDG, the European Reference Networks (MetabERN)) is an efficient tool to disseminate knowledge and boost collaboration at all levels. The final goal is of course to improve the quality of life of the patients and their families.

1. Introduction

Approximately half of all proteins typically expressed in a cell undergo glycosylation to achieve their full functionality. There are mainly two categories of glycosylation: N-glycosylation and O-glycosylation. N-glycans are linked to the amide group of asparagine, while O-glycans are linked to the hydroxyl group of serine or threonine. The synthesis of N-glycans proceeds in three stages: formation of nucleotide-linked sugars, assembly (in cytosol and ER), and processing (in the Golgi). The synthesis of O-glycans does not involve processing, and occurs mainly in the Golgi. Besides, there is also lipid glycosylation and synthesis of glycosylphosphatidylinositol anchors. Congenital Disorders of Glycosylation (CDG) are genetic defects in the synthesis and attachment

of glycoprotein and glycolipid glycans. Initially, mutations were found in genes encoding glycosyltransferases, remodelling glycosidases, and sugar nucleotide transporters, that are all known to have a direct role in glycosylation. However, new forms of CDG have recently been identified with defects in vesicular trafficking, pH homeostasis or Mn^{2+} homeostasis. Various approaches have been developed for the efficient diagnosis of these diverse types of CDG (see section 2.2 for more details). Since their first clinical description in 1980, 105 types of CDG have been identified, and that number keeps rising. Their clinical spectrum is extremely broad, covers nearly all known phenotypes, and comprises new phenotypes. Research into CDG received an enormous boost since 1999 thanks to the consecutive, collaborative initiatives of EUROGLYCAN and EUROGLYCANET, that were originally funded by

* Corresponding author. Center for Human Genetics, KU Leuven, Leuven, Belgium.

E-mail address: gert.matthijs@kuleuven.be (G. Matthijs).

<http://dx.doi.org/10.1016/j.ejmg.2017.10.012>

Received 27 July 2017; Received in revised form 5 October 2017; Accepted 22 October 2017

Available online 25 October 2017

1769-7212/ © 2017 The Authors. Published by Elsevier Masson SAS. This is an open access article under the CC BY license (<http://creativecommons.org/licenses/by/4.0/>).

the European Commission's Framework Programmes. In 2011, our group (Berlin, Brussels, Heidelberg, Leuven, Lille (Villeneuve d'Ascq), Madrid, Nijmegen, and Paris) has successfully replied to the E-Rare-2 Call for Proposals with the EURO-CDG project. Research in the context of EURO-CDG has yielded improved diagnostic methodologies resulting in the identification of an increasing number of CDG, shortening of the time to diagnosis, and CDG diagnosis in patients who remained 'unsolved' for many years. In addition, cellular models have been used to study the pathophysiology of disease and to identify molecular pathways that can be targeted for therapy. Within the network, more than 1300 CDG patients received a definite diagnosis (with PMM2-CDG representing 62% of the recorded patients, and 30 other CDG representing the remaining 38%).

Efforts are now guided towards the development of therapeutic approaches for PMM2-CDG, the most frequent CDG, but also for the more rare CDG. The functional characterization of disease-causing mutations in PMM2-CDG patients led to the identification of pharmacological chaperones to rescue the folding of the mutant PMM2 enzyme. In parallel, oral D-galactose therapy has been shown to be beneficial in CDG with hypogalactosylation. We initiated a multicentre clinical trial to characterize the effects of D-galactose supplementation in different genetic conditions affecting Golgi glycosylation, including PGM1-CDG, TMEM165-CDG and SLC35A2-CDG. The European network for research on CDG wants to build on its past achievements and is committed to explore different possibilities to improve treatment and quality of life of the patients and their families. It will of course also share efforts to this aim with other researchers interested in CDG. Open, international meetings, often in parallel with patients and parents meetings, are meant to exchange experience and results, and to promote progress in CDG.

2. CDG at present

2.1. Phenotypic spectrum

Table 1 tabulates the known CDG (in alphabetical order) with the main associated organ involvement and symptomatology. For a recent general review on CDG and a selection of reviews on organ/tissue-specific CDG and specific CDG/CDG groups see Jaeken and Morava 2016; Jaeken and Péanne 2017. The fact that five novel CDG have been reported in the first half of 2017 illustrates the rapid expansion of this disease family: ATP6V1A-CDG (Van Damme et al., 2017), ATP6V1E1-CDG (Van Damme et al., 2017), PIGC-CDG (Edvardson et al., 2017), TRAPPC11-CDG (Matalonga et al., 2017), and OGT-CDG (Willems et al., 2017). Also, a novel regulatory mutation has been presented, with a defect in the PMM2 promoter (Cabezas et al., 2017). In recent years, it has become clear that some CDG can present totally different phenotypes depending on the types of mutation. Striking examples are PMM2-CDG (a dysmorphism-disability syndrome; polycystic kidney disease with hyperinsulinemic hypoglycaemia; isolated tendency to thrombosis), ALG9-CDG (a dysmorphism/neuro-hepato-renal syndrome; a skeletal phenotype with death in utero), EXT2-CDG (exostoses; seizures-scoliosis-macrocephaly syndrome), PIGA-CDG (intellectual disability and seizures without dysmorphism; ferro-cerebrocutaneous syndrome; Simpson-Golabi-Behmel syndrome type 2; early onset epileptic encephalopathy with severe muscular hypotonia, dysmorphism, multiple congenital anomalies and early death (MCAHS2)), and POGUT1-CDG (skin disease; muscular dystrophy). No defects have yet been reported in many genes of the glycosylation machinery, as for instance in the Golgi mannosidases (except MAN1B1), in MGAT1, B4GAT1, ...which have been candidate genes, right from the beginning. We reckon that patients with defects in these genes are extremely rare and highly underestimated, or may not survive until birth.

There is an increasing number of reports on adult features of CDG such as PMM2-CDG (up to 67 years; Monin et al., 2014; Barone et al., 2015), SRD5A3-CDG (up to 45 years; Kahrizi et al., 2011; Kara et al.,

2014; Wheeler et al., 2016), PGM3-CDG (up to 35 years; Sassi et al., 2014; Zhang et al., 2014), a.o. This helps in answering the often asked question of parents: what is the future of my child?

2.2. CDG frequency and registry

The standard test for the diagnosis of N-glycosylation disorders with sialic acid deficiency is still isoelectrofocusing of serum transferrin (Tf IEF), which is only N-glycosylated. A type 1 pattern (decreased tetra-sialotransferrin, increased disialo- and asialotransferrin) points to an assembly defect or a defect in the transfer to the peptide chain (CDG-I), whilst a type 2 pattern (increase also of threesialo- and monosialotransferrin) suggests a remodelling defect (CDG-II). Note that in normal infants up to about 6 weeks, the serum transferrin bands are slightly more intense than later on (looking like a mild type 2 pattern). In case of a typical MPI-CDG or PMM2-CDG presentation, enzymatic testing can be performed in leukocytes or fibroblasts although it is more cumbersome than direct mutation analysis of the *MPI* and *PMM2* genes respectively. In addition, we have evidence that false negative PMM2 measurements in fibroblasts occur (G. Matthijs, E. Van Schaftingen and co-workers, unpublished). Hence, we propose to sequence the *PMM2* gene first in all CDG type I cases. In the other cases with a type 1 pattern, there is a tendency to first perform a targeted CDG panel analysis, and when negative, whole genome/exome sequencing. Lipid-linked oligosaccharide analysis (LLO) in fibroblasts for type 1 is a cumbersome and expensive test that not always provides accurate results (see below). In patients with a type 2 pattern, mass spectrometry of transferrin glycans can first be performed but this rarely yields a specific pattern. Isoelectrofocusing of serum apolipoprotein C-III (which is only O-glycosylated) can detect some O-glycosylation disorders. A flowchart summarizing the approach to obtain molecular diagnosis in unsolved CDG is depicted in Fig. 1.

Since there is no worldwide CDG registry, information about frequency is lacking. In order to fill up this gap, in November 2016 the different laboratories in Europe offering CDG diagnosis were asked to fill an informal excel table with (i) the actual number of patients for each type of molecularly diagnosed CDG-I and CDG-II; (ii) and for the types with less than 4 patients, the initials and nationality of the patients, to avoid double counting of patients with a very rare CDG that could have been studied by more than one laboratory; and (iii) the number of 'unsolved' patients (indicating: positive screening for abnormal glycans, negative targeted sequencing or negative exome results). Thus only the CDG with an abnormal transferrin IEF were included in this study (for example not alpha-dystroglycanopathies).

The following laboratories accepted to share their data: Barcelona, Catania, Heidelberg, Leuven, Lille, Lyon, Madrid, Nijmegen, Paris, Porto, Prague and Tallinn. The number of molecularly diagnosed patients was 1350, distributed among 94% CDG-I and 6% CDG-II. Twenty-two different types of CDG-I and 15 of CDG-II were reported. Fig. 2 shows the distribution of the patients. As to CDG-I (Fig. 2A), PMM2-CDG, as expected, was by far the most frequent (62%; n: 834). ALG6-CDG was the second most frequent (8%; n: 101), followed by SRD5A3-CDG (n: 43), ALG1-CDG (n: 41) and MPI-CDG (n: 36). Regarding CDG-II (Fig. 2B), MANB1-CDG was the type with the largest number of patients (n: 18), followed by COG7-CDG (n: 10). The different COG deficiencies (COG1-CDG COG4-CDG to COG8-CDG) together comprised 33 patients. The distribution of some specific types was strikingly different within the different laboratories. For example, almost all of the TMEM165-CDG patients (n: 5/6) were reported by Leuven, the SRD5A3-CDG patients mainly by Nijmegen. Importantly, it is worth mentioning that some patients may have been counted twice, as samples traveled extensively especially in the early days of genetic diagnostics.

Finally, the number of reported molecularly unsolved cases was relatively small (less than 100). The total number of diagnosed CDG patients in Europe might reasonably exceed 2500 when adding those from the United Kingdom, Ireland, and the countries of Northern and

Table 1

Overview of CDG organ involvement and symptoms/signs. Items before the semicolon are clinical symptoms and signs, and the items after the semicolon are results of paraclinical investigations.

ALG1-CDG *

Brain	psychomotor disability, microcephaly, refractory epilepsy, hypotonia; cerebral atrophy
Liver	hepatosplenomegaly
Dysmorphic features	large fontanel, hypertelorism, micrognathia
Other	nonimmune foetal hydrops, hypogonadism

ALG2-CDG *

Brain	psychomotor disability, epilepsy; hypomyelination
Eyes	bilateral iris coloboma, cataract
Liver	hepatomegaly

Myasthenic syndrome, congenital, 14, with tubular aggregates

Muscles	slowly progressive motor disability, waddling gait, hypotonia, absent reflexes, muscle weakness (proximal more than distal) including mild facial weakness, myasthenia
Skeleton	lumbar lordosis, scapular winging

ALG3-CDG *

Brain	developmental disability, microcephaly, epilepsy, axial hypotonia, hyperreflexia; cerebellar and corpus callosum hypoplasia
Eyes	strabismus, epicanthus, optic atrophy, iris coloboma, cortical blindness
Skeleton	arthrogryposis, clubfeet
Dysmorphic features	facial dysmorphism (dysplastic ears, broad flat nasal bridge, abnormalities of the uvula and high-arched palate), pectus excavatum and hypoplastic nipples
Other	failure to thrive with vomiting, diarrhoea

ALG6-CDG *

Brain	psychomotor disability, epilepsy, cortical blindness, dysarthria, wide-based gait, ataxia, intention tremor; agenesis of the corpus callosum
Eyes	hyperopia; atrophic retinal pigmentation, reduction of retinal vascularization
Skeleton	distal limb defects
Other	endocrine (hyperandrogenism, hyperinsulinemic, hypoglycaemia) and gastrointestinal disturbances

ALG8-CDG *

Heart	ventricular septal defects, patent ductus arteriosus
Liver	hepatomegaly, multiple cystic intra- and extrahepatic bile ducts, cholestasis
Kidneys	diffuse renal microcysts
Skeleton	camptodactyly, clubfeet
Dysmorphic features	craniofacial dysmorphism (asymmetric skull, large fontanel, hypertelorism, low-set and abnormally positioned ears, long philtrum), short neck
Other	diarrhoea (protein-losing enteropathy), vomiting, massive ascites; hypoalbuminemia

ALG9-CDG *

Brain	psychomotor disability, microcephaly, epilepsy, hypotonia; diffuse brain atrophy with delayed myelination
Heart	pericardial effusion
Liver/spleen	hepatosplenomegaly
Kidneys	cystic renal disease
Other	failure to thrive, esotropia, inverted nipples

Gillessen-Kaesbach-Nishimura syndrome

Brain	microcephaly; ectopic gray matter, focal laminar necrosis and migration abnormalities in the cerebellum
Heart	ventricular septal defect, double outlet right ventricle with anomalous outflow tract
Liver	periportal hepatic fibrosis, cystic dilation of the bile ducts, mild ductal dilation of the pancreas
Kidneys	polycystic kidneys (Potter type I)
Skeleton	brachymelia, lethal mesomelic osteochondrodysplasia, decreased ossification of the frontoparietal bones, thickening of the occipital bones, 'butterfly' vertebrae, distinctive shape of the iliac bones, bowed and thickened radii and ulnae, lack or partial ossification of the cervical vertebral bodies, round ilia, delayed ossification of the pubic bones, and thick, round pelvis, and short tubular bones with metaphyseal flaring
Dysmorphic features	facial dysmorphism (microbrachycephaly, abundant hair, hypertelorism with telecanthus, low-set, posteriorly rotated and fleshy ears, sloping forehead, aniridia, anteverted nares, beaked nose, long palpebral fissures, flat philtrum with upturned upper lip, micrognathia, cleft palate), short neck, short extremities with ulnar deviation of the hands and deformed feet
Other	diaphragmatic hernia, abnormal lung lobulation

(continued on next page)

Table 1 (continued)

ALG11-CDG *

Brain	developmental disability, epilepsy, hypotonia; abnormal brainstem auditory response consistent with deafness
Eyes	strabismus, delayed pupil reaction and fixation, no blink reflex, lack of visual tracking
Muscles	opisthotonus
Dysmorphic features	craniofacial dysmorphism (small head, high forehead with low hairline, long philtrum, retrognathia), scoliosis, fat pads, inverted nipples
Other	poor feeding, recurrent vomiting, instability of body temperature

ALG12-CDG *

Brain	disabled motor and mental development, microcephaly, hypotonia; widening of the lateral ventricles without hydrocephalus
Eyes	blindness
Heart	cardiomyopathy and other cardiac abnormalities
Skeleton	unique short limb skeletal dysplasia with delayed ossification of cervical vertebrae and signs of generalized epiphyseal dysplasia including lack of ossification of the pubic bones, knee epiphyses, and tali
Dysmorphic features	facial dysmorphism, supragluteal fat pads
Other	male genital hypoplasia, immunodeficiency, IgG deficiency, recurrent ear, nose, throat, and respiratory infections, failure to thrive, generalized oedema, deafness

ALG13-CDG *

Epileptic encephalopathy, early infantile, 36

Brain	psychomotor disability, epilepsy; hydrocephalus, myelination deficiency, wide sulci, hypsarrhythmia on EEG
Dysmorphic features	facial dysmorphism (coarse face, hypertelorism, low-set ears, mild retromicrognathia), small hands and feet, joint contractures, and scoliosis
Other	neonatal feeding problems, self-mutilation, sleep disturbance

ALG14-CDG *

Myasthenic syndrome, congenital, 15, without tubular aggregates:

Muscles	congenital myasthenia, multiple joint contractures in adulthood
---------	---

ATP6AP1-CDG **

Immunodeficiency 47

Liver	neonatal jaundice, hepatosplenomegaly; histology: steatosis, fibrosis, micronodular cirrhosis, abnormal mitochondria
Other	recurrent bacterial infections associated with hypogammaglobulinemia

ATP6V0A2-CDG **

Cutis laxa, autosomal recessive, type IIA

Brain	developmental and mental disability, microcephaly, seizures, hypotonia; bilateral pachygyria, cobblestone-like malformation predominantly in the posterior frontal, perisylvian, and parietal regions
Eyes	high myopia
Skeleton	persistent fontanels, slight oxycephaly, pigeon breast, hip dislocation, static scoliosis, flat feet, joint hyperlaxity
Dysmorphic features	bossing of the forehead, reversed-V eyebrows, downslanting of palpebral fissures, large anterior fontanel, prominent supraorbital ridges, midface hypoplasia, anteverted nares, short nose, small mouth
Skin	overfolding and wrinkling of the skin (unaffected face), but no hyperelasticity

Wrinkly skin syndrome

Brain	mental disability, microcephaly, epilepsy
Heart	atrial septum aneurysm
Skeleton	poorly developed and hypotonic skeletal musculature, with winging of the scapulae
Dysmorphic features	craniofacial dysmorphism
Skin	wrinkled skin of hands, feet and abdominal wall, decreased elastic recoil of the skin; elastic fibre abnormalities

B3GALNT2-CDG

Muscular dystrophy-dystroglycanopathy (congenital with brain and eye anomalies), type A, 11

Brain	polymicrogyria, hydrocephalus, cerebellar cysts, pontocerebellar hypoplasia, frontotemporal leukoencephalopathy, and cobblestone lissencephaly
Eyes	myopia, microphthalmia; optic nerve hypoplasia
Muscles	dystrophy

B3GALT6-CDG

Ehlers-Danlos syndrome, progeroid type, 2

Brain	developmental disability
Muscles	hypotonia
Skeleton	general osteopenia, hypermobile joints
Dysmorphic features	aged appearance, short stature, craniofacial disproportion
Skin	defective wound healing, loose, elastic skin

(continued on next page)

Table 1 (continued)

<u>Spondyloepimetaphyseal dysplasia with joint laxity, type 1, with or without fractures</u>	
Muscles	hypotonia
Heart	congenital heart disease
Skeleton	brachydactyly of hands and feet, progressive severe kyphoscoliosis, thoracic asymmetry, elbow deformities with radial head dislocation, dislocated hips, clubfeet, tapered fingers with spatulate distal phalanges, platyspondyly, spondyloepimetaphyseal dysplasia with bone fragility, multiple early-onset fractures, minimal metaphyseal and epiphyseal abnormalities at the knees
Dysmorphic features	oval face, flat midface, prominent eyes with blue sclerae, long philtrum, palatal abnormalities
B3GAT3-CDG	
<u>Multiple joint dislocations, short stature, craniofacial dysmorphism, with or without congenital heart defects</u>	
Eyes	wide-set eyes, proptosis, blue sclerae
Heart	dilated cardiomyopathy
Skeleton	shortened metacarpals and spatulate deformity of the tuft of the thumb (so-called 'delta phalanx'), multiple ossification centers leading to supernumerary carpal bones, pseudoclubbing of fingers, deep palmar creases, kyphoscoliosis, severe hyperextensibility of all joints except for the elbows, dislocations of shoulders, elbows, proximal radioulnar joints, mild shortening of the first metacarpal bone, delayed and dissociated bone age, mild dysplasia of the hip joints, and foot deformities; osteopenia. foot deformity with brachymetatarsia and brachymetapody
Dysmorphic features	prominent forehead, brachycephaly, thick eyebrows, large eyes with downslanting palpebral fissures, depressed nasal bridge, micrognathia or microretrognathia
B4GALNT1-CDG	
<u>Spastic paraplegia 26, autosomal recessive</u>	
Brain	intellectual disability; cortical atrophy and white matter hyperintensities
Eyes	cataract
Muscles	spastic paraplegia, gait abnormalities due to lower limb spasticity, hyperreflexia, extensor plantar responses, muscle weakness and atrophy; axonal sensorimotor neuropathy
Skeleton	mild upper limb involvement, including decreased vibration sense at the ankles, pseudobulbar dysarthria, pes cavus, scoliosis
B4GALT7-CDG	
<u>Ehlers-Danlos syndrome with short stature and limb anomalies</u>	
Brain	mental disability, mild hypotonia
Skeleton	short stature, bowing of extremities, multiple dislocations, defective deciduous teeth, mild pectus carinatum, bilateral elbow contractures with decreased supination, hyperextension of the shoulders, wrists, fingers, and knees, varus bowing of the lower legs, marked pes planus, and long toes; osteopenia, dysplasia of some bones, early bone maturation with multiple ossification centres, metaphyseal enlargement
Dysmorphic features	facial dysmorphism (relatively small face with prominent forehead, flattened nasal bridge, large and protuberant eyes, small ears, deep nasolabial folds, small mouth, curly and fine hair, scanty eyebrows and eyelashes, telecanthus), short neck, pectus excavatum
Other	joint laxity, skin hyperextensibility, loose, elastic skin, delayed wound healing with thin, atrophic scars, multiple nevi, periodontitis, papyraceous scars, bruiseability, varicose veins, bilateral cryptorchidism
B3GALT-CDG	
<u>Peters-plus syndrome</u>	
Brain	developmental/intellectual disability, macrocephaly, microcephaly; hydrocephaly, cerebral atrophy
Eyes	Peters' anomaly (central corneal clouding, thinning of posterior cornea, iridocorneal adhesions), cataracts, congenital glaucoma
Skeleton	growth deficiency (starts prenatally; growth hormone deficiency in some patients)
Dysmorphic features	prominent forehead, hypoplastic columella, long philtrum, depressed nasal bridge, anteverted nostrils, thin vermilion border of the upper lip, cleft lip/palate, ear anomalies, broad neck, urogenital malformations
CAD-CDG	
<u>Epileptic encephalopathy, early infantile, 50</u>	
Brain	disabled psychomotor development, early-onset epilepsy
Other	normocytic anaemia characterized by anisopoikilocytes, acanthocytes, and schistocytes
CCDC115-CDG **	
Brain	psychomotor disability, hypotonia
Liver	neonatal jaundice, liver failure, hepatosplenomegaly; increased serum transaminases; histology: variable fibrosis, necrosis, cirrhosis
Dysmorphic features	mild dysmorphic features, such as long face and ptosis.
CHSY1-CDG	
<u>Temtamy preaxial brachydactyly syndrome</u>	
Eyes	macrophthalmia, blue sclerae, remnants of pupillary membrane; tilted optic discs
Skeleton	preaxial brachydactyly, phalangeal duplication, symphalangism and hyperphalangism of digits 1-3, ulnar deviation of the fifth fingers; accessory ossicles of digits 2-5
Dysmorphic features	micrognathia, talon cusps of upper central incisors, cleft palate
Other	growth deficiency, sensorineural deafness

COG1-CDG **

(continued on next page)

Table 1 (continued)

Brain	psychomotor disability, microcephaly, hypotonia; large cisterna magna, hypoplastic vermis, atrophy of the temporal cortex
Eye	maculopathy
Heart	hypertrophy of the atrial septum, pulmonary hypertension
Liver	enlarged liver and spleen
Skeleton	costovertebral anomalies (osteopenia, rib fusions and posterior rib gaps, butterfly vertebrae, misaligned vertebrae, kyphoscoliosis), shortening of the long bones, coxa valga, shallow acetabular roofs, and small proximal epiphyses of the femur with irregular medial parts, clubfeet
Dysmorphic features	rhizomelic short stature, facial dysmorphism (downslanting palpebral fissures, wide nasal bridge, hypertelorism, long philtrum, thin upper lip, broad, low-set posteriorly rotated ears, Pierre-Robin sequence), short neck

COG2-CDG **

Brain	developmental disability, acquired microcephaly, spastic quadriplegia; diffuse cerebral atrophy, thin corpus callosum, small pituitary gland
Liver	dysfunction

COG4-CDG **

Brain	psychomotor disability, microcephaly, axial hypotonia, mild peripheral hypertonia, ataxia, hyperreflexia; diffuse cerebral atrophy, thinning of corpus callosum
Eyes	nystagmus
Liver	hepatosplenomegaly, liver cirrhosis
Dysmorphic features	down-sloping frontal area, thick hair
Other	recurrent respiratory infections, failure to thrive in infancy with recurrent diarrhoea

COG5-CDG **

Brain	moderate mental disability, truncal ataxia, mild hypotonia; pronounced atrophy of the cerebellum and brainstem
-------	--

COG6-CDG **

Brain	developmental disability, microcephaly, epilepsy
Liver	hepatomegaly; increased serum transaminases; histology: macrovesicular steatosis, cirrhosis
Kidneys	proximal tubulopathy
Dysmorphic features	broad palpebral fissures, retrognathia, anal anteversion
Other	vomiting, diarrhea, failure to thrive, inflammatory bowel disease, recurrent infections; primary combined immunodeficiency with hypogammaglobulinemia and defective cellular immunity without lymphopenia

COG7-CDG **

Brain	developmental disability, microcephaly, epilepsy, hypotonia; cerebral atrophy
Eyes	poor ocular fixation
Heart	cardiac insufficiency
Liver	hepatomegaly, jaundice; cholestasis
Skeleton	distal arthrogryposis, adducted thumbs
Dysmorphic features	craniofacial dysmorphism (low-set dysplastic ears, micrognathia, flat face, full lips, protruding tongue), short neck, wrinkled skin, inverted nipples
Other	failure to thrive, diarrhoea; anaemia, thrombocytopenia, proteinuria

COG8-CDG **

Brain	psychomotor disability, epilepsy, ataxia, hypotonia; cerebellar atrophy, slight brainstem atrophy, axonal neuropathy
Eyes	alternating esotropia, pseudoptosis
Other	spontaneous hematomas

DDOST-CDG *

Brain	developmental disability, hypotonia; disordered myelination
Eyes	external strabismus
Liver	dysfunction
Skeleton	advanced bone age, osteopenia
Other	failure to thrive, gastroesophageal reflux, constipation, ear infections, and oromotor dysfunction

DHDDS-CDG *

Retinitis pigmentosa 59

Eyes	decreased visual acuity, impaired night vision; diffuse pigmentary retinal degeneration with vascular attenuation, cone-rod dysfunction, bone spicule-like pigmentation, absent electroretinographic response
------	---

Multisystem disease

Brain	epilepsy
Eyes	fundus oculi: pale papillae; electroretinogram: no response to any type of stimulation
Liver	enlarged liver; mild dilatation of the biliary duct; transient increase of serum transaminases
Kidneys	renal failure

(continued on next page)

Table 1 (continued)

Muscles	axial hypotonia, peripheral hypertonia
Heart	severe brachycardia
Dysmorphic features	micropenis, cryptorchidism
Other	intra-uterine growth retardation and decreased fetal movements during pregnancy, poor sucking with frequent regurgitations, failure to thrive, sensorineural deafness

DOLK-CDG *

Brain	disabled psychomotor development with lack of speech, epilepsy; hypsarrhythmia (EEG)
Eyes	progressive bilateral nystagmus
Muscles	hypotonia, tetraplegia
Heart	dilated cardiomyopathy (sometimes isolated)
Other	ichthyosis, sparse eyebrows and eyelashes, minimal hair growth

DPAGT1-CDG *

Brain	progressive microcephaly, intractable epilepsy, hypotonia; cerebral atrophy
Eyes	strabismus, nystagmus, bilateral cataracts
Liver	jaundice
Dysmorphic features	micrognathia, arched palate, fifth finger clinodactyly, single flexion creases of the hands, skin dimples on the upper thighs
Other	frequent apnoeas, respiratory insufficiency, joint contractures, tremor, feeding difficulties, cryptorchidism

Myasthenic syndrome, congenital, 13, with tubular aggregates

Muscles	limb-girdle congenital myasthenic syndrome; structural and functional abnormalities of the neuromuscular junction, tubular aggregates on muscle biopsy, predominantly in proximal limb muscles
Skeleton	scoliosis

DPM1-CDG *

Brain	developmental disability, microcephaly, epilepsy, hypotonia, cerebellar ataxia with dysmetria, tremor, ataxic gait; cerebral atrophy, T2-weighted hyperintensities of the dentate nucleus
Eyes	strabismus, nystagmus, cortical blindness; optic nerve atrophy, macular retinopathy
Muscles	dystrophy, with increased variation in fibre size, areas of necrosis, hypoglycosylation of alpha-dystroglycan

Dysmorphic features	craniofacial dysmorphism (trigonocephaly, prominent forehead, thick metopic suture, hypertelorism, high nasal bridge, smooth philtrum, micrognathia, gothic palate, teeth malocclusion), hemangiomas, camptodactyly, small hands with dysplastic nails
Other	hydrops, respiratory distress, apnoeas, patent ductus arteriosus

DPM2-CDG *

Brain	disabled psychomotor development without visual tracking, head control and speech, microcephaly, epilepsy; cerebellar hypoplasia
Eyes	strabismus
Muscles	dystrophy on muscle biopsy
Skeleton	severe congenital contractures of the joints, scoliosis
Dysmorphic features	myopathic facies, micrognathia, teeth malocclusion
Other	respiratory infections

DPM3-CDG *

Muscles	waddling gate; moderate muscular dystrophy with variation in fibre size, multiple internal nuclei, necrotic fibres, rimmed vacuoles, fibre splitting, interstitial fibrosis
Heart	dilated cardiomyopathy

EOGT-CDG

Adams-Oliver syndrome 4

Eyes	microphthalmia
Heart	atrial and ventricular septal defects, patent ductus arteriosus
Other	aplasia cutis congenita (scalp) and terminal transverse limb defects with hypoplastic or absent nails and variably absent distal phalanges

EXT1-CDG

Exostoses, multiple, type 1

Skeleton	multiple exostoses (projections of bone capped by cartilage), most numerous in the metaphyses of long bones, but also occurring on the diaphyses of long bones, deformity of forearms (resembling Madelung deformity), hands, legs, flat bones, vertebrae, and ribs but the skull is usually not involved
----------	---

Chondrosarcoma

Skeleton	chondrosarcoma of the pelvic bone, fibulae, and femora
----------	--

EXT2-CDG

Exostoses, multiple, type 2

Skeleton	multiple exostoses (projections of bone capped by cartilage), most numerous in the metaphyses of long bones, but also occurring on the diaphyses of long bones, deformity of forearms (resembling Madelung deformity), hands, legs, flat bones, vertebrae, and ribs but the skull is usually not involved
----------	---

(continued on next page)

Table 1 (continued)

<u>Seizures, scoliosis, and macrocephaly syndrome</u>	
Brain	psychomotor disability, macrocephaly, epilepsy, hypotonia, brain haemorrhage
Muscles	wide-based gait, tremor
Heart	ventricular septal defect, hypertension
Liver	dysfunction
Kidneys	haematuria with proteinuria, sometimes associated with haemolytic-uremic syndrome
Skeleton	scoliosis, overlapping toes; low bone density
Dysmorphic features	coarse facies with hypertelorism
Other	skin sensitivity, gastrointestinal problems (gastroesophageal reflux, bowel malrotation, diarrhoea/constipation), cryptorchidism in males

FKRP-CDG

Muscular dystrophy-dystroglycanopathy (congenital with brain and eye anomalies), type A, 5

Brain	psychomotor disability, hypotonia; agyria, absence of corpus callosum and cerebellar vermis, congenital hydrocephalus associated with a Dandy-Walker-like malformation, ventricular dilatation, aqueductal stenosis, dysplastic and small cerebellum and pons, cobblestone lissencephaly, pachygyria, hypoplastic brainstem, cerebellar cysts, white matter abnormalities
Eyes	myopia, anterior chamber abnormalities, microphthalmia, corneal clouding, coloboma, retinal pigmentary changes, asymmetric pupils, absent pupillary light reflexes, cataracts, rarefaction of pigment epithelium, no demarcation of the macula, bilateral retinal detachment
Muscles	dystrophy
Heart	left ventricular hypertrophy
Other	elevated serum creatine kinase

Muscular dystrophy-dystroglycanopathy (congenital with or without mental retardation), type B, 5

Brain	mental disability, hypotonia; cerebellar cysts
Muscles	wasting and weakness of shoulder girdle muscles and upper limbs, facial weakness, pronation of the forearm, Achilles tendon contractures, leg hypertrophy
Other	elevated serum creatine kinase

Muscular dystrophy-dystroglycanopathy (limb-girdle), type C, 5

Muscles	developmental disability, waddling gait, muscle cramps, frequent falls, hypotonia, proximal muscle weakness, shoulder girdle and hip girdle weakness, hypertrophy of tongue, calf muscles and thigh, absence of scapular winging, Achilles tendon contractures, restrictive respiratory insufficiency; histology: dystrophic changes
Heart	dilated cardiomyopathy, left ventricular wall motion abnormalities
Skeleton	hyperlordosis, (kypho)scoliosis, spinal fusion
Other	elevated serum creatine kinase

FKTN-CDG

Cardiomyopathy, dilated, 1X

Muscles	mild or no limb-girdle muscle involvement; minimal dystrophic features but hypoglycosylation of alpha-dystroglycan
Heart	dilated cardiomyopathy

Muscular dystrophy-dystroglycanopathy (congenital with brain and eye anomalies), type A, 4

Brain	intellectual disability, epilepsy; cerebellar micropolygyria, fibroglial proliferation of the leptomeninges, hydrocephalus, focal interhemispheric fusion, hypoplasia of the corticospinal tracts, presence of cerebellar cysts, frontoparietal pachygyria, cephalocele, flattening of the pons and brainstem, marked cerebellar vermis hypoplasia, cortical brain atrophy, absent corpus callosum, lissencephaly, ventricular dilatation; subcortical white matter abnormalities, patchy periventricular hyperintensities, white matter hyperlucencies
Eyes	strabismus, myopia, hyperopia, microphthalmia, congenital cataracts, buphthalmos, optical atrophy, retinal dysplasia and detachment
Muscles	diffuse and progressive muscle weakness and atrophy with axial and proximal limb predominance, moderate facial involvement, severe and progressive restrictive respiratory insufficiency, diffuse amyotrophy, progressive knee and ankle contractures, calf muscles hypertrophy; histology: muscle dystrophy with dystroglycanopathy
Heart	dilated cardiomyopathy (from 2 nd decade), structural defects
Skeleton	congenital arthrogryposis multiplex, spinal rigidity, scoliosis, congenital hip dislocation
Other	elevated serum creatine kinase

Muscular dystrophy-dystroglycanopathy (congenital with or without mental retardation), type B, 4

Brain	white matter changes
Muscles	generalized weakness; dystrophy and evidence of dystroglycanopathy
Other	increased serum creatine kinase

Muscular dystrophy-dystroglycanopathy (limb-girdle), type C, 4

Muscles	disabled motor disability, waddling gait, limb-girdle muscular dystrophy, proximal muscle weakness, frequent falls, hypertrophy of lower limb muscles, decreased deep tendon reflexes, mild hypotonia, decreased muscle strength, calf hypertrophy; histology: dystrophic features with dystroglycanopathy
Skeleton	lumbar lordosis, pectus excavatum, club feet
Other	increased serum creatine kinase

(continued on next page)

Table 1 (continued)

GALNT3-CDG <u>Tumoral calcinosis, hyperphosphatemic, familial</u>	
Soft tissues around major joints	ectopic calcifications (shoulders, elbows, knees ...), intolerable pain, skin ulcerations, secondary skin and bone infections; hyperphosphatemia
Other	*vascular calcifications, angioid streaks of the retina, dental abnormalities, testicular microlithiasis *hyperostosis-hyperphosphatemia syndrome (recurrent long bone lesions)
GANAB-CDG <u>Polycystic kidney disease 3</u>	
Liver	occasional presence of liver cysts, sometimes liver dysfunction
Kidneys	polycystic kidney disease, usually mild with onset in mid- to late-adulthood
GFPT1-CDG <u>Myasthenia, congenital, 12, with tubular aggregates</u>	
Peripheral nervous system	proximal muscle weakness due to defect at neuromuscular junction, waddling gait, muscle cramps, easy fatigability
Muscles	histology: small type 1 fibres and tubular aggregates in both fiber types
Other	increased serum creatine kinase
GMPPA-CDG <u>Alacrima, achalasia, and mental retardation syndrome</u>	
Brain	psychomotor disability
Eyes	alacrima, visual problems, anisocoria
Other	achalasia, feeding difficulties, gait abnormalities, hearing impairment, decreased sweating, postural hypotension, hyperkeratosis
GMPPB-CDG <u>Muscular dystrophy-dystroglycanopathy (congenital with brain and eye anomalies), type A, 14</u>	
Brain	intellectual disability, microcephaly; pontine and cerebellar hypoplasia
Eyes	retinal dysfunction
Muscles	severe muscle weakness, delayed walking, ataxia; dystroglycanopathy
Dysmorphic features	cleft palate
Other	sensorineural hearing loss
<u>Muscular dystrophy-dystroglycanopathy (congenital with mental retardation), type B, 14</u>	
Brain	intellectual disability, microcephaly, drug-resistant epilepsy, hypotonia; cerebellar hypoplasia
Eyes	strabismus, cataracts, ptosis
Muscles	generalized muscle weakness; dystrophy with dystroglycanopathy,
Heart	long QT syndrome, left ventricular dilatation
Skeleton	torticollis
Other	feeding difficulties, ileal atresia
<u>Muscular dystrophy-dystroglycanopathy (limb-girdle), type C, 14</u>	
Brain	intellectual disability, microcephaly, epilepsy, hypotonia
Eyes	nystagmus, cataracts
Muscles	limb-girdle muscular dystrophy, muscle weakness; histology: dystrophy, dystroglycanopathy
Heart	cardiomyopathy
Other	respiratory insufficiency
GNE-CDG <u>Nonaka myopathy</u>	
Muscles	distal muscle weakness and atrophy, relative sparing of the deltoid, biceps, and triceps, ocular, pharyngeal, and cardiac muscles are usually not involved, typical sparing of the quadriceps (onset early adulthood); EMG: myopathic changes, histology: 'rimmed vacuole myopathy' (abundant lined vacuoles and characteristic cytoplasmic inclusions of 15- to 18-nm in muscle fibers)
Other	increased serum creatine kinase
<u>Sialuria</u>	
Brain	developmental disability, macrocephaly, epilepsy
Liver	hepatosplenomegaly
Dysmorphic features	facial dysmorphism (coarse face, low-set ears, periorbital fullness, thin upper lip a.o.), hypoplastic nipples
Other	sleep apnoeas, inguinal hernias (males); massive urinary excretion of free sialic acid
ISPD-CDG <u>Muscular dystrophy-dystroglycanopathy (congenital with brain and eye anomalies), type A, 7</u>	
Brain	intellectual disability, encephalocele, hypotonia; hydrocephalus, agyria, cobblestone lissencephaly of the cerebral cortex, severe brainstem and cerebellar hypoplasia, atrophy of corpus callosum, ventriculomegaly, Dandy-Walker malformation, subcortical heterotopia
Eyes	microphthalmia, cataracts, Peters anomaly, optic nerve hypoplasia, retinal dysplasia, retinal detachment

(continued on next page)

Table 1 (continued)

Muscles	severe muscular dystrophy, weakness in the upper and lower limb girdles, tongue and calf hypertrophy, reduced forced respiratory vital capacity; muscle biopsies: dystrophic changes with hypoglycosylated alpha-dystroglycan
Dysmorphic features	facial dysmorphism (large fontanelles, frontal bossing, deep-set eyes, retrognathia, small, simple, low-set ears)
Other	neural tube defects, limb deformations; visceral malformations, brain vascular anomalies

Muscular dystrophy-dystroglycanopathy (limb-girdle), type C, 7

Muscles	proximal upper and lower limbs affected, calf hypertrophy, scapular winging, reduced forced respiratory vital capacity; histology: dystrophic changes with hypoglycosylated alpha-dystroglycan
Other	increased serum creatine kinase, myoglobinuria after exercise

LARGE-CDG

Muscular dystrophy-dystroglycanopathy (congenital with mental retardation), type B, 6

Brain	intellectual disability; periventricular and temporal white matter changes, posterior concavity of the brainstem, hypoplastic pons, frontoparietal pachygyria
Eyes	nystagmus; abnormal electroretinogram
Muscles	muscle hypertrophy of the tongue, calves, thighs, and shoulder girdle, and predominantly lower limb weakness with positive Gowers sign and waddling gait

LFNG-CDG

Spondylocostal dysostosis 3, autosomal recessive

Skeleton	long, slender fingers, camptodactyly of the left index finger, extensive congenital vertebral anomalies with severe shortening of the spine; vertebral ossification centres in the thoracic spine with fitted angular shape
----------	---

MAN1B1-CDG **

Brain	intellectual disability
Dysmorphic features	craniofacial dysmorphism (dolichocephaly, downslanting palpebral fissures, hypertelorism, broad and long eyebrows, flat philtrum, thin upper lip, triangular and pointed chin, prominent nose)
Other	truncal obesity

MGAT2-CDG **

Brain	psychomotor disability, microcephaly, epilepsy, stereotypic movements
Muscles	muscle atrophy
Dysmorphic features	craniofacial dysmorphism (retrognathia, large and posteriorly rotated ears, beaked nose, long philtrum, thin vermilion border of the upper lip, large mouth, diastema, gum hypertrophy, long eyelashes, thick eyebrows), short neck, thoracic deformity, distal limb anomalies; radioulnar synostosis
Other	chronic feeding problems with severe diarrhoea, gastroesophageal reflux and volvulus, recurrent respiratory infections, lack of pubertal development, sensorineural hearing loss

MOGS-CDG

Brain	developmental disability, epilepsy, hypotonia; cerebral atrophy, small corpus callosum
Eyes	optic nerve atrophy
Liver	hepatomegaly
Skeleton	recurrent bone fractures, thoracic scoliosis
Dysmorphic features	prominent occiput, retrognathia, short palpebral fissures, broad nose, high-arched palate, long eyelashes, generalized oedema
Other	sensorineural hearing loss, hypoplastic genitalia, chronic constipation, hypoventilation, feeding problems; hypogammaglobulinemia

MPDU1-CDG *

Brain	intellectual disability, epilepsy, ataxia
Eyes	strabismus, nystagmus, amaurosis, optic atrophy
Skeleton	dwarfism
Other	feeding difficulties, hyperkeratosis, erythroderma; transient growth hormone deficiency

MPI-CDG *

Liver	congenital hepatic fibrosis, microvesicular steatosis, cirrhosis
Other	secretory diarrhoea with protein-losing enteropathy, intestinal lymphangiectasia, recurrent thrombotic events, life-threatening gastrointestinal bleeding, frequent bacterial/viral gastroenteritis, hyperinsulinemic hypoglycaemia

NANS-CDG

Spondyloepimetaphyseal dysplasia, Camera-Genevieve type

Brain	developmental disability, microcephaly, epilepsy, ataxia; hydrocephalus, cerebral atrophy with nonspecific white matter changes, hypoplastic corpus callosum
Skeleton	spondyloepimetaphyseal dysplasia (shortening of trunk and limbs, premature carpal ossification, platyspondyly, longitudinal metaphyseal striations and small epiphyses)
Dysmorphic features	facial dysmorphism (prominent forehead, synophrys, sunken nasal bridge, prominent bulbous nasal tip, full lips a.o.)

(continued on next page)

Table 1 (continued)

NUS1-CDG *	
Brain	developmental disability, microcephaly, epilepsy, hypotonia; cortical atrophy
Eyes	visual impairment; mottling of the retinal pigment epithelium, macular lesions
Skeleton	scoliosis
Other	failure to thrive, hearing impairment, hypertrichosis
PGAP1-CDG	
Brain	developmental disability, microcephaly, hypotonia, stereotypic movements, dyskinetic movements; thinning of the corpus callosum, delayed myelination, agenesis of corpus callosum, cerebellar vermis hypoplasia; signal abnormalities in the central tegmental tracts of the pons
Eyes	strabismus, nystagmus, visual impairment; retinal dystrophy
Dysmorphic features	facial dysmorphism (prominent forehead, high-arched eyebrows, deep-set eyes, large abnormal earlobes, upslanting palpebral fissures, large mouth with abnormal teeth), short neck, abnormal hand morphology
PGAP2-CDG	
<u>Hyperphosphatasia with mental retardation syndrome 3</u>	
Brain	developmental disability, microcephaly, epilepsy, hypotonia; brain atrophy
Heart	atrial septal defect
Dysmorphic features	broad nasal bridge, cleft palate
Other	sensorineural hearing loss, Hirschsprung disease; increased serum alkaline phosphatase
PGAP3-CDG	
<u>Hyperphosphatasia with mental retardation syndrome 4</u>	
Brain	developmental disability, microcephaly, epilepsy, hypotonia
Dysmorphic features	facial dysmorphism (hypertelorism, upslanting palpebral fissures, broad nasal bridge, short nose, long philtrum, tented upper lip, full cheeks, and large fleshy earlobes)
Other	increased serum alkaline phosphatase
PGM1-CDG **	
Brain	cerebral thrombosis
Muscles	weakness of the pelvic-girdle muscles; histology: abnormal subsarcolemmal and sarcoplasmic accumulations of normally structured, free glycogen
Heart	dilated cardiomyopathy
Liver	chronic hepatitis, steatosis, fibrosis
Dysmorphic features	Pierre-Robin sequence, cleft palate, bifid uvula
Other	growth deficiency; hypogonadotropic hypogonadism
PGM3-CDG	
<u>Immunodeficiency 23</u>	
Brain	developmental disability, myoclonus, ataxia, dysarthria; myelination defect
Dysmorphic features	high-arched palate, narrow palpebral fissures
Immune system	recurrent infections, atopic diatheses, including asthma and allergies, autoimmune and immune-mediated disease (cutaneous leukocytoclastic vasculitis, membranoproliferative glomerulonephritis, and autoimmune hemolytic anemia); lymphopenia, neutropenia, increased serum IgA, IgE, IgG, cytokine abnormalities
Other	hearing loss, cutaneous vasculitis
PIGA-CDG	
<u>Multiple congenital anomalies-hypotonia-seizures syndrome 2</u>	
Brain	developmental disability, epilepsy, hypotonia; thin corpus callosum, white matter immaturity, delayed myelination, absence of septum pellucidum, lack of olfactory bulb and tracts, cerebellar hypoplasia, dysplastic pons, abnormal cortical lamination
Muscles	hyperreflexia, contractures
Heart	atrial septal defect
Dysmorphic features	Facial dysmorphism (Pierre-Robin sequence, prominent occiput, enlarged fontanel, high anterior hairline, depressed nasal bridge, short and anteverted nose, malar flattening, upslanted palpebral fissures, overfolded helix, small mouth with downturned corners, absence of teeth), short neck
Other	hypoplastic nails; increased serum alkaline phosphatase in some patients
PIGC-CDG	
Brain	developmental disability, epilepsy
PIGG	
Brain	developmental and intellectual disability, epilepsy, hypotonia; thin corpus callosum, asymmetry of the lateral ventricles, cerebellar hypoplasia, cerebral atrophy
Muscles	hyporeflexia
PIGL-CDG	
<u>CHIME syndrome</u>	

(continued on next page)

Table 1 (continued)

Brain	intellectual disability, epilepsy
Eyes	retinal coloboma
Heart	transposition of the great vessels, ventricular septal defect, tetralogy of Fallot
Skeleton	short stature
Skin	ichthyosiform dermatosis
Dysmorphic features	craniofacial dysmorphism (bifida uvula, submucous cleft, ear anomalies, brachycephaly)
Other	hearing loss

PIGM-CDG

Brain	epilepsy
Liver	portal vein thrombosis

PIGN-CDG

Multiple congenital anomalies-hypotonia-seizures syndrome 1

Brain	developmental/intellectual disability, epilepsy, hypo-/hypertonia, spasticity; cerebellar atrophy, progressive white matter disease
Eyes	nystagmus, roving eye movements
Liver	splenomegaly
Kidneys	hydronephrosis
Dysmorphic features	craniofacial dysmorphism (brachycephaly, micrognathia, flat face, depressed nasal bridge, small nose and mouth, small and abnormally shaped ears, upslanting palpebral fissures, epicanthal folds, synophrys, bitemporal narrowing, high-arched palate), short neck, hypoplasia distal phalanges, anal stenosis, imperforate anus, diaphragmatic hernia
Other	gastroesophageal reflux

PIGO-CDG

Hyperphosphatasia with mental retardation syndrome 2

Brain	developmental/intellectual disability, microcephaly, epilepsy, hypotonia, left coronal synostosis; enlarged ventricles
Heart	atrial septal defect, peripheral pulmonary stenosis
Dysmorphic features	facial dysmorphism (wide-set eyes with long palpebral fissures, short nose with broad nasal bridge and tip, tented mouth), anal stenosis, anal atresia (with perineal fistula), brachytelephalangy, nail hypoplasia

PIGP-CDG

Brain	intellectual disability, epilepsy, hypotonia, peripheral hypertonia; thin corpus callosum
Eyes	cortical visual impairment, episodes of sustained eye deviation

PIGQ-CDG

Brain	developmental disability, epilepsy
-------	------------------------------------

PIGT-CDG

Paroxysmal nocturnal hemoglobinuria 2 (a germline mutation associated with a somatic mutation)

Other	hemolytic anemia, frequent hemolytic crises, abdominal pain, diarrhea, headache, arthralgia, dyspnea, fatigue, cold-induced urticaria
-------	---

Multiple congenital anomalies-hypotonia-seizures syndrome 3

Brain	psychomotor disability, epilepsy, hypotonia; frontotemporal atrophy, cerebellar hypoplasia
Eyes	strabismus, nystagmus, visual impairment
Heart	restrictive cardiomyopathy, patent ductus arteriosus
Liver	nephrocalcinosis, ureteral stenosis/dilation
Skeleton	scoliosis, pectus excavatum, short upper extremities, slender long bones, arthrogryposis; wide and long femoral necks, delayed bone age, osteoporosis, osteopenia, large secondary ossification centers
Dysmorphic features	craniofacial dysmorphism (macrocephaly, brachycephaly, high forehead with bitemporal narrowing, long philtrum with a deep groove, open mouth, micrognathia, malar flattening, upslanting palpebral fissures, depressed nasal bridge with anteverted nares, downturned corners of the mouth, tented lip, high-arched palate, tooth abnormalities)

Other	macrosomia, tooth abnormalities; decreased serum alkaline phosphatase, increased serum calcium
-------	--

PIGV-CDG

Hyperphosphatasia with mental retardation syndrome 1

Brain	developmental/intellectual disability, epilepsy
Muscles	hypotonia
Heart	ventricular septal defect
Kidneys	hydronephrosis
Dysmorphic features	craniofacial dysmorphism (macrocephaly, cleft lip/palate, hypertelorism, broad nasal bridge, tented mouth, simple cupped ears with thickened helices), brachytelephalangy
Other	displaced anus, Hirschsprung disease, hypoplastic terminal phalanges, hypoplastic nails, hearing impairment; elevated serum alkaline phosphatase

PIGW-CDG

Hyperphosphatasia with mental retardation syndrome 5

Brain	intellectual disability, epilepsy, hypotonia
Dysmorphic features	broad nasal bridge, tented upper lip
Other	hyperphosphatasia

(continued on next page)

Table 1 (continued)

PIGY-CDG <u>Hyperphosphatasia with mental retardation syndrome 6</u>	
Brain	developmental disability, microcephaly, epilepsy, behavioural disturbances
Eyes	congenital cataracts
Muscles	variation in muscle fiber size with small rounded atrophic fibers and increased fibrosis
Kidneys	dilatation of the renal collecting systems, increased echogenicity of renal parenchyma
Skeleton	osteopenia
Dysmorphic features	facial dysmorphism (bitemporal narrowing, long palpebral fissures, depressed nasal bridge with upturned nares, deep-set eyes, fleshy earlobes), short neck, brachytelephalangy, proximal limb shortening; hip dysplasia
Other	necrotizing enterocolitis, chronic lung disease; increased serum alkaline phosphatase and creatine kinase
PMM2-CDG *	
Brain	psychomotor disability, hypotonia, ataxia, stroke-like episodes, peripheral polyneuropathy; cerebellar hypoplasia
Eyes	internal strabismus, retinitis pigmentosa
Muscles	hyporeflexia
Liver	mild hepatopathy
Dysmorphic features	fusiform phalanges of the fingers, prominent labia majora, inverted nipples, symmetric fat accumulations, lipodystrophy of the buttocks
Other	thrombotic tendency, pericarditis, increased serum insulin and growth hormone
POFUT1-CDG <u>Dowling-Deegos disease 2</u>	
Skin	hypo-/hyperpigmentation in reticular pattern on flexural skin, hyperkeratotic papules on neck, chest and back; electronmicroscopy: melanocytes lack melanosomes
POGLUT1-CDG <u>Dowling-Deegos disease 4</u>	
Skin	brownish macular and lentiginous lesions on extremities, trunk and neck; histology: digitiform acanthosis, focal hypergranulosis
<u>Limb-girdle muscular dystrophy type 2Z</u>	
Muscles	proximal muscle weakness affecting first lower limbs, and later upper limbs; histology: dystrophy, dystroglycanopathy
Other	impaired respiratory function; increased serum creatine kinase
POMGNT1-CDG <u>Muscular dystrophy-dystroglycanopathy (congenital with brain and eye anomalies), type A, 3</u>	
Brain	psychomotor disability, microcephaly, epilepsy, hypotonia; hydrocephalus, cerebellar hypoplasia/dysplasia, cerebellar cysts, cortical dysplasia, brainstem abnormalities, pontine hypoplasia, ventricular dilatation, polymicrogyria, pachygyria, agyria, cobblestone cortex, white matter abnormalities, lissencephaly, complete or partial absence of corpus callosum
Eyes	cataracts, glaucoma, high myopia, microphthalmia, buphthalmos; retinal dysplasia, optic nerve hypoplasia
Muscles	dystrophy, dystroglycanopathy
Dysmorphic features	facial dysmorphism (everted lower lip, short nasal bridge, mild micrognathia, midface hypoplasia)
<u>Muscular dystrophy-dystroglycanopathy (congenital with mental retardation), type B, 3:</u>	
Brain	intellectual disability; ventricular dilatation, diffuse white matter changes, cerebellar cysts, pontine hypoplasia
Eyes	strabismus, myopia; optic atrophy
Muscles	dystrophy; dystroglycanopathy
<u>Muscular dystrophy-dystroglycanopathy (limb-girdle), type C, 3:</u>	
Muscles	proximal muscle weakness and wasting, hypertrophy of the calves and quadriceps; histology: dystrophic changes, dystroglycanopathy
Other	increased serum creatine kinase
<u>Retinitis pigmentosa 76</u>	
Eyes	nyctalopia, reduced visual acuity, constricted visual fields; peripapillary atrophy, bone spicule pigmentation, narrow retinal vessels, peripapillary atrophy, tigroid appearance of the fundus, retinal thinning with absent inner/outer segment junctions, chorioretinal atrophy, flat fovea, optic disc pallor, cystoid macular edema
POMT1-CDG <u>Muscular dystrophy-dystroglycanopathy (congenital with brain and eye anomalies), type A, 1</u>	
Brain	developmental/intellectual disability, epilepsy, hypotonia; hydrocephalus, ventricular dilatation, frontal bossing, ventriculomegaly, minimal cortical development, no visible gyri, vermis and cerebellar hypoplasia, cerebellar cysts, cobblestone lissencephaly with agyria and agenesis of the corpus callosum, encephalocele, pachygyria/agyria, Dandy-Walker-like malformation, frequent flattening of the pons and brainstem, polymicrogyria, white matter abnormalities
Eyes	microphthalmia, exophthalmia, buphthalmos, megalocornea, glaucoma, cataract, corneal clouding, progressive myopia; retinal atrophy, retinal detachment
Muscles	dystrophy, dystroglycanopathy
Other	increased serum creatine kinase

(continued on next page)

Table 1 (continued)

<u>Muscular dystrophy-dystroglycanopathy (congenital with mental retardation), type B, 1</u>	
Brain	psychomotor disability, hypotonia; enlarged cisterna magna, cerebellar hypoplasia
Muscles	dystrophy, muscle wasting, pseudohypertrophy of calf and quadriceps muscles
Skeleton	joint contractures, scoliosis
Dysmorphic features	macroglossia
Other	increased serum creatine kinase

Muscular dystrophy-dystroglycanopathy (limb-girdle), type C, 1

Brain	intellectual disability, microcephaly
Muscles	limb-girdle muscular dystrophy, muscle pseudohypertrophy; dystroglycanopathy
Heart	cardiomyopathy
Skeleton	lordosis
Other	increased serum creatine kinase

POMT2-CDG

Muscular dystrophy-dystroglycanopathy (congenital with brain and eye anomalies), type A, 2

Brain	developmental disability, microcephaly, epilepsy, hypotonia; hydrocephalus, cobblestone lissencephaly, pachygyria with preferential frontoparietal involvement, polymicrogyria, cerebellar hypoplasia/dysplasia, aplasia of the corpus callosum, smooth cortical mantle, brainstem hypoplasia, pontine hypoplasia, ventricular dilatation, pachygyria, polymicrogyria, heterotopia, cerebellar cysts, periventricular white matter abnormalities
Eyes	Peters anomaly, cataracts, microphthalmia, buphthalmos, persistent pupillary membrane, hypermetropia, congenital glaucoma, progressive myopia, retinal atrophy
Muscles	muscle weakness, contractures, muscle hypertrophy of the lower limbs; histology: muscular dystrophy, dystroglycanopathy
Dysmorphic features	cleft lip and palate, macroglossia
Other	increased serum creatine kinase

Muscular dystrophy-dystroglycanopathy (congenital with mental retardation), type B, 2

Brain	developmental/intellectual disability, microcephaly, hypotonia; cortical atrophy, cerebellar vermis hypoplasia without brainstem involvement, flat pons, ventriculomegaly, hypoplasia of the corpus callosum; periventricular white matter abnormalities
Eyes	myopia, strabismus; pigmentary retinopathy
Muscles	muscle weakness in face, trunk, girdle muscles, tongue, calf muscle hypertrophy, diffuse joint contractures, decreased or absent deep tendon reflexes; histology: dystrophy, dystroglycanopathy
Heart	left ventricular hypertrophy, aortic root dilatation
Skeleton	lordosis, scoliosis, hip dislocation
Other	micropenis, cryptorchidism; increased serum creatine kinase

Muscular dystrophy-dystroglycanopathy (limb-girdle), type C, 3

Muscles	limb-girdle muscular dystrophy, calf hypertrophy; histology: dystrophic and inflammatory changes, dystroglycanopathy
---------	--

PRKCSH-CDG

Polycystic liver disease 1

Liver	multiple liver cysts
-------	----------------------

RFT1-CDG *

Brain	developmental/intellectual disability, microcephaly, early-onset epilepsy, hypotonia, hyperreflexia
Eyes	decreased visual acuity
Dysmorphic features	micrognathia, short neck, adducted thumbs, valgus foot deformities, inverted nipples
Other	feeding difficulties, failure to thrive, sensorineural deafness, short stature

SEC23B-CDG

Dyserythropoietic anemia, congenital, type II

Liver	splenomegaly, cholelithiasis
Blood	dyserythropoietic anemia: increased reticulocytes, multinucleated erythroblasts, increased erythrocyte osmotic fragility and hypoglycosylation of red blood cell membranes

SLC35A1-CDG **

Brain	developmental disability, microcephaly, epilepsy, ataxia, hyporeflexia
Kidneys	proteinuria
Dysmorphic features	facial dysmorphism, webbed neck
Other	bleeding diathesis, macrothrombocytopenia

SLC35A2-CDG **

Brain	intellectual/developmental disability, microcephaly, epilepsy, hypotonia; small cerebellum, thinning of the corpus callosum, delayed myelination, cerebral and cerebellar atrophy
Kidneys	acute nephrotic syndrome
Dysmorphic features	facial dysmorphism (coarse facies, thick eyebrows, broad nasal bridge, thick lips, semi-open mouth, maxillary prognathism)
Other	poor feeding, recurrent infections, shortened limbs

(continued on next page)

Table 1 (continued)

SLC35A3-CDG <u>Arthrogryposis, mental retardation, and seizures</u>	
Brain	intellectual disability, microcephaly, autism spectrum disorder, epilepsy
Muscles	hypotonia
Skeleton	arthrogryposis, deviation of the distal phalanges, swan-neck deformity, knee and hip dislocation
Dysmorphic features	retromicrognathia
SLC35C1-CDG	
Brain	intellectual disability, microcephaly, epilepsy, hypotonia; cortical atrophy
Skeleton	dwarfism
Dysmorphic features	facial dysmorphism
Other	recurrent infections with neutrophilia (pneumonia, periodontitis, otitis media, and cellulitis without pus formation), Bombay blood group
SLC35D1-CDG <u>Schneckenbecken dysplasia</u>	
Skeleton	dwarfism, large head, flat midface, cleft palate, narrow chest, short splayed ribs, round vertebral bodies, snail-shaped ilia, dumbbell-shaped short long bones, brachydactyly, precociously ossified carpal and tarsal bones
Other	stillborn or lethal in newborn period
SLC39A8-CDG **	
Brain	psychomotor disability, epilepsy, hypotonia; cerebellar atrophy
Eyes	strabismus, nystagmus, hyperopia, astigmatism
Skeleton	short stature, short limbs, craniosynostosis, osteopenia
Other	recurrent infections, hearing impairment
SRD5A3-CDG *	
Brain	developmental/intellectual disability, hypotonia; cerebellar atrophy, vermis malformations, hypoplasia of the pituitary gland
Eyes	visual loss, nystagmus; congenital malformations (coloboma, hypoplasia of the optic disc, ...)
Heart	dilated cardiomyopathy
Skin	palmoplantar keratoderma, ichthyosiform dermatitis, hypertrichosis, dark skin of the dorsum of hands and feet
Other	increased serum transaminases, decreased antithrombin III
<u>Kahrizi syndrome</u>	
Brain	severe intellectual disability, psychomotor disability
Eyes	cataracts with onset in late adolescence, iris coloboma
Skeleton	kyphosis, contractures of large joints
Dysmorphic features	bulbous nose with broad nasal bridge, thick lips
SSR4-CDG *	
Brain	developmental/intellectual disability, epilepsy, hypotonia; thin corpus callosum, decreased periventricular white matter, absence of septum pellucidum
Eyes	strabismus, deep-set eyes
Skeleton	scoliosis
Dysmorphic features	Facial dysmorphism (micrognathia, large mouth with widely spaced teeth, large ears, hypoplastic vermillion of the upper lip), excess skin around the neck, fat pads, hypospadias, clinodactyly of fourth and fifth toes
Other	failure to thrive, gastrointestinal reflux
ST3GAL3-CDG <u>Epileptic encephalopathy, early infantile, 15. Mental retardation</u>	
Brain	developmental/intellectual disability, epilepsy, hypotonia, irritability
ST3GAL5-CDG <u>Salt and pepper developmental regression syndrome</u>	
Brain	psychomotor disability, microcephaly, epilepsy, hypotonia, hyporeflexia of upper limbs, hyperreflexia of lower limbs, irritability, choreoathetotic movements; white matter lesions, cortical atrophy
Eyes	nystagmus, optic atrophy
Skin	dyspigmentation, hyperpigmented macules mainly on extremities, hypopigmented macules (less common)
Other	poor feeding, vomiting, failure to thrive
STT3A-CDG *	
Brain	psychomotor disability, microcephaly, epilepsy, hypotonia; cerebellar atrophy
Eyes	poor visual tracking
Other	failure to thrive
STT3B-CDG *	
Brain	psychomotor disability, microcephaly, epilepsy, hypotonia; cerebellar atrophy
Eyes	optic nerve hypoplasia
Liver	liver involvement
Other	failure to thrive, micropenis, hypoplastic scrotum; thrombocytopenia

(continued on next page)

Table 1 (continued)

TMEM165-CDG **	
Brain	psychomotor disability, epilepsy; white matter abnormalities, hypoplasia of the pituitary gland
Eyes	strabismus, ptosis
Muscles	muscle weakness
Liver	hepatosplenomegaly
Skeleton	growth deficiency, kyphoscoliosis; osteoporosis, anterior beaking of vertebrae, dysplastic vertebrae, ribs, fourth metacarpals and metatarsals, hypoplasia of femoral heads and epiphyseal, metaphyseal, and diaphyseal dysplasia
Dysmorphic features	facial dysmorphism (macrocephaly, midface hypoplasia, tongue protrusion, downslanting palpebral fissures, flat nose, and low-set posteriorly rotated ears, long philtrum, high-arched palate), short and broad neck, broad thorax, sacral dimple, absent second toenails
Other	wrinkled skin, dense hair, long and dense eyelashes, abnormal fat distribution, joint laxity, fever episodes, amelogenesis imperfecta, delayed dentition, hoarse voice
TMEM199-CDG **	
Brain	psychomotor disability, hypotonia
Liver	steatosis, fibrosis, vacuolization of hepatocytes, decreased serum ceruloplasmin, hypercholesterolemia, increased serum alkaline phosphatase
TMEM5-CDG	
<u>Muscular dystrophy-dystroglycanopathy (congenital with brain and eye anomalies), type A, 10</u>	
Brain	developmental disability, microcephaly; severe cobblestone lissencephaly, occipital neural tube defects, occipital encephalocele, hydrocephaly, brainstem atrophy, dilated ventricles, widespread pachygyria
Eyes	microphthalmia, cataract, opaque cornea; retinal dysplasia
Muscles	hypotonia
Dysmorphic features	facial clefts
Other	gonadal dysgenesis; increased serum creatine kinase
TRAPPC11-CDG #	
<u>Muscular dystrophy, limb-girdle, type 2S</u>	
Brain	developmental/intellectual disability, epilepsy, choreiform movements, dystonia, ataxia, tremor; cerebral/cerebellar atrophy, reduced white matter volume
Eyes	strabismus, myopia, cataracts, alacrima
Muscles	proximal muscle weakness with shoulder girdle muscles less severely affected than hip girdle muscles, cramps; histology: dystrophic changes with necrotic and regenerating fibers, endomysial fibrosis, increased lipid droplets
Liver	hepatomegaly; increased serum transaminases, steatosis
Skeleton	scoliosis, lordosis, hip dysplasia
Other	restrictive pulmonary function, achalasia; increased serum creatine kinase
TUSC3-CDG *	
Brain	mental disability
VPS13B-CDG	
<u>Cohen syndrome</u>	
Brain	psychomotor disability, microcephaly, epilepsy, hypotonia; cerebellar hypoplasia, large corpus callosum
Eyes	myopia, decreased visual activity; chorioretinal dystrophy, optic atrophy
Heart	mitral valve prolaps
Skeleton	lordosis, genua valga, narrow hands, mild shortening of metacarpals
Dysmorphic features	facial dysmorphism (maxillary hypoplasia, prominent central incisors, micrognathia, short philtrum), thick hair, low hairline
Other	truncal obesity with slender extremities, short stature, delayed puberty; growth hormone deficiency, leukopenia, neutropenia
XYLT1-CDG	
<u>Desbuquois dysplasia 2</u>	
Brain	intellectual disability, hypotonia
Skeleton	short stature, short extremities, multiple dislocations of large joints, plump and stocky long bones with metaphyseal widening, short femoral necks, broad ribs, shortened clavicles, epiphyseal dysplasia, advanced carpal and tarsal ossification
Dysmorphic features	macrocephaly, facial dysmorphism (flat face with prominent eyes, synophrys, deep nasal ridges, full lips, long philtrum), broad thumbs, clinodactyly, coxa valga
Other	truncal obesity
XYLT2-CDG	
<u>Spondylo-ocular syndrome</u>	
Brain	learning difficulties
Eyes	nystagmus, cataract (juvenile); retinal detachment
Heart	atrial septal defect, mitral valve prolapse, dysplastic aortic valve
Skeleton	normal height with short trunk, immobile spine with thoracic kyphosis, lumbar lordosis, osteoporosis, marked platyspondyly, advanced bone age, bone fragility, multiple vertebral compression fractures with generalized vertebral flattening
Dysmorphic features	low posterior hairline, facial dysmorphism, short webbed neck, shield chest, long fingers and toes, overriding second and third toes
Other	hearing impairment, undescended testes

* refers to a type 1 serum transferrin pattern, while ** refers to a type 2. # indicates that the glycosylation of serum transferrin has not been investigated.

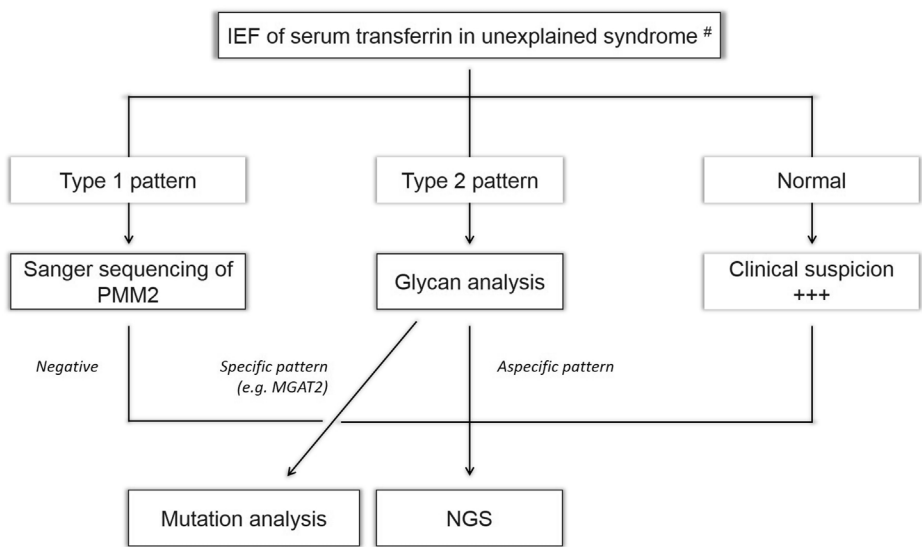


Fig. 1. Updated diagnostic flowchart for unsolved CDG. IEF: isoelectrofocusing; NGS: next generation sequencing (CDG panel, exome or genome sequencing). #: we recommend to perform serum transferrin IEF twice, using independent serum samples.

Eastern Europe. The prevalence of CDG in Europe could then approach 0.1–0.5/100,000, which is far from the one of only PMM2-CDG calculated on the basis of carrier frequencies (1/20 000; Schollen et al., 2000, 1/77 000; Vals et al., 2017). Thus, CDG is still largely under-diagnosed, even in Europe, the most active region with regard to CDG screening worldwide. This under-diagnosis leads to under-treatment since some CDG are treatable, in particular MPI-CDG (mannose; de Lonlay et al., 2001), and PGM1-CDG and SLC35A2-CDG (galactose; Morava, 2014; Dörre et al., 2015).

The number of molecularly unsolved CDG patients (after exclusion of galactosemia and fructosemia, see section 2.3 for more details) decreases thanks to targeted and whole exome sequencing. As expected, CDG-I appeared to be much more frequent than CDG-II. This is logical since 30 of the known 105 CDG show a Tf IEF type 1 pattern, while only 18 CDG show a type 2 pattern (48 in total; review in Jaeken and Péanne, 2017). Thus only about half of the known CDG are picked up by this test. Among these 48 CDG, eleven did not show up in this survey performed by our network.

In conclusion, these preparatory results on CDG frequency will be a helpful tool in accompanying the development of new therapeutics for CDG patients and should be followed by setting up a patient register containing full clinical and biological data.

2.3. Treatment

2.3.1. Therapeutic trials in cells

An important pitfall in the field of many inherited metabolic disorders is the lack of good cellular models for testing therapeutic drugs. The cells most commonly used are patient-derived fibroblasts. However in diseases such as CDG these cells are not representative for the cells that are involved in CDG pathophysiology. Furthermore, for testing mutation-specific therapies cellular models are needed with specific mutations. Recently, the generation of induced pluripotent stem cells (iPSCs) and the number of reports on its applications have rapidly increased because these cells provide a unique platform to carry out in vitro drug screening tests (Thiesler et al., 2016). Nevertheless, the generation of a battery of iPSCs bearing different mutations for successful therapeutic evaluation is a complex task. This prompted B. Pérez and coworkers to develop other cellular models. They have generated a biobank of patient-derived fibroblasts overexpressing hypomorphic mutant alleles. This cellular model allows a rapid screening of potential drugs to be selected for further evaluation in neurons or hepatocytes derived from iPSCs and, in the last step, for evaluation in animal models (unpublished results). In addition, methodologies to generate knock-out cell lines for specific gene defects have been established within the EURO-CDG network, including Hap1, HEK293 and C2C12 cells.

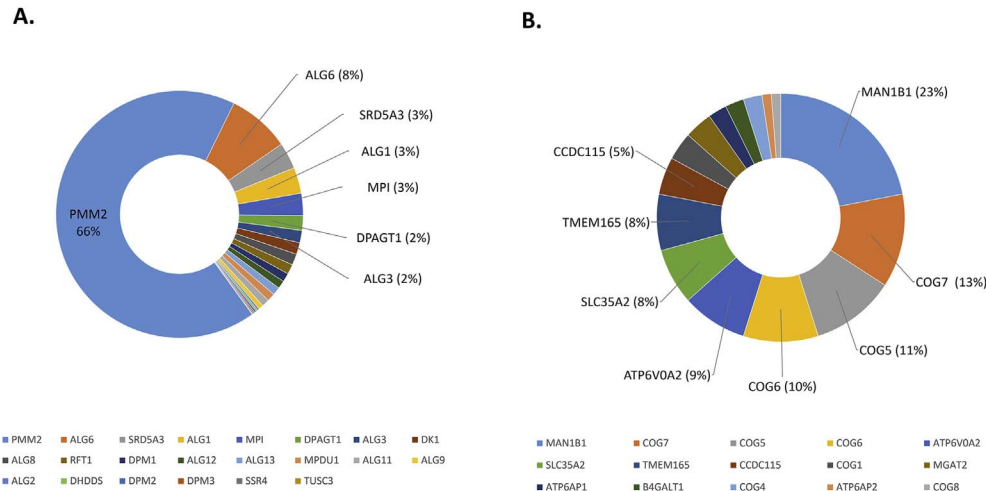


Fig. 2. Distribution among twelve European laboratories of (A) CDG-I patients, and (B) CDG-II patients. For more clarity, only the CDG-I with a frequency higher than 3% (left panel) or the CDG-II with a frequency higher than 5% (right panel) are displayed.

2.3.2. Treatment strategies in patients

MPI-CDG was the first CDG with a fairly effective treatment. Initial studies showed significant clinical improvement on dietary intervention with oral mannose (1 g/kg per day divided in 3–4 doses), improving the serum transferrin isoform pattern, coagulation anomalies, hyperinsulinism and the protein losing enteropathy. Mannose therapy acts by its transformation into mannose-6-phosphate, thus restoring the defective pathway. Some patients require higher doses and a few patients do not tolerate mannose due to recurrent hemolysis. Although mannose reduces serum transaminase levels, it does not cure the liver disease in MPI-CDG. Several MPI-CDG patients are known with progressive liver cirrhosis and liver failure on mannose therapy. Liver transplantation has been shown to be beneficial in a few patients with full clinical recovery (Janssen et al., 2014).

PGM1-CDG involves several metabolic pathways, including glycolysis, glycolysis and glycosylation. Galactose therapy has been introduced based on the hypogalactosylation pattern of protein glycans in this disorder. It improves the mixed type of N-glycosylation defect. While the Tf IEF type 2 pattern normalizes quickly, a full restoration is rarely observed. Depending on the patient, dietary galactose in a dose of 0.5–1.5 g/kg per day decreased serum transaminase levels and increased coagulation factors, especially antithrombin. Some patients showed better endocrine control, and a decrease in the frequency of hypoglycemia and rhabdomyolysis. Muscle weakness and cardiomyopathy seem to be unaffected by the galactose intervention in PGM1 deficiency. In a few patients uridine was added, but the effect hereof is not clear yet (Tegtmeyer et al., 2014; Morava, 2014; Wong et al., 2017).

CAD-CDG is a disorder in the pyrimidine biosynthesis, important for glycosylation through its role in nucleotide biosynthesis. Both the severe seizures and the microcytic anemia are treatable by oral uridine supplements (Koch et al., 2017). Uridine is an efficient treatment because it is a product of the defective pathway. Monosaccharide supplementation is a partial treatment for individual patients in several other N-glycosylation disorders. Oral galactose supplementation improved seizures and a few blood parameters including Tf IEF in a subset of SLC35A2-CDG patients (Dörre et al., 2015), and the bleeding diathesis, endocrine function and Tf IEF in TMEM165-CDG (Morelle et al., 2017). Both galactose and manganese improved the transferrin isoforms and the seizure disorder in SLC39A8-CDG (Park et al., 2015). The treatment with mannose, galactose, manganese, and a possible treatment with chaperones for PMM2-CDG is illustrated in Fig. 3. Oral fucose treatment improved the immune disorder and decreased infection frequency in a few patients with SLC35C1-CDG (Wild et al., 2002).

Besides in MPI-CDG, liver transplantation has also been performed with partial success in CCDC115-CDG (Jansen et al., 2016a, 2016b). Heart transplantation was successful in 2 children with mild DOLK-CDG (Kapusta et al., 2013), and bone marrow transplantation led to improvement of the immune disease in PGM3-CDG (Stray-Pedersen et al., 2014). Other potential therapeutic approaches aim at specific symptoms like hypoglycemia, hypothyroidism, pericarditis. Congenital myasthenia such as in DPAGT1-CDG can be treated with cholinesterase inhibitors (Finlayson et al., 2013).

2.4. Pathophysiology

A disordered glycosylation machinery does not only influence the glycoprotein and glycolipid homeostasis, but can also have a significant secondary impact on other cellular pathways. The other way around, some metabolic diseases such as galactosemia and fructose intolerance, cause a secondary glycosylation disorder. They show a type 1 pattern. Equally, alcoholism show a type 1 pattern while infections with neuraminidase-producing bacteria cause a type 2 pattern.

Although these hypoglycosylation devious side effects were expected, they were somewhat out of the scope and began to gain center stage just recently. First of course is the polyisoprenoid (or mevalonate) pathway which is necessary for the synthesis of cholesterol and the oligosaccharide lipid-carrier dolichol. Both are directly associated with and influenced by the glycosylation process. A group of CDG, most prominently exemplified by the COG-related CDG, is secondary to perturbation of the in- and outward vesicular trafficking at the Golgi apparatus (Reynders et al., 2011). Since these transport processes play central roles independent of protein glycosylation, the related disorders are probably caused by a combination of protein hypoglycosylation and defects in exo- and endocytosis, lysosomal function, and/or autophagy. There is also a rising interest in pathways leading to the generation of other metabolites such as aminoacids, acylcarnitines and lipids. In a patient with ATP6AP1-CDG, dysregulated levels of several amino acids (e.g. arginine) and strong up-regulated levels of acylcarnitines of the long and very long species were found. Besides, within the main and minor lipid classes reduced amounts of e.g. phosphatidylcholine in combination with abnormalities of the plasmalogens were detected (C. Thiel and co-workers, unpublished results).

It is worth mentioning that, as in CDG, defects in the metabolism of amino acids and in the biosynthesis and remodelling of phospholipids, sphingolipids and complex fatty acids can lead to pathology of the nervous system and many other organs (de Koning, 2013; Lamari et al.,

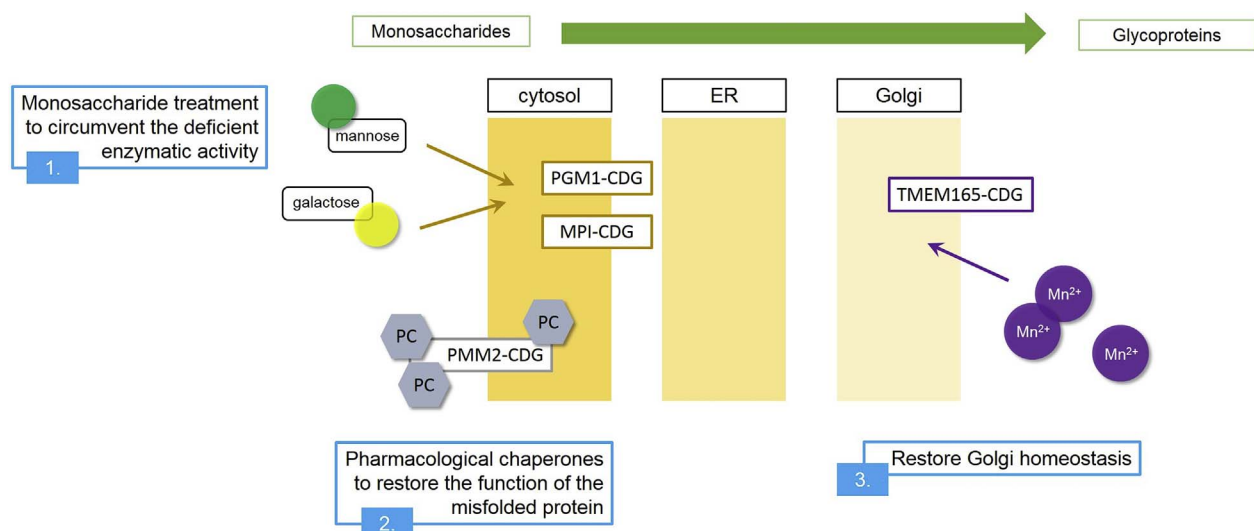


Fig. 3. Schematic representation of some promising CDG treatments. Even if more treatments are being investigated (for instance for SLC35A2-CDG, CAD-CDG, SLC39A8-CDG or SLC35A1-CDG), only the therapeutic approaches developed within the European EURO-CDG network are illustrated.

2015). More metabolomic analyses of patient material as well as of CDG animal models will help to further elucidate the role of glycosylation in other pathways. This will be of major help in understanding the complex pathophysiology underlying a glycosylation deficiency and in establishing new therapeutic approaches.

2.5. Patients and parents involvement

The parents have been very active in raising awareness for CDG and in helping families. They have also contributed to the commitment of the basic and clinical research community for CDG. At the risk of not being comprehensive and forgetting to honour several organisations that have been active in CDG – and the people that are the drivers behind these associations – we want to name a few that have contributed significantly. First, there have been parents associations in Denmark (Den Danske CDG Forening), in Germany (Glycokids®), in Sweden (Svenska CDG-Föreningen) and later associations were founded in Canada (Foundation Glycosylation (the FoG)), France (Les P'tits CDG), the Netherlands (CDG Netherlands), Portugal (Associação Portuguesa CDG, APCDG), Spain (AES CDG), and the UK (CDG UK), who have been very active at the national level. Prior to these, the American CDG Family Network Inc. has organized meetings in association with the EUROGLYCAN, EUROGLYCANET and EURO-CDG networks, a.o. in Leuven (1999) and in Worms (2008).

In 2013, the Portuguese CDG Association has organised in Barcelona the first World Conference on CDG, a gather of patients, parents, policy makers, representatives from industry and scientists. The second and third World Conference took place in Lyon in 2015 and in Leuven in 2017, the latter again in conjunction with EURO-CDG. Reports and videos of these gatherings are available (<http://www.apcdg.com/>). Thanks to joint programs for parents, clinicians and basic scientists, a strong impetus is given to research in the field of CDG. A very interesting leaflet providing general information on CDG to parents has been developed by clinicians, scientists from the Barcelona Hospital Sant Joan de Déu, together with the parents (see http://www.euroglycanet.org/uz/digitalAssets/1006_P05-Barcelona-Triptico_CDG.pdf). Other information is available at the patients' and parents' association websites. For information on 'inclusive education' see <https://www.includ-ed.eu/>, <http://aaate.net/> and <https://www.european-agency.org/>.

3. The future of CDG

3.1. Developments in the diagnostics of CDG: protein-specific glycoprofiling and metabolic labelling as functional diagnostic tools

About 50 genetic glycosylation defects are known that can be screened for by Tf IEF (Jaeken and Péanne, 2017). The identification of novel types of CDG-I, with a defect in the cytosol or endoplasmic reticulum (ER), has been very successful thanks to direct metabolic labelling of cultured CDG patients' cells with radioactive [2-³H] mannose (Péanne et al., 2013). Following lipid-linked oligosaccharide (LLO) analysis, the culprit gene could relatively easily be identified thanks to the high level of conservation of the N-glycosylation pathway in the ER between humans and yeast. Next-generation sequencing, via whole-exome sequencing or targeted gene panels, has replaced LLO analysis for gene identification. In combination with clinical phenotyping, an efficient diagnostic protocol for CDG-I subtyping has been achieved. For identification of CDG-II defects, glycan structural analysis by glycomics has been instructive to define genetic defects, such as MGAT2-, SLC35C1-, SLC35A1-, B4GALT1- and MAN1B1-CDG, that are directly associated with enzymes and transporters involved in the Golgi processing of glycans (Jaeken and Péanne, 2017). However, the newer forms of CDG-II with defects in vesicular trafficking and ion homeostasis are clearly more difficult to elucidate. The discovery of a CDG-II patient with COG7 –deficiency increased the awareness of the impact of abnormal trafficking on glycosylation in humans (Reynders et al., 2011;

Wu et al., 2004). Similarly, the identification of mutations in the V-ATPase complex (ATP6V0A2, ATP6V1E1, and ATP6V1A) and in V-ATPase assembly factors (ATP6AP1, CCDC115 and TMEM199) extended the causes of CDG to intracellular compartmental pH defects (Jansen et al., 2016a, 2016b; Kornak et al., 2008; Van Damme et al., 2017). This is also true for defects in *TMEM165* and *SLC39A8*, two genes that link CDG to deficiency of the trace element manganese (Park et al., 2015; Potelle et al., 2017). These observations suggest that any defect that disturbs the function and organization of the Golgi complex may lead to abnormal glycosylation and thus to CDG. As a result, the number of candidate genes becomes very large. In the majority of cases, glycomics profiling of total serum N-linked glycoproteins does not result in sufficiently specific signatures to directly diagnose the respective CDG-II defects. Since plasma biomarkers are highly relevant and easily accessible for CDG diagnostics and subtyping, future efforts will aim at the development of proteome-wide analysis of glycopeptides to identify protein-specific CDG biomarkers. For example, immunoglobulin glycosylation was shown to be affected in MOGS-CDG, while transferrin remained unaffected (Sadat et al., 2014).

Exome sequencing has greatly facilitated the search for novel genes and is now commonly used in CDG-II diagnostics. On the other hand, disorders like EXT1- and EXT2-CDG, which are not captured by testing for abnormal serum protein glycosylation, indicate that there may be many more monogenic disorders with relevant tissue-specific glycosylation deficiencies. The confirmation of this kind of effect of genetic variants is highly challenging, due to the limited availability of easy read-out systems for visualization and analysis of glycosylation deficiencies in patient material. The advent of bioorthogonal click chemistry with the emergence of metabolic oligosaccharide engineering (MOE) has opened a completely new field of investigation (Ovryn et al., 2017). This extremely powerful strategy allows via a chemical reaction to decipher in living cells a specific metabolic pathway without interfering with it. The available chemical toolbox and the strategies to study glycosylation in normal and pathophysiological conditions are constantly growing. In the field of CDG, the use of two unprotected monosaccharide reporters, namely N-4-pentynoylneuraminic acid (SiaNAI) and N-(4-pentynoyl) mannosamine (ManNAI) has proved to be an effective method to track glycoconjugate sialylation defects (Vanbeselaere et al., 2013; Gilormini et al., 2016). Such labeling strategies, coupled to the use of different azido functionalized fluorescent probes allowed to quantitatively measure the Golgi glycosylation efficiency in CDG patient cells. This assay was successfully applied in COG-, *TMEM165*-, *CCDC115*- and *TMEM199*-CDG patient fibroblasts (Vanbeselaere et al., 2013; Jansen et al., 2016a, 2016b), showing a drastically reduced incorporation of monosaccharide reporters, which was restored upon complementation with wild-type gene. This novel approach will be also facilitate the confirmation of novel CDG-II defects in Golgi homeostasis, as still many Golgi defects are expected to be discovered.

3.2. Beyond genetics: epigenetic studies

Epigenomics or alterations to chromatin (modifications of DNA and histones) can be divided in chromatin marks (individual chemical modifications) and features (multiple linked modifications and more complex elements). Examples of the first are DNA methylations and histone acetylations, and of the latter chromatin interactions, RNA modifications and non-coding RNAs (reviewed in Stricker et al., 2017). A large body of literature documents epigenetic regulation of glycosylation, mostly by showing aberrant glycosylation in cancer. A change in cytosine methylation within the promotor of certain glyco-genes is responsible for the expression of cancer-associated carbohydrate antigens, in gastrointestinal, pancreatic and breast cancer. Other examples of epigenetic regulation of glyco-genes include *FUT7* in leukocytes and the transcription factor HNF1A, a master regulator of plasma protein fucosylation (Zoldoš et al., 2013; Lauc et al., 2014). Treatments of

cultured cells with epigenetic inhibitors reveal that N-glycome profiles drastically change, which indicates that many glycosylation-related genes are regulated by DNA and histone modifications (Saldova et al., 2011). To the best of our knowledge, there are no clear examples of CDG caused by epigenetic changes, probably because we are not looking for such defects. However, we are quite convinced that epigenetic disorders will become an important CDG chapter.

3.3. In search for novel treatments

The functional characterization of phosphomannomutase 2 (PMM2) disease-causing mutations has suggested that PMM2-CDG could be a conformational disease and that therapies addressed to improve the protein folding would be able to ameliorate the clinical symptoms (Yuste-Checa et al., 2015). From a 10,000 compound library screening, 8 possible pharmacological chaperone (PCs) were selected. The compound 1-(3-chlorophenyl)-3-3-bis(pyridine-2-yl)urea stood out, based on its pharmacological properties, the absence of inhibitory effect on PMM enzymatic activity and the improved stability of a number of destabilizing mutant proteins. PMM activity assays were performed with soluble cell extracts from healthy and patient-derived fibroblasts overexpressing wild type PMM2 or PMM2 with the mutations p.Asp65Tyr, p.Pro113Leu, p.Arg162Trp and p.Thr237Met. These results have provided the first proof-of-concept of a possible treatment for PMM2-CDG and identified a promising chemical structure as a starting lead for the development of therapeutic agents against this severe orphan disease (Yuste-Checa et al., 2017). Future clinical trials aim at D-galactose use in different CDG, liposomal mannose-1-phosphate and chaperone therapy in PMM2-CDG (Fig. 2), and possibly PMM enzyme replacement therapy. However, there are major hurdles for enzyme replacement, because it is difficult to target deficiencies in the cytosol, the endoplasmic reticulum or the Golgi compartment. The finding that GDP-mannose levels are tightly controlled by a feedback loop involving GMPPA (Koehler et al., 2013) opens the possibility that PMM2 defects could be treated by pharmacological intervention aimed at suppressing the inhibition exerted by GMPPA on GMPPB, the catalytic subunit of GDP-mannose pyrophosphorylase.

3.4. CDG reference network

MetabERN is a European non-profit network established by the EU to facilitate access to the best available care and to address the needs of all European patients affected by any rare inherited metabolic disease (IMD) and their families. MetabERN already involves 69 specialized metabolic centers from 19 countries and is continuously growing. It aims to promote prevention, accelerate diagnosis and improve standards of care across Europe for patients with an IMD. It is entirely patient- and expert-led. The 7 subnetworks focus on disorder groups, one of which is disorders of glycosylation and intracellular trafficking. This subnetwork aims at initiating natural history studies and therapeutic trials in different CDG.

3.5. eHealth at the service of the patient

Nanotechnology is invading daily life and this should profit the patients. The CDG patient community as well as the researchers involved in CDG would benefit from the development and use of specific apps for the follow-up of patients. Indeed, CDG is characterized by frequent and often severe clinical events throughout the life of the patients. Examples are seizures, bleeding, infections, but also events like hospitalisation, change of drug treatment, frequency of physical therapy sessions, etc. A detailed, online registration would allow the collection of data necessary for the natural history of the different types of CDG. A mobile tool would be especially welcome, given the extreme genetic heterogeneity of CDG, the broad clinical spectrum and variable symptoms, the rarity of most of the types of the disease and the large

geographical distribution of the patients. The different compounds of the app should be developed in collaboration with clinicians and patients' representatives, and the data collected in accordance with national and international laws on medical records and privacy. The app should be useful to inform caretakers of critical events, and allow rapid clinical action if needed (alert function).

4. Conclusion

CDG are a family of, largely not yet treatable, genetic diseases. Like for all patients, it is of utmost importance to provide the best possible care and support to these patients and their families. These include a well-organized, multidisciplinary medical approach and follow-up, optimal paramedical services (physiotherapy, speech therapy, social service a.o.), regularly updated information (via meetings, letters, social media), and practical help e.g. by specific apps. The patients/families, caregivers, and researchers should form a strong community at the service of the patients. The EURO-CDG initiatives are prominent examples of such collaboration and take the lead in this undertaking. We hope that this survey may contribute to this goal.

Acknowledgments

This work was supported by the European Union's Horizon 2020 research and innovation program under the ERA-NET Cofund action N° 643578. BP received funding from the grant PI16/00573 (Fondo de Investigaciones Sanitarias and European Regional Development Fund) and the Fundación Isabel Gemio.

References

- Barone, R., Carrozzi, M., Parini, R., et al., 2015. A nationwide survey of PMM2-CDG in Italy: high frequency of a mild neurological variant associated with the L32R mutation. *J. Neurol.* 262, 154–164.
- Cabezas, O.R., Flanagan, S.E., Stanescu, H., et al., 2017. Polycystic kidney disease with hyperinsulinemic hypoglycemia caused by a promoter mutation in phosphomannomutase 2. *J. Am. Soc. Nephrol.* <http://dx.doi.org/10.1681/ASN.2016121312>.
- de Koning, T.J., 2013. Amino acid synthesis deficiencies. *Handb. Clin. Neurol.* 113, 1775–1783.
- de Lonlay, P., Seta, N., Barrot, S., et al., 2001. A broad spectrum of clinical presentations in congenital disorders of glycosylation I: a series of 26 cases. *J. Med. Genet.* 38, 14–19.
- Dörre, K., Olczak, M., Wada, Y., et al., 2015. A new case of UDP-galactose transporter deficiency (SLC35A2-CDG): molecular basis, clinical phenotype, and therapeutic approach. *J. Inher. Metab. Dis.* 38, 931–940.
- Edvardson, S., Murakami, Y., Nguyen, T.T., et al., 2017. Mutations in the phosphatidylinositol glycan C (PIGC) gene are associated with epilepsy and intellectual disability. *J. Med. Genet.* 54, 196–201.
- Finlayson, S., Palace, J., Belaya, K., et al., 2013. Clinical features of congenital myasthenic syndrome due to mutations in *DPAAT1*. *J. Neurol. Neurosurg. Psychiatry* 84, 1119–1125.
- Gilormini, P.A., Lion, C., Vicogne, D., et al., 2016. A sequential bioorthogonal dual strategy: ManNAI and SiaNAI as distinct tools to unravel sialic acid metabolic pathways. *Chem. Commun. (Camb)* 52, 2318–2321.
- Jaeken, J., Morava, E., 2016. Congenital disorders of glycosylation, dolichol and glycosylphosphatidylinositol metabolism. In: Saudubray, J.-M., Baumgartner, M.R., Walter, J. (Eds.), *Inborn Metabolic Diseases Diagnosis and Treatment*, sixth ed. Springer, Berlin chap 41.
- Jaeken, J., Péanne, R., 2017. What is new in CDG. *J. Inher. Metab. Dis.* <http://dx.doi.org/10.1007/s10545-017-0050-6>.
- Jansen, J.C., Cirak, S., van Scherpenzeel, M., et al., 2016a. CCDC115 deficiency causes a disorder of Golgi homeostasis with abnormal protein glycosylation. *Am. J. Hum. Genet.* 98, 310–321.
- Jansen, E.J., Timal, S., Ryan, M., et al., 2016b. ATP6AP1 deficiency causes an immunodeficiency with hepatopathy, cognitive impairment and abnormal protein glycosylation. *Nat. Commun.* 7, 11600. <http://dx.doi.org/10.1038/ncomms11600>.
- Janssen, M.C., de Kleine, R.H., van den Berg, A.P., et al., 2014. Successful liver transplantation and long-term follow-up in a patient with MPI-CDG. *Pediatrics* 134, e279–e283.
- Kahrizi, K., Hu, C.H., Garshasbi, M., et al., 2011. Next generation sequencing in a family with autosomal recessive Kahrizi syndrome (OMIM 612713) reveals a homozygous frameshift mutation in *SRD5A3*. *Eur. J. Hum. Genet.* 19, 115–117.
- Kapusta, L., Zucker, N., Frenckel, G., et al., 2013. From discrete dilated cardiomyopathy to successful cardiac transplantation in congenital disorders of glycosylation due to dolichol kinase deficiency (DK1-CDG). *Heart Fail. Rev.* 18, 187–196.
- Kara, B., Ayhan, Ö., Gökçay, G., Başboğaoğlu, N., Tolun, A., 2014. Adult phenotype and

- further phenotypic variability in SRD5A3-CDG. *BMC Med. Genet.* 15, 10.
- Koch, J., Mayr, J.A., Alhaddad, B., et al., 2017. CAD mutations and uridine-responsive epileptic encephalopathy. *Brain* 140 (Pt2), 279–286.
- Koehler, K., Malik, M., Mahmood, S., et al., 2013. Mutations in GMPPA cause a glycosylation disorder characterized by intellectual disability and autonomic dysfunction. *Am. J. Hum. Genet.* 93, 727–734.
- Kornak, U., Reynders, E., Dimopoulou, A., et al., 2008. Impaired glycosylation and cutis laxa caused by mutations in the vesicular H⁺-ATPase subunit ATP6V0A2. *Nat. Genet.* 40, 32–34.
- Lamari, F., Mochel, F., Saudubray, J.-M., 2015. An overview of inborn errors of complex lipid biosynthesis and remodelling. *J. Inher. Metab. Dis.* 38, 3–18.
- Lauc, G., Vojta, A., Zoldoš, V., 2014. Epigenetic regulation of glycosylation is the quantum mechanics of biology. *Biochim. Biophys. Acta* 1840, 65–70.
- Matalonga, L., Bravo, M., Serra-Peinado, C., et al., 2017. Mutations in TRAPPC11 are associated with a congenital disorder of glycosylation. *Hum. Mutat.* 38, 148–151.
- Monin, M.-L., Mignot, C., De Lonlay, P., et al., 2014. 29 French adult patients with PMM2-congenital disorder of glycosylation: outcome of the classical pediatric phenotype and depiction of a late-onset phenotype. *Orphanet J. Rare Dis.* 9, 207.
- Morava, E., 2014. Galactose supplementation in phosphoglucomutase-1 deficiency: review and outlook for a novel treatable CDG. *Mol. Genet. Metab.* 112, 275–279.
- Morelle, W., Potelle, S., Witters, P., et al., 2017. Galactose supplementation in TMEM165-CDG patients rescues the glycosylation defects. *J. Clin. Endocrinol. Metab.* <http://dx.doi.org/10.1210/jc.2016-3443>.
- Ovryn, B., Li, J., Hong, S., Wu, P., 2017. Visualizing glycans on single cells and tissues. *Curr. Opin. Chem. Biol.* 39, 39–45.
- Park, J.H., Hogrebe, M., Grüneberg, M., et al., 2015. SLC39A8 deficiency: a disorder of manganese transport and glycosylation. *Am. J. Hum. Genet.* 97, 894–903.
- Péanne, R., Vanbeselaere, J., Vicogne, D., 2013. Assessing ER and Golgi N-glycosylation process using metabolic labeling in mammalian cultured cells. *Methods Cell Biol.* 118, 157–176.
- Potelle, S., Dulary, E., Climer, L., et al., 2017. Manganese-induced turnover of TMEM165. *Biochem. J.* 474, 1481–1493.
- Reynders, E., Foulquier, F., Annaert, W., Matthijs, G., 2011. How Golgi glycosylation meets and needs trafficking: the case of the COG complex. *Glycobiology* 21, 853–863.
- Sadat, M.A., Moir, S., Chun, T.W., et al., 2014. Glycosylation, hypogammaglobulinemia, and resistance to viral infections. *N. Engl. J. Med.* 370, 1615–1625.
- Saldova, R., Dempsey, E., Garay-Perez, M., et al., 2011. 5-AZA-2'-deoxycytidine induced demethylation influences N-glycosylation of secreted glycoproteins in ovarian cancer. *Epigenetics* 6, 1362–1372.
- Sassi, A., Lazaroski, S., Wu, G., et al., 2014. Hypomorphic homozygous mutations in phosphoglucomutase 3 (PGM3) impair immunity and increase serum IgE levels. *J. Allergy Clin. Immunol.* 133, 1410–1419.
- Schollen, E., Kjaergaard, S., Legius, E., Schwartz, M., Matthijs, G., et al., 2000. Lack of Hardy-Weinberg equilibrium for the most prevalent PMM2 mutation in CDG-Ia (congenital disorder of glycosylation type Ia). *Eur. J. Hum. Genet.* 8, 367–371.
- Stray-Pedersen, A., Backe, P.H., Sorte, H.S., et al., 2014. PGM3 mutations cause a congenital disorder of glycosylation with severe immunodeficiency and skeletal dysplasia. *Am. J. Hum. Genet.* 95, 96–107.
- Stricker, S.H., Köferle, A., Beck, S., 2017. From profiles to function in epigenomics. *Nat. Rev. Genet.* 18, 51–66.
- Tegtmeyer, L.C., Rust, S., van Scherpenzeel, M., et al., 2014. Multiple phenotypes in phosphoglucomutase 1 deficiency. *N. Engl. J. Med.* 370, 533–542.
- Thiesler, C.T., Cajic, S., Hoffmann, D., 2016. Glycomic characterization of induced pluripotent stem cells derived from a patient suffering from phosphomannomutase 2 congenital disorder of glycosylation (PMM2-CDG). *Mol. Cell Proteomics* 15, 1435–1452.
- Vals, M.A., Pajusalu, S., Kals, M., Mägi, R., Öunap, K., 2017 Jul 7. The prevalence of PMM2-CDG in Estonia based on population carrier frequencies and diagnosed patients. *JIMD Rep.* <http://dx.doi.org/10.1007/8904.2017.41>. [Epub ahead of print].
- Vanbeselaere, J., Vicogne, D., Matthijs, G., Biot, C., Foulquier, F., Guerardel, Y., 2013. Alkynyl monosaccharide analogues as a tool for evaluating Golgi glycosylation efficiency: application to Congenital Disorders of Glycosylation (CDG). *Chem. Commun. (Camb)* 49, 11293–11295.
- Van Damme, T., Gardeitchik, T., Mohamed, M., et al., 2017. Mutations in ATP6V1E1 or ATP6V1A cause autosomal-recessive cutis laxa. *Am. J. Hum. Genet.* 100, 216–227.
- Wheeler, P.G., Ng, B.G., Sanford, L., et al., 2016. SRD5A3-CDG: expanding the phenotype of a congenital disorder of glycosylation with emphasis on adult onset features. *Am. J. Med. Genet. A* 170, 3165–3171.
- Wild, M.K., Lühn, K., Marquardt, T., Vestweber, D., 2002. Leukocyte adhesion deficiency II: therapy and genetic defect. *Cells Tissues Organs* 172, 161–173.
- Willems, A.P., Gundogdu, M., Kempers, M.E.J., et al., 2017. Mutations in N-acetylglucosamine (O-GlcNAc) transferase in patients with X-linked intellectual disability. *J. Biol. Chem.* <http://dx.doi.org/10.1074/jbc.M117.790097>.
- Wong, S.Y., Gadomski, T., van Scherpenzeel, M., et al., 2017. Oral D-galactose supplementation in PGM1-CDG. *Genet. Med.* <http://dx.doi.org/10.1038/gim.2017.41>.
- Wu, X., Steet, R.A., Bohorov, O., et al., 2004. Mutation of the COG complex subunit gene COG7 causes a lethal congenital disorder. *Nat. Med.* 10, 518–523.
- Yuste-Checa, P., Gámez, A., Brasil, S., et al., 2015. The effects of PMM2-CDG-causing mutations on the folding, activity, and stability of the PMM2 protein. *Hum. Mut.* 36, 851–860.
- Yuste-Checa, P., Brasil, S., Gámez, A., et al., 2017. Pharmacological chaperoning: a potential treatment for PMM2-CDG. *Hum. Mut.* 38, 160–168.
- Zhang, Y., Yu, X., Ichikawa, M., et al., 2014. Autosomal recessive phosphoglucomutase 3 (PGM3) mutations link glycosylation defects to atopy, immune deficiency, autoimmunity, and neurocognitive impairment. *J. Allergy Clin. Immunol.* 133, 1400–1409.
- Zoldoš, V., Novokmet, M., Bečcheli, I., 2013. Genomics and epigenomics of the human glycome. *Glycoconj. J.* 30, 41–50.