



**HAL**  
open science

## Dental discoloration following Le Fort 1 osteotomy, a systematic review

Nolwenn Piot, Matthias Schlund, Joel Ferri

### ► To cite this version:

Nolwenn Piot, Matthias Schlund, Joel Ferri. Dental discoloration following Le Fort 1 osteotomy, a systematic review. *Journal of Stomatology, Oral and Maxillofacial Surgery*, 2021, *Journal of Stomatology, Oral and Maxillofacial Surgery*, 10.1016/j.jormas.2021.05.005 . hal-04007956

**HAL Id: hal-04007956**

**<https://hal.univ-lille.fr/hal-04007956>**

Submitted on 22 Jul 2024

**HAL** is a multi-disciplinary open access archive for the deposit and dissemination of scientific research documents, whether they are published or not. The documents may come from teaching and research institutions in France or abroad, or from public or private research centers.

L'archive ouverte pluridisciplinaire **HAL**, est destinée au dépôt et à la diffusion de documents scientifiques de niveau recherche, publiés ou non, émanant des établissements d'enseignement et de recherche français ou étrangers, des laboratoires publics ou privés.



Distributed under a Creative Commons Attribution - NonCommercial 4.0 International License

## **Dental discoloration following Le Fort 1 osteotomy, a systematic review**

Nolwenn Piot, Matthias Schlund, Joël Ferri

Nolwenn Piot, Resident

-Univ. Lille, CHU Lille, Service de Chirurgie Maxillo-Faciale et Stomatologie, F-59000 Lille, France

Matthias Schlund, MD, MSc, Chief Resident

-Univ. Lille, CHU Lille, INSERM, Service de Chirurgie Maxillo-Faciale et Stomatologie, U1008 - Controlled Drug Delivery Systems and Biomaterials, F-59000 Lille, France

Joël Ferri, MD, PhD, Professor, Department Head

-Univ. Lille, CHU Lille, INSERM, Service de Chirurgie Maxillo-Faciale et Stomatologie, U1008 - Controlled Drug Delivery Systems and Biomaterials, F-59000 Lille, France

- AIMOM, F-59650, Villeneuve d'Ascq, France

Corresponding author :

Nolwenn Piot

Service de Chirurgie Maxillo-Faciale et Stomatologie

Hôpital Roger Salengro – CHU Lille

Rue Emile Laine

59037 Lille Cedex

France

Tel : +33320443676

Fax : +33320445860

e-mail : nolwenn.piot@hotmail.fr

## **Dental discoloration following Le Fort 1 osteotomy, a systematic review**

### **Abstract**

**Introduction:** This study was conducted to review current knowledge concerning factor and how to proceed with dental discoloration after Le Fort 1 osteotomy (LF1O).

**Material & Methods:** A systematic search of the literature was performed in PubMed/Medline and Cochrane library until December 1, 2020 using the following key words: “dental discoloration and osteotomy”, “dental discoloration and Le Fort”, “dental discoloration and orthognathic”, “dental discoloration and surgery”, “tooth discoloration and osteotomy”, “tooth discoloration and Le Fort”, “tooth discoloration and orthognathic”, “tooth discoloration and surgery”.

**Results:** 705 studies were located by initial screening; 232 were duplicate, 468 did not meet the eligibility criteria, leaving 5 studies. The post-operative follow-up period of the included studies ranged from 6 months to 2 years.

**Conclusion:** The present revue found dental discoloration can occur after LF1O in 3.56% of the cases. The follow-up before treatment should be around one years. If the discoloration persisted and pulpal sensibility test is negative, the tooth should be treated. If the pulpal sensibility test is positive, follow-up should be carry on.

**Keywords:** Le Fort 1 osteotomy; orthognathic surgery; maxillary osteotomy; dental discoloration; pulpal blood flow.

## **Introduction**

Le Fort 1 osteotomy (LF1O) was first performed to correct a dentofacial deformity in 1921 by Herman Wassmund. [1] Since then, the technique has been refined. [2] It became a routine procedure associated with orthodontic treatment in the treatment of dentofacial deformity. Its functional and esthetic benefits are well known, an improvement in physical and psychosocial quality of life with high rates of patient satisfaction has been described. [3–5] LF1O is considered a safe procedure, however, complications may occur similarly as with any type of surgical procedure. Infra-orbital nerve injuries, intra and post-operative hemorrhage, infection, fixation material failure, postoperative malocclusion, temporomandibular joint disorder, cranial base fractures, amaurosis, lachrymal duct lesion, hearing impairment, unsatisfactory esthetic result, especially nasal structure, oroantral fistula, osteonecrosis, facial palsy, maxillary non-union, relapse have been described [6–13]. Dental complications may also occur such as injury to the dental apex when performing the osteotomy leading to pulp necrosis and dental discoloration. This is a technical complication and its care is straightforward: endodontic treatment is necessary. However, dental discoloration may happen following LF1O even when there is no direct lesion to dental roots. [14–18] This is a rarely described event following LF1O, which can be very distressing for the patient and the surgeon. Indeed, pulp necrosis is a poor outcome in a surgery aimed at improving oral function and dentofacial esthetic. The physiopathology of this discoloration is currently not well known. [19–21]

The aim of this study was to systematically review the incidence and the outcome of dental discoloration following LF1O.

## **Materials and Methods**

This systematic review was performed in accordance with the preferred reporting items for systematic reviews and meta-analyses (PRISMA) guidelines. The following databases were searched: MEDLINE and Cochrane library. The terms used in the searches of each database were “dental discoloration and osteotomy”, “dental discoloration and Le Fort”, “dental discoloration and orthognathic”, “dental discoloration and surgery”, “tooth discoloration and osteotomy”, “tooth discoloration and Le Fort”, “tooth discoloration and orthognathic”, “tooth discoloration and surgery”. Searches were performed until December 1, 2020.

Studies were eligible if dental discoloration following LF1O was assessed. Exclusion criteria were: case reports, language other than English, and unavailability of the full text. Studies were first screened using their title and abstract. The full report was then reviewed and included if no exclusion criteria were met. Incidence and outcome were assessed.

## **Results**

The initial search yielded 705 results. 232 were duplicate, leaving 473 studies. 468 were not eligible since dental discoloration following LF1O was not assessed. Five full reports were reviewed, no exclusion criteria was met. Finally, 5 studies were included and analyzed (Figure 1).

The results are shown in Tables 1 and 2. Five studies were retrospective and 1 were prospective. A total of 2631 patients were included in this review, 2178 of whom underwent LF1O. LF1O was associated to a mandibular osteotomy in 1736 cases. LF1O was segmented in 522 cases. 67 discolored teeth were found. Hence, dental discoloration happened following 3.02% of LF1O performed. Some patients exhibited two dental discolorations, but since two studies did not mention this data [17,18] the total number of patient presenting with dental discoloration cannot be calculated. Final assessment of the tooth was performed at 6 months in 1 study, [16] after 1 year in 1 study, [18] and after 2 years in 1 study. [15] This data was not mentioned in 2 studies. [16,22] Primary objective of the included studies were focused on dental discoloration following orthognathic surgery, [15] complications following orthognathic surgery, [16,22] tooth vitality after LF1O, [18] or pulpal blood flow after LF1O. [16]

Lee et al. [15] performed root canal treatment with dental bleaching in every case of tooth discoloration while Robl et al. [17] stated that many teeth recovered without treatment without giving a numbered account. The final outcome of the discolored teeth was not disclosed in the other studies. Mesgarzadeh et al. [18] found no significant relationship between pulp vitality and tooth discoloration.

## Discussion

Dental complications following orthognathic surgery are less frequent than nerve injury, hemorrhage or infection with an incidence described at 2.8%. [6] However, 3.56% of dental discoloration following LF1O were found reviewing the literature. Dental discoloration was not related to the distance between the root apex and the screws. [15] The physiopathology of this complication is not well understood as Mesgarzadeh et al. found 5.3% of discolored anterior teeth while 3.2% of these teeth were necrotic and required endodontic treatment. [18] No statistically significant relationship was found between pulp vitality and discoloration. Furthermore, Robl et al. state that many teeth recover without treatment, return to normal coloration, and respond to pulp testing. [17] On the other hand, Lee et al. found that every teeth showing a remarkable discoloration had a necrotic pulp when endodontic treatment was performed. [15] Pulpal vascularization may be the key to understand dental discoloration following LF1O. Indeed, LF1O is responsible for a disruption in maxillary vascularization. Some tissues may be more sensitive to this disruption and suffer some degree of ischemia. Several studies focused on pulpal blood flow (PBF) showed a significant postoperative decrease of PBF during 1 to 10 days comparatively to preoperative PBF. [23–27] The study with the longest follow-up (up to 29 months) showed that PBF returned to normal. [24] It is speculated that this decreased PBF values could be a postoperative effect of the osteotomy and that with time the blood flow may return to baseline values. [24] Maxillary PBF was even shown to decrease when an isolated mandibular osteotomy was performed. [23] A “stealing of dental pulp perfusion pressure” by the mandibular segment was suggested. Maxillo-mandibular osteotomies would therefore be more at risk of dental discoloration. However, this review could not conclude on this subject as there were either only LF1O without mandibular osteotomy [18,22] or LF1O systematically associated with a mandibular osteotomy, [15] or insufficient data. [16,17]

The link with vascular disruption is stressed if the role of the descending palatal artery (DPA) ligation is considered, even if DPA ligation does not compromise maxillary vascularization after LF1O. [28] Indeed, dental discoloration was significantly more frequent in patients who had DPA ligation during the LF1O. [15] Furthermore, in a case of unilateral DPA ligation, Ramsay et al. described a dental discoloration ipsilateral to the ligated DPA, whereas PBF was not altered on the contralateral side. [16] Contrarily, Dodson et al. did not find a significant difference in PBF between patients who underwent DPA ligation versus those with DPA preserved. [28] It was also shown that the extent of the maxillary displacement was not associated with an increased risk of dental discoloration, [15] however, massive displacement may strain the DPA and reduce blood supply. [29,30]

On another hand, PBF and clinical findings can be discordant. Central incisor was the tooth most frequently affected in several studies, [14–16,22] whereas canine and premolar had greatest variability in recovery of pulpal response in PBF studies. It was explained by the proximity of these teeth to the vertical interdental osteotomy on segmental osteotomies as well as the closeness of their root apices to the horizontal osteotomy line [23,24,31,32] The rate of dental discoloration is indeed more elevated in the study of Williams et al., which includes only surgically assisted rapid palatal expansion with 5% versus the 3.56% of the global review. [22] This is in favor of lesions linked to the segmentation. Similarly, one study found that every dental discoloration occurred in the mandible when the mandibular osteotomy was associated with a genioplasty. [15] However, segmental LF1O are considered a safe technique in other studies. [33] Furthermore, maxillary anterior multi-segmental osteotomy was not significantly correlated with dental discoloration in the Lee et al. study. [15]



While no definite physiopathological explanation can yet be defined, every study confirms that time is the cornerstone of dental discoloration following LF1O care. Indeed, vitality testing cannot provide reliable results for several months. The rate of teeth with positive pulpal sensibility test gradually increase postoperatively: 0% at 2 weeks, [27] 3-17% at 2 months , [27,34] 50% at 3 months, [27] 70-90% at 6 months [27,34] 96% at 12 months. [27] This suggests the root canal treatment should not be systematic or precocious after LF1O. It seems reasonable to follow-up patients with dental discoloration following LF1O at least for 12 months. At 12 months, pulpal vitality should be assessed. If the pulpal sensibility test is negative, the tooth should be treated endodontically and bleached. If the pulpal sensibility test is positive, follow-up should be considered (Figure 2).

### **Conclusion**

Dental discoloration can occur after LF1O in 3.56% of the cases without technical mistake. Careful follow-up is necessary as long-term suppressed response to vitality testing may occur without signifying that an endodontic treatment is necessary.

**Funding:** None

**Conflict of Interest:** None

## References

- [1] Wassmund, Frakturen and Luxationen des Gesichtsschädels. Meusser, Leipzig, 1927
- [2] Bell RB. A History of Orthognathic Surgery in North America. *J Oral Maxillofac Surg* 2018;76:2466–81. <https://doi.org/10.1016/j.joms.2018.09.006>.
- [3] Zamboni R, de Moura FRR, Brew MC, Rivaldo EG, Braz MA, Grossmann E, et al. Impacts of Orthognathic Surgery on Patient Satisfaction, Overall Quality of Life, and Oral Health-Related Quality of Life: A Systematic Literature Review. *Int J Dent* 2019;2019:2864216. <https://doi.org/10.1155/2019/2864216>.
- [4] Promerat A, Touzet-Roumazeille S, Schlund M, Ferri J. Assessing Quality of Life After Orthognathic Surgery in Disabled Patients. *J Craniofac Surg* 2019;30:2404–7. <https://doi.org/10.1097/SCS.0000000000005698>.
- [5] Ghorbani F, Gheibollahi H, Tavanafar S, Eftekharian HR. Improvement of Esthetic, Functional, and Social Well-Being After Orthognathic Surgical Intervention: A Sampling of Postsurgical Patients Over a 10-Year Period From 2007 to 2017. *J Oral Maxillofac Surg* 2018;76:2398–403. <https://doi.org/10.1016/j.joms.2018.04.034>.
- [6] Jędrzejewski M, Smektała T, Sporniak-Tutak K, Olszewski R. Preoperative, intraoperative, and postoperative complications in orthognathic surgery: a systematic review. *Clin Oral Investig* 2015;19:969–77. <https://doi.org/10.1007/s00784-015-1452-1>.
- [7] Ferri J, Druelle C, Schlund M, Bricout N, Nicot R. Complications in orthognathic surgery: A retrospective study of 5025 cases. *Int Orthod* 2019;17:789–98. <https://doi.org/10.1016/j.ortho.2019.08.016>.
- [8] Ettinger KS, Nathan J, Guerrero LM, Salinas TJ, Arce K. Microvascular Reconstruction of Total Maxillary Avascular Necrosis as a Complication of Routine Orthognathic Surgery. *J Oral Maxillofac Surg* 2020;78:1846–58. <https://doi.org/10.1016/j.joms.2020.06.009>.
- [9] Maquet C, Evrard M, Kerbrat J-B, Bastien A-V, Adnot J, Trost O. A case of severe facial palsy following bimaxillary osteotomy: It is time to update the pre-surgery patient fact sheet. *J Stomatol Oral Maxillofac Surg* 2020;121:323–4. <https://doi.org/10.1016/j.jormas.2019.08.013>.
- [10] Kurohara K, Tomomatsu N, Nakakuki K, Sakuma T, Arai N, Yoda T. Treatment of refractory non-union after maxillary osteotomy: A case report. *J Stomatol Oral Maxillofac Surg* 2019;120:493–6. <https://doi.org/10.1016/j.jormas.2018.11.017>.
- [11] Suzen M, Develi T, Uckan S. Prevalence of postoperative secondary bleeding and its relationship with intraoperative massive bleeding in patients undergoing orthognathic surgery. *J Stomatol Oral Maxillofac Surg* 2021;122:29–32. <https://doi.org/10.1016/j.jormas.2020.05.002>.
- [12] Marion F, Mercier JM, Odri G-A, Perrin JP, Longis J, Kün-Darbois J-D, et al. Associated relaps factors in Le Fort I osteotomy. A retrospective study of 54 cases. *J Stomatol Oral Maxillofac Surg* 2019;120:419–27. <https://doi.org/10.1016/j.jormas.2018.11.020>.
- [13] Ben Rejeb M, Souissi Med A, Bertin H, Perrin J-P, Longis J, Zairi I, et al. Nasal structure changes after inferior maxillary repositioning: A retrospective study of 20 cases. *J Stomatol Oral Maxillofac Surg* 2019;120:332–6. <https://doi.org/10.1016/j.jormas.2019.02.008>.
- [14] Buckley JG, Jones ML, Hill M, Sugar AW. An Evaluation of the Changes in Maxillary Pulpal Blood Flow Associated with Orthognathic Surgery. *Br J Orthod* 1999;26:39–45. <https://doi.org/10.1093/ortho/26.1.39>.
- [15] Lee U-L, Lee E-J, Seo H-Y, Han S-H, Choi W-C, Choi Y-J. Prevalence and risk factors of tooth discolouration after orthognathic surgery: a retrospective study of 1455 patients. *Int J Oral Maxillofac Surg* 2016;45:1464–70. <https://doi.org/10.1016/j.ijom.2016.05.018>.

- [16] Ramsay DS, Artun J, Bloomquist D. Orthognathic surgery and pulpal blood flow: a pilot study using laser Doppler flowmetry. *J Oral Maxillofac Surg* 1991;49:564–70. [https://doi.org/10.1016/0278-2391\(91\)90336-k](https://doi.org/10.1016/0278-2391(91)90336-k).
- [17] Robl MT, Farrell BB, Tucker MR. Complications in Orthognathic Surgery. *Oral Maxillofac Surg Clin N Am* 2014;26:599–609. <https://doi.org/10.1016/j.coms.2014.08.008>.
- [18] Mesgarzadeh A, Motamedi MH, Akhavan H, Tousi TS, Mehrvarzfar P, Eshkevari PS. Effects of Le Fort I osteotomy on maxillary anterior teeth: a 5-year follow up of 42 cases. *Eplasty*. 2010 Jan 8;10:e10. PMID: 20090842; PMCID: PMC2806794.
- [19] Justus T, Chang BL, Bloomquist D, Ramsay DS. Human gingival and pulpal blood flow during healing after Le Fort I osteotomy. *J Oral Maxillofac Surg* 2001;59:2–7. <https://doi.org/10.1053/joms.2001.19251>.
- [20] Kim S. Neurovascular interactions in the dental pulp in health and inflammation. *J Endod* 1990;16:48–53. [https://doi.org/10.1016/S0099-2399\(06\)81563-3](https://doi.org/10.1016/S0099-2399(06)81563-3).
- [21] Nanda R, Legan HL, Langeland K. Pulpal and radicular response to maxillary osteotomy in monkeys. *Oral Surg Oral Med Oral Pathol* 1982;53:624–36. [https://doi.org/10.1016/0030-4220\(82\)90353-x](https://doi.org/10.1016/0030-4220(82)90353-x).
- [22] Williams BJD, Currimbhoy S, Silva A, O’Ryan FS. Complications following surgically assisted rapid palatal expansion: a retrospective cohort study. *J Oral Maxillofac Surg* 2012;70:2394–402. <https://doi.org/10.1016/j.joms.2011.09.050>.
- [23] Eroglu SE, Sabuncuoglu FA. Changes in dental pulp blood flow of different maxillary tooth types after Le Fort I osteotomy. *J Craniofac Surg* 2014;25:e420-424. <https://doi.org/10.1097/SCS.0000000000000920>.
- [24] Aanderud-Larsen K, Brodin P, Aars H, Skjelbred P. Laser doppler flowmetry in the assessment of tooth vitality after Le Fort I osteotomy. *J Cranio-Maxillofac Surg* 1995;23:391–5. [https://doi.org/10.1016/S1010-5182\(05\)80136-2](https://doi.org/10.1016/S1010-5182(05)80136-2).
- [25] Harada K, Sato M, Omura K. Blood-flow and neurosensory changes in the maxillary dental pulp after differing Le Fort I osteotomies. *Oral Surg Oral Med Oral Pathol Oral Radiol Endod* 2004;97:12–7. <https://doi.org/10.1016/j.tripleo.2003.08.028>.
- [26] Harada K, Sato M, Omura K. Blood-flow change and recovery of sensibility in the maxillary dental pulp during and after maxillary distraction: a pilot study. *Oral Surg Oral Med Oral Pathol Oral Radiol Endod* 2004;98:528–32. <https://doi.org/10.1016/j.tripleo.2004.02.079>.
- [27] Sato M, Harada K, Okada Y, Omura K. Blood-flow change and recovery of sensibility in the maxillary dental pulp after a single-segment Le Fort I osteotomy. *Oral Surg Oral Med Oral Pathol Oral Radiol Endodontology* 2003;95:660–4. <https://doi.org/10.1067/moe.2003.241>.
- [28] Dodson TB, Bays RA, Neuenschwander MC. Maxillary perfusion during Le Fort I osteotomy after ligation of the descending palatine artery. *J Oral Maxillofac Surg* 1997;55:51–5. [https://doi.org/10.1016/S0278-2391\(97\)90446-8](https://doi.org/10.1016/S0278-2391(97)90446-8).
- [29] Lazaridis K, Lazaridou M, Athanasiou AE. Pulpal and Periodontal Tissues Changes Associated with Le Fort I and Sagittal Split Ramus Osteotomies: A review. *Open Dent J* 2018;12:24–31. <https://doi.org/10.2174/1874210601812010024>.
- [30] Lanigan DT. Ligation of the descending palatine artery: pro and con. *J Oral Maxillofac Surg* 1997;55:1502–4. [https://doi.org/10.1016/s0278-2391\(97\)90676-5](https://doi.org/10.1016/s0278-2391(97)90676-5).
- [31] Vedtofte P. Pulp canal obliteration after Le Fort I osteotomy. *Dent Traumatol* 1989;5:274–8. <https://doi.org/10.1111/j.1600-9657.1989.tb00373.x>.
- [32] Ranna V, Kellesarian SV, Feng C, Javed F, Ghanem A. Influence of the orthognathic surgical procedure Le Fort I osteotomy on the vascularity and neurosensory response of

the dental pulp: A systematic review. *Quintessence Int.* 2016;47(8):677-86. [https://doi:10.3290/j.qi.a36386](https://doi.org/10.3290/j.qi.a36386)

- [33] Haas Junior OL, Guijarro-Martínez R, de Sousa Gil AP, da Silva Meirelles L, de Oliveira RB, Hernández-Alfaro F. Stability and surgical complications in segmental Le Fort I osteotomy: a systematic review. *Int J Oral Maxillofac Surg* 2017;46:1071–87. <https://doi.org/10.1016/j.ijom.2017.05.011>.
- [34] Kahnberg KE, Engström H. Recovery of maxillary sinus and tooth sensibility after le Fort I osteotomy. *Br J Oral Maxillofac Surg.* 1987 Feb;25(1):68-73. [https://doi:10.1016/0266-4356\(87\)90159-8](https://doi.org/10.1016/0266-4356(87)90159-8)

## **List of Tables and Figures**

Table 1: Included studies and outcomes

Table 2: Included studies and results

Figure 1: Flowchart of the systematic review following PRISMA guidelines

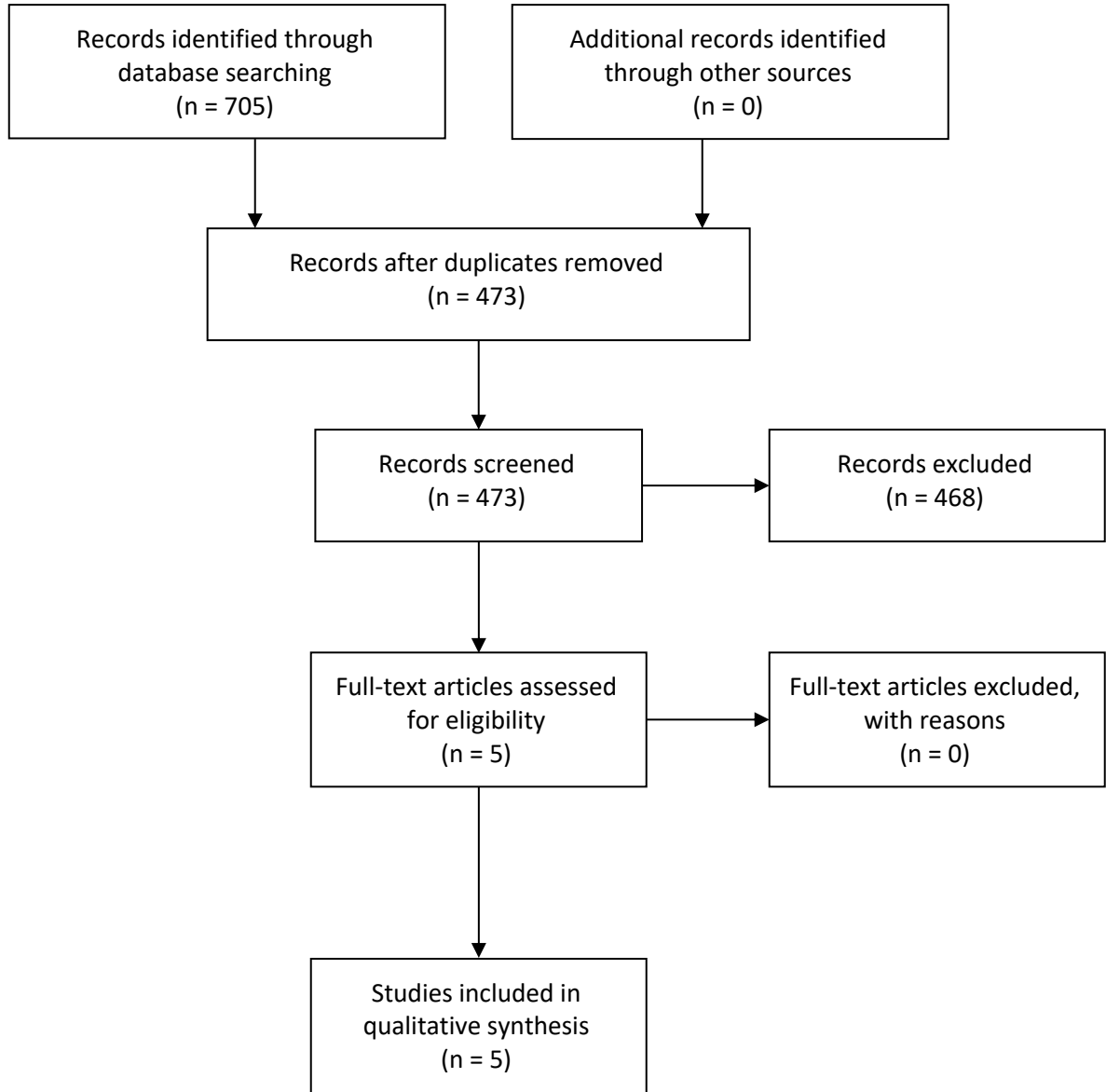
Figure 2: Guidelines proposal

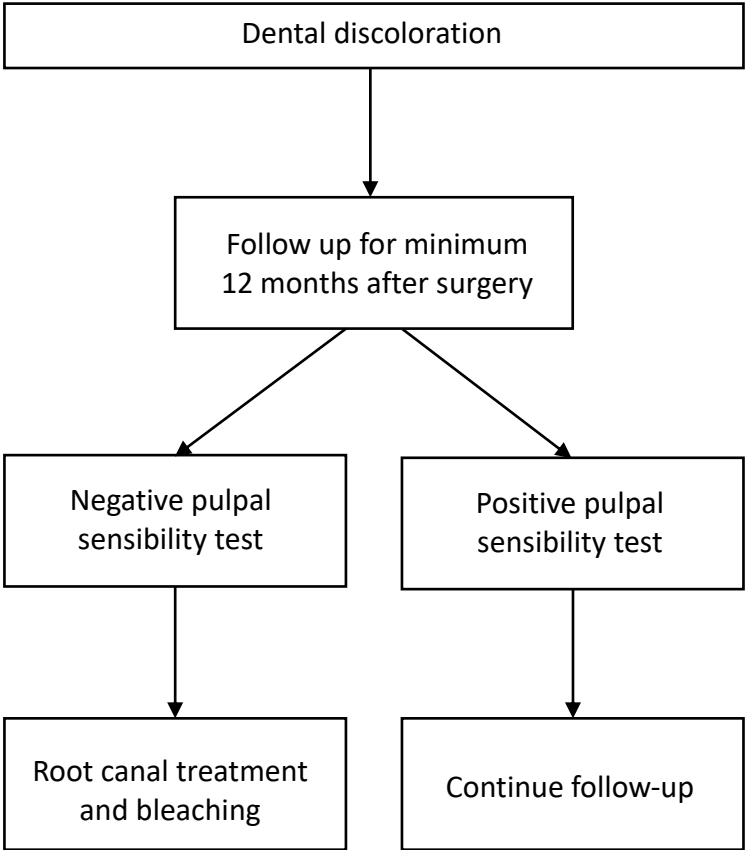
Identification

Screening

Eligibility

Included





Investigator	Patients included	Le Fort 1 (segmented)	mandibular osteotomy associated at LF10	Discolored teeth	Patients with discoloration	Last follow-up visit
Lee et al., 2016	1455	1339 (60)	1339	48	49	2 years
Robl et al., 2014	1000	663 (342)	389	Unknown	Unknown	Unknown
Williams et al., 2012	120	120 (120)		5	5	Unknown
Mesgarzadeh et al., 2010	42	42		13	Unknown	1-5 years
Ramsay et al., 1991	14	14	12	1	1	6 months
	Total = 2631	Total = 2178 (522)	Total = 1736	Total = 67		



Investigator	Study design	Primary Objective	Outcome
Lee et al., 2016	Retrospective	prevalence and risk factors of tooth discolouration assessment	RCT + tooth bleaching in every case
Robl et al., 2014	Retrospective	orthognathic surgery complications reviewing	RCT in 4 cases, many teeth recover without treatment
Williams et al., 2012	Retrospective	SARPE complications assessment	Unknown
Mesgarzadeh et al., 2010	Retrospective	vitality status of anterior teeth after LF1 assessment	No relationship between pulp vitality and tooth discoloration
Ramsay et al., 1991	Prospective	effect of LF1 on pulpal blood flow	Unknown