



**HAL**  
open science

## Free flap for lower limb salvage in infectious purpura fulminans

Justine Boucher, E. Guerre, Veronique Duquennoy- Martinot, Pierre Guerreschi, L. Pasquesoone

► **To cite this version:**

Justine Boucher, E. Guerre, Veronique Duquennoy- Martinot, Pierre Guerreschi, L. Pasquesoone. Free flap for lower limb salvage in infectious purpura fulminans. *Annales de Chirurgie Plastique Esthétique*, 2021, *Annales de Chirurgie Plastique Esthétique*, 10.1016/j.anplas.2021.10.001 . hal-04007965

**HAL Id: hal-04007965**

**<https://hal.univ-lille.fr/hal-04007965v1>**

Submitted on 5 Jan 2024

**HAL** is a multi-disciplinary open access archive for the deposit and dissemination of scientific research documents, whether they are published or not. The documents may come from teaching and research institutions in France or abroad, or from public or private research centers.

L'archive ouverte pluridisciplinaire **HAL**, est destinée au dépôt et à la diffusion de documents scientifiques de niveau recherche, publiés ou non, émanant des établissements d'enseignement et de recherche français ou étrangers, des laboratoires publics ou privés.



Distributed under a Creative Commons Attribution - NonCommercial 4.0 International License

## **Free Flap for Lower Limb Salvage in Infectious Purpura Fulminans**

### **Lambeau Libre pour Sauvetage de Membre Inférieur dans le Purpura**

### **Fulminans infectieux**

J. Boucher <sup>a</sup>, E. Guerre <sup>b</sup>, V. Duquennoy-Martinot <sup>a</sup>, P. Guerreschi <sup>a</sup>, L. Pasquesoone <sup>a</sup>

a. Justine Boucher, M.D., Véronique Duquennoy-Martinot, M.D., Ph.D., Pierre Guerreschi, M.D., Ph.D., Louise Pasquesoone, M.D., Department of Plastic and Reconstructive Surgery and Burn Care Unit, Lille University Hospital, France

b. Elvire Guerre, M.D., Department of Orthopaedic Surgery n°1, Lille University Hospital, France

#### **Corresponding author:**

Justine Boucher

Service de Chirurgie Plastique

CHU Lille

59000 Lille, France

Tel. +33646333350

Fax +3320445425

boucher.justine@live.fr

## **INTRODUCTION**

Purpura fulminans is a serious disease with high mortality, from 20 to 50% according to the studies, and also high morbidity. About 25% of purpura fulminans survivors require amputation of at least one limb, sometimes of all 4, more or less proximally [1, 2]. The diffuse soft tissue lesions of purpura fulminans lead to complex situations. Necrosis may develop at a joint or proximal bones, whereas the distal limb survives. Free flaps are increasingly used to cover important exposed structures and to preserve maximum limb length [3–5]. But does preserving the length of a limb already affected by purpura fulminans, at the cost of major surgery, improve limb function and the patient's quality of life?

We aimed to evaluate preservation of lower limb length and limitation of the level of amputation achieved using free flaps in patients with infectious purpura fulminans by secondarily evaluating walking ability, limb function and the patients' quality of life.

## **PATIENTS AND METHODS**

### **Patient Inclusion**

This single-center, observational, descriptive retrospective study was conducted from 2016 to 2019. The patients included were adults aged over 18 years, survivors of purpura fulminans (defined as extensive necrotic lesions with septic shock and disseminated intravascular coagulation) [6, 7], who received a free flap for lower limb salvage. There were no exclusion criteria.

### **Data Collection**

Retrospective data collected for each patient were age, sex, history, occupation, regular sports practice and leisure activities, microbiological results, hyperbaric oxygen therapy

sessions and duration of intensive care. Data collected on surgical management were number of limbs involved, fasciotomies, surgical debridements, amputation level, performance of a free flap with preoperative angiography, time between onset of purpura fulminans and surgery, site, flap type, flap donor site, pedicles used, type of microsurgical anastomosis, intraoperative platelet level, preoperative antiplatelet therapy, intraoperative anticoagulant flush, and time to healing. Free flap surgery was performed by the same orthoplastic team (plastic surgeon and orthopedic surgeon) referred to here as the “reference surgeon” [8]. Data collected on rehabilitation were duration of rehabilitation and time to walking.

### **Later Post-Surgical Evaluation**

Later post-surgical evaluation was based on data obtained during a follow-up consultation in 2019 by one of the surgeons of the orthoplastic team. Secondary surgery, independence, discharge home, resumption of sports and leisure activities, car driving, professional activity, walking ability and walking distance were recorded.

In each limb with a free flap, we assessed sensation, function and aesthetic appearance on a numerical scale 0 (minimum) to 10 (maximum). The aesthetic appearance of the flap donor sites was assessed on a scale from 0 to 5. These assessments were made by the patient, the reference surgeon and an independent surgeon.

Quality of life was assessed with the generic SF-36 questionnaire which the patients completed during the follow-up visit [9]. The questionnaire examines 9 dimensions, and several dimensions can be grouped to calculate the physical component score (PCS) and mental component score (MCS). Each dimension, the PCS and the MCS are scored between 0 (minimum) and 100 (maximum).

### **Statistical Analysis**

Quantitative variables were described as means and standard deviations or as medians and interquartile intervals (Q1–Q3). Qualitative variables were described as frequencies and percentages. Normal distribution was verified using the Shapiro-Wilk test. Variables with non-normal distribution were compared using Wilcoxon's test. All tests were two-tailed and  $p < 0.05$  was considered significant. The SF-36 sub-dimensions were expressed as raw values from 0 to 100. The PCS and MCS scores were calculated as recommended. Descriptive statistics were performed with Excel® software (Microsoft Corp., USA) and Wilcoxon's test with R statistical software on the BiostaTGV website.

### **Ethical Approval**

Study was declared to the French data protection authority CNIL. Patients received written information on the study and gave their informed oral consent.

## **RESULTS**

From 2016 to 2019, 6 patients were included, 2 men and 4 women of mean age  $38 \pm 13$  years. Two patients had a medical history, one of asthma, nasal polyps and polymyomatous uterus, and the other of tobacco-related COPD and multiple dental infections. All patients had a professional occupation and leisure activities. Five patients undertook regular physical activity. The bacteria identified were *Neisseria meningitidis* (1 case), group A beta-hemolytic *Streptococcus* (3), *Klebsiella pneumoniae* (1) and *Escherichia coli* (1), and initial clinical presentations are shown in Table 1. Five of the 6 patients received hyperbaric oxygen therapy sessions. Mean duration of stay in intensive care was  $84.8 \pm 15.3$  days.

### **Surgical Management**

Five of the 6 patients had more or less extensive involvement of all 4 limbs and in one patient 3 limbs were involved. Two patients underwent fasciotomies of the lower limbs. Each involved limb underwent 1 to 4 surgical debridements. All patients required amputation of at least one limb. Amputations were performed at a mean of  $37.4 \pm 16.6$  days after the onset of purpura fulminans. Amputation levels are shown in Table 2. Vascular permeability was monitored in all patients by preoperative angiography. Nine free flaps were performed in the 6 patients: a single flap in 3 patients and a double flap in 3 patients during the same surgical procedure. The free flaps were used to cover a loss of substance exposing important structures in 7 cases and for stump coverage in 2 cases. The 9 free flaps were performed a mean of  $74 \pm 13$  days after the onset of purpura fulminans. All 9 flaps were successful and there was no flap failure. The microsurgical arterial anastomoses were all performed at a distance from the area of interest and 89% were end-to-end anastomoses. The venous anastomoses were all carried out end-to-end using a Coupler™ (Synovis Micro Companies Alliance, Birmingham, AL, USA). In one patient, we attempted to restore sensation in the free flap placed on the heel by end-to-side anastomosis of a sensory nerve branch of the flap to the posterior tibial nerve. Table 3 shows the donor sites, recipient sites and types of anastomosis of the free flaps. At the time of surgery, mean platelet level was  $350,666 \pm 111,662/\text{mm}^3$ . All patients received pre- and postoperative antiplatelet treatment with acetylsalicylic acid (Kardegic®), 75 mg/day. All patients received an intraoperative systemic heparin flush, 0.5 mg/kg, during microsurgical anastomosis. Healing was obtained at a mean of  $71 \pm 30$  days after the free flap procedure (Fig. 1). The use of free flaps made it possible to preserve greater limb length. In all patients, the level of amputation avoided was much more proximal than the effective amputation level (Table 4).

## **Rehabilitation**

Mean duration of stay in a rehabilitation unit was  $183 \pm 100$  days (range, 51 to 341 days). Five patients were recovered walking with an appropriate prosthesis at a mean of  $117 \pm 112$  days after discharge from intensive care. In patient 3, despite optimal rehabilitation, chronic flap sores and musculoskeletal stump deformities never allowed weightbearing and bilateral transtibial amputation was finally performed. With suitable prostheses and rehabilitation, this patient recovered walking 20 months after purpura fulminans and 16 weeks after bilateral transtibial amputation.

### **Later Post-Surgical Evaluation**

Post-surgical evaluation of purpura fulminans was conducted at a mean of  $30 \pm 9.3$  months.

### ***Secondary Surgical Management***

Patients were regularly seen by the reference surgeons and secondary surgical procedures were proposed, which were accepted by 5 patients. These procedures aimed to improve the scars of purpura fulminans or flap donor sites (4 patients underwent scar lipofilling or flap defatting), or to manage ulceration of the limb with a flap (5 patients) by means such as free flap coverage with palliative surgery by tendon transfer, secondary bilateral transtibial amputation, management of chronic osteitis, surgical shortening of the stump bone, and lipofilling and skin graft on the flap. These procedures resolved the problem in 2 of the 5 patients while 3 still experienced disability.

### ***General Evaluation of the Patients***

All patients were independent for the activities of daily living (dressing, eating, hygiene). Overall post-surgical evaluation is presented in Table 5.

### ***Evaluation of the Limb with Free Flap***

Five of the 8 free flaps were in a weightbearing area and all were insensate despite the attempt to provide sensation. Three free flaps had ulcerations.

Patients scored function of the limb with flap an average of 6.4/10, whereas the reference and independent surgeons gave a score of 8.3/10 (Table 6). The aesthetic appearance of the limb with flap was scored a mean of 1.4/5 by patients and 3.7/5 by the surgeons (Table 6).

### ***Donor Site Evaluation***

The aesthetic appearance of the flap was scored on average 3.1/5 by patients, 4.3/5 by the reference surgeon and 4.5/5 by the independent surgeon, a statistically significant difference between patients and surgeons (Table 6).

### ***Quality of Life and SF-36 Score***

The SF-36 scores (means  $\pm$  standard deviations) and medians (Q1–Q3) of all 6 patients are shown in Table 7.

## **DISCUSSION**

### **Surgical Management**

#### ***Limitation of Amputation Level***

The value of free flap limb salvage is evidenced when its use allows more distal amputation. More distal amputation also reduces the functional consequences for the patient. The first publications on free flap limb salvage date from 1994, when Herrera et al. performed a free temporoparietal flap for ankle coverage in a child, saving his foot [3]. Some series of 1 or 2 free flaps were later described. The cases were fairly similar, using free flaps to cover exposed knee joints and avoid transfemoral amputation. Then MacLennan et al. in 2000 and Duteille et al. in 2005 performed free flap limb salvage in series of 5 and 4 patients, respectively [4, 5]. In our study, the free flaps performed in the 6 patients initially lowered the level of amputation. Nevertheless, in one patient functional complications made it impossible to preserve limb length and she underwent secondary bilateral transtibial amputation. Some amputation levels are not functional [10, 11]. As toe or long transmetatarsal amputations have a slight effect on walking, a way must be found to limit amputations at this level. In short transmetatarsal or



Lisfranc amputations, the foot develops a paradoxical varus attitude [11]. If the insensate free flap lies in a weightbearing area, there is a risk of chronic ulcerations. This type of amputation must be discussed on an individual basis with the teams and the patient. In midtarsal amputation, the stump is too short to be functional and develops equinus [11]. Midtarsal amputation was attempted in one of our patients but he was unable to resume walking. This type of amputation is thus not advisable and transtibial amputation should be preferred [11]. Transtibial amputation should also be preferred if the knee is mobile, as a free flap avoids transfemoral amputation. A decision tree for preservation of lower limb length and limitation of amputation level in infectious purpura fulminans is proposed in Fig. 2.

### ***Coverage with a Free Flap***

Our study includes 6 patients with 9 free flaps and is the largest study on free flap limb salvage in purpura fulminans survivors. There are only 2 published series: MacLennan et al. in 2000 [4] and Duteille et al. in 2005 [5]. Duteille et al. performed 6 free flaps in 4 patients of mean age 19 years [5]. MacLennan et al. performed 7 free flaps in 5 patients of age range 3.5–35 years [4]. Free flaps were performed at a mean of 74 days, when platelet levels were in the normal range. MacLennan et al. performed their flaps at around 1 month, with platelet levels from 300,000 to 900,000/mm<sup>3</sup> [4]. In purpura fulminans, disseminated intravascular coagulation causes thrombocytopenia followed by reactive thrombocytosis [12]. MacLennan et al. experienced one flap loss in a patient whose platelet level was 728,000/mm<sup>3</sup> [4]. Flap thrombosis is the most frequent cause of free flap loss. Thrombocytosis is a potential risk factor for flap thrombosis, although the causal relationship is not scientifically proven [13, 14]. Time to surgery and platelet levels must be therefore be considered. In our study, free flap surgery was not performed in the same procedure as excision of necrotic tissue. Viability of remaining tissue could thus be assessed before the coverage procedure. Duteille et al. performed all free flaps during the same procedure as excision [5]. This carries the risk of incomplete debridement.

Our patients received perioperative antiplatelet therapy, as did those of MacLennan et al. and Duteille et al. [4, 5]. Our patients also received systemic heparin anticoagulation when microsurgical anastomosis was performed, although the recent study of Couteau et al. did not demonstrate that this improved flap survival [15].

This is the first series of perforating free flaps performed in patients with purpura fulminans. Perforating flaps are increasingly used as they reduce donor site sequelae. A free anterolateral thigh flap was recently described in 2017 for reconstruction of necrotic upper and lower lips after purpura fulminans [16]. MacLennan et al. and Duteille et al. used the latissimus dorsi flap, which is larger in area [4, 5]. The choice of donor site depends on the area to be covered, donor site sequelae and a donor area free of purpuric lesions. The recipient sites are various because the lesions themselves are heterogeneous, as observed by other authors [4, 5]. Nearly all arterial anastomoses were end-to-end. Preoperative angiography is therefore indispensable to monitor vascular permeability. MacLennan et al. and Duteille et al. recommend end-to-side anastomosis to avoid sacrificing an arterial axis and distal worsening of ischemia [4, 5]. We observed no worsening in our study. Like other authors, we carried out end-to-end venous anastomosis, but using a venous coupler. This device has proven its efficacy and safety and decreases operating time [17, 18]. The thrombosis rate does not significantly differ between venous anastomoses performed by suture or with the coupler [19, 20]. Like Duteille et al., we had no free flap failure and no technical problem [5]. In addition, we performed anastomoses at a distance from the affected areas requiring coverage, and so quality vessels were available. Lastly, our patients were young without vascular risk factors. In view of these convincing results [5, 21–23], the need for microsurgery should not be a drawback in the surgical strategy of purpura fulminans.

### **Later Post-Surgical Evaluation**

Five of 6 patients presented with complications and surgery was required in 4 cases. Ulcerations were located in areas of weightbearing or friction when walking and sometimes on the free flaps which are insensate. Patients must be informed of the risks and complications (hyperkeratosis, chronic ulceration) when the free flap lies in a weightbearing area. Donor site sequelae were acceptable, since only 2 patients requested revision surgery for cosmetic improvement. The aesthetic scores given by the surgeons were good and concordant, whereas patient scores were lower. The scars were objectively of good quality, but for the patient this is a new scar in an area previously intact. Five of the 6 patients were able to walk without technical aids. The patient with secondary bilateral transtibial amputation was resuming walking during our evaluation. The patients of MacLennan et al. and Duteille et al. were able to walk at their evaluations at 60 and 25 months, respectively [4, 5]. Our patients were independent, lived at home and some had resumed work, but follow-up was relatively short. Patients scored the function of their salvaged limb at 6.4/10, which is encouraging although we used a simple numerical non-validated scale. No study, however, has used a validated scale for lower limb function in patients after purpura fulminans. Lastly, quality of life was relatively good, since the dimension scores were around 50/100 except for limitations related to physical health where the score was lower. However, there appeared to be no link between amputation level and quality of life. In fact, a patient with proximal amputations has a better quality of life than a patient with distal amputations. Very few studies have addressed quality of life after purpura fulminans. Contou et al. in 2019 evaluated 12 amputees and found similar quality of life scores to those of our patients [24]. Lastly, the scores in the general population are higher than in our study patients [9]. However, we did not carry out statistical analysis to seek significant differences between these 3 groups.

## **CONCLUSION**

Purpura fulminans is a serious disease with high mortality and morbidity. The free flap is now a technically validated procedure for bone and joint coverage and preserving limb length in purpura fulminans survivors. However, this technique is not appropriate for all patients and is dependent on the patient's general condition and amputation level. Patients are satisfied with this procedure which restores independence and walking ability. Their quality of life is relatively good despite complications and secondary surgery.

**Conflict of Interest:** None

### REFERENCES

1. Contou D, Sonnevile R, Canoui-Poitrine F, Colin G, Coudroy R, Pène F et al. Clinical spectrum and short-term outcome of adult patients with purpura fulminans: a French multicenter retrospective cohort study. *Intensive Care Med.* 2018;44:1502-1511.
2. Klifto KM, Gurno CF, Grzelak MJ, Seal SM, Asif M, Hultman CS et al. Surgical outcomes in adults with purpura fulminans: A systematic review and patient-level meta-synthesis. *Burns Trauma.* 2019;7:30.
3. Herrera R, Hobar PC, Ginsburg CM. Surgical intervention for the complications of meningococcal-induced purpura fulminans. *Pediatr Infect Dis J.* 1994;13:734-737.
4. MacLennan SE, Kitzmiller WJ, Yakuboff KP. Free-tissue transfer for limb salvage in Purpura fulminans. *Plast Reconstr Surg.* 2001;107:1437-1442.
5. Duteille F, Thibault F, Perrot P, Renard B, Pannier M. Salvaging limbs in cases of severe purpura fulminans: Advantages of free flaps. *Plast Reconstr Surg.* 2006;118:681-685.
6. Perera TB, Murphy-Lavoie HM. Purpura Fulminans. In: StatPearls [Internet]. Treasure Island (FL): StatPearls Publishing; 2019. Available at: <http://www.ncbi.nlm.nih.gov/books/NBK532865/>. Accessed Sept. August 15, 2020.
7. Chu DZ, Blaisdell FW. Purpura fulminans. *Am J Surg.* 1982;143:356-362.

8. Pasquesoone L, Barry L, Sturbois-Nachef N, Duquennoy-Martinot V, Chantelot C, Guerre E. The interest of “ortho-plastic” collaboration in management of complex limb injury. *Ann Chir Plast Esthet.* 2020 Nov;65(5-6):423-446.
9. Lepage A, Ecosse E, Pouchot J, Coste J, Perneger T. Le questionnaire MOS SF-36 : Manuel de l'utilisateur et guide d'interprétation des scores. Paris: Editions Estem; 2001.
10. Camilleri A, Anract P, Missenard G, Larivière JY et Ménager D. Amputations et désarticulations des membres. Membre inférieur. *Encycl Méd Chir (Editions Scientifiques et Médicales Elsevier SAS, Paris, tous droits réservés), Techniques chirurgicales - Orthopédie-Traumatologie*, 44-109, 2000, 27 p.
11. Menager D. Amputations du membre inférieur et appareillage. *EMC - Appar Locomoteur* 2006;1:1□15.
12. Koch C, Taeger C, Geis S, Lonic D, Heigekrueger P, Dolderer J et al. Early fasciotomies and plastic-surgical reconstruction may enhance preservation of functional extremity length in purpura fulminans. *Clin Hemorheol Microcirc.* 2020;75(3):267□278.
13. Kuo YR, Yang KD, Yang MY, Lo Huang MN, Lin CW, Lin FC et al. Reactive thrombocytosis alone does not affect the patency of microvascular anastomosis in the splenectomy rat. *Plast Reconstr Surg.* 2002;110:812□817.
14. Kuo YR, Yang KD, Huang MNL, Wei FC, Jeng SF. Reactive thrombocytosis without endothelial damage does not affect the microvascular anastomotic patency. *Ann Plast Surg.* 2003;50:57□63.
15. Couteau C, Rem K, Guillier D, Moris V, Revol M, Cristofari S. Improving free-flap survival using intra-operative heparin: Ritualistic practice or evidence-base medicine? A systematic review. *Ann Chir Plast Esthet.* 2018;63:e1□5.
16. Kuwahara M, Yurugi S, Yamanaka Y, Sasaki C, Nakanishi T. Reconstruction of near-total loss of the upper and lower lips due to purpura fulminans with local tissue and a dual-

- skin paddled anterolateral thigh flap. *Plast Reconstr Surg Glob Open* 2017;5:e1505.
17. Nakayama K, Tamiya T, Yamamoto K, Akimoto S. A simple new apparatus for small vessel anastomosis (free autograft of the sigmoid included). *Surgery* 1962;52:918-931. Print.
  18. Jandali S, Wu LC, Vega SJ, Kovach SJ, Serletti JM. 1000 Consecutive venous anastomoses using the microvascular anastomotic coupler in breast reconstruction. *Plast Reconstr Surg*. 2010;125:792-798.
  19. Yap LH, Constantinides J, Butler CE. Venous thrombosis in coupled versus sutured microvascular anastomoses. *Ann Plast Surg*. 2006;57:666-669.
  20. Rozen WM, Whitaker IS, Acosta R. Venous coupler for free-flap anastomosis: Outcomes of 1,000 cases. *Anticancer Res*. 2010;30:1293-1294.
  21. Redett RJ, Bury TF, McClinton MA. The use of simultaneous free latissimus dorsi tissue transfers for reconstruction of bilateral upper extremities in a case of purpura fulminans. *J Hand Surg*. 2000;25:559-564.
  22. Jester A, Waag KL, Germann G, Bickert B. Sequential microsurgical flap reconstruction following purpura fulminans during infancy and childhood. *J Reconstr Microsurg*. 2002;18:17-22.
  23. Herrera F, Lee C, Kryger G, Roostaeian J, Safa B, Lohman RF et al. Microsurgery in the hypercoagulable patient: Review of the literature. *J Reconstr Microsurg*. 2012;28:305-312.
  24. Contou D, Canoui-Poitaine F, Coudroy R, Préau S, Cour M, Barbier F et al. Long-term quality of life in adult patients surviving purpura fulminans: An exposed-unexposed multicenter cohort study. *Clin Infect Dis*. 2019;69:332-340.

## TABLES

**Table 1. Age, Germ and Initial Clinical Presentation in All Patients**

<b>Patients</b>	<b>Age</b>	<b>Germ</b>	<b>Initial clinical presentation</b>
<b>1</b>	30	Neisseria Meningitidis (Serogroup C)	Meningococemia
<b>2</b>	28	Group A beta-hemolytic Streptococcus	Influenza complicated by bacterial pneumonia
<b>3</b>	51	Klebsiella Pneumoniae	Acute pyelonephritis
<b>4</b>	52	Group A beta-hemolytic Streptococcus	Appendicular peritonitis
<b>5</b>	47	Escherichia Coli	Pneumonia
<b>6</b>	21	Group A beta-hemolytic Streptococcus	Influenza complicated by bacterial pneumonia

**Table 2. Levels of Limb Amputation in Patients after Infectious Purpura Fulminans**

Patients	Upper limb amputation level	Lower limb amputation level
1	Bilateral digital	Left transtibial
2	Right forearm Left transmetacarpal	Bilateral transtibial
3	Bilateral finger pulp	Bilateral midtarsal
4	Bilateral digital	Bilateral toes
5	Left digital	Right transtibial Left transmetatarsal
6	Left finger pulp	Right transtibial Left transmetatarsal



**Table 3. Free Flaps, Donor and Recipient Sites in All Patients**

<b>Patients</b>	<b>Recipient Site</b>	<b>Amputation Level of Limb Receiving the Free Flap</b>	<b>Type of Flap</b>	<b>Receiving Artery</b>	
<b>1</b>	Single free flap	Right heel and ankle	No amputation	Chimeric flap: fasciocutaneous thoracodorsal + serratus anterior flap	Posterior tibial
<b>2</b>	Double free flap	Right patella	Transtibial	Serratus anterior muscle flap	Anterior tibial
		Left patella	Transtibial	Serratus anterior muscle flap	Anterior tibial
<b>3</b>	Double free flap	Right stump	Midtarsal	Serratus anterior muscle flap	Anterior tibial
		Left stump	Midtarsal	Serratus anterior muscle flap	Anterior tibial
<b>4</b>	Double free flap	Right heel	Toes	Anterolateral thigh perforator flap	Posterior tibial
		Left heel	Toes	Serratus anterior muscle flap	Posterior tibial
<b>5</b>	Single free flap	Left heel	Transmetatarsal	Anterolateral thigh perforator flap	Posterior tibial
<b>6</b>	Single free flap	Left heel	Transmetatarsal	Anterolateral thigh perforator flap	Posterior tibial

**Table 4. Effective Amputation Level for Each Patient Compared with Amputation Level Avoided by Use of a Free Flap**

<b>Patients</b>		<b>Effective Amputation Level</b>	<b>Amputation Level Avoided</b>
1	Right lower limb	0	Transtibial
2	Right lower limb	Transtibial	Transfemoral
2	Left lower limb	Transtibial	Transfemoral
3	Right lower limb	Midtarsal	Transtibial
3	Left lower limb	Midtarsal	Transtibial
4	Right lower limb	Toes	Transtibial
4	Left lower limb	Toes	Transtibial
5	Left lower limb	Transmetatarsal	Transtibial
6	Left lower limb	Transmetatarsal	Transtibial

**Table 5. Post-Surgical Evaluation of Independence, Activities and Pain in Patients after Purpura Fulminans**

	<b>Number of patients</b>	<b>Percentage</b>
	<b>(n = 6)</b>	<b>(%)</b>
<b>Independent</b>	<b>6</b>	<b>100</b>
<b>Professional activity</b>	<b>2</b>	<b>33</b>
Adaptation of work environment	1	17
<b>Discharge home</b>	<b>6</b>	<b>100</b>
Time from onset of purpura fulminans (mean ± standard deviation)	240 ± 177 days	
Help in the home	1	17
<b>Leisure activities</b>	<b>6</b>	<b>83</b>
<b>Sports activities</b>	<b>3</b>	<b>50</b>
<b>Driving</b>	<b>4</b>	<b>67</b>
Specially adapted car	3	50
<b>Walking ability</b>	<b>6</b>	<b>83</b>
Walking distance < 500 m	1	17
Walking distance > 500 m	5	83
<b>Technical assistance</b>	<b>1</b>	<b>17</b>
<b>Chronic pain</b>	<b>2</b>	<b>33</b>
Daily analgesics	1	17

**Table 6. Comparison of Functional and Aesthetic Scores Evaluated by Patients, Reference Surgeon and Independent Surgeon**

	<b>Patient Evaluation (A)</b>	<b>Evaluation by Reference Surgeon (B)</b>	<b>Evaluation by Independent Surgeon (C)</b>	<b>A vs B <i>p</i></b>	<b>B vs C <i>p</i></b>	<b>A vs C <i>p</i></b>
Functional evaluation score of limbs with free flap ( <i>n</i> = 7)	6.4 ± 3.1	8.3 ± 1.5	8.3 ± 0.8	0.276	1	0.167
Aesthetic evaluation score of limbs with free flap ( <i>n</i> = 7)	1.4 ± 1.8	3.7 ± 1.7	3.7 ± 1.1	0.091	1	0.072
Aesthetic evaluation score of donor sites ( <i>n</i> = 10)	3.1 ± 1.4	4.3 ± 0.7	4.5 ± 0.7	0.020*	0.345	0.020*

Scores are given as means ± standard deviations

\* = *p* < 0.05.

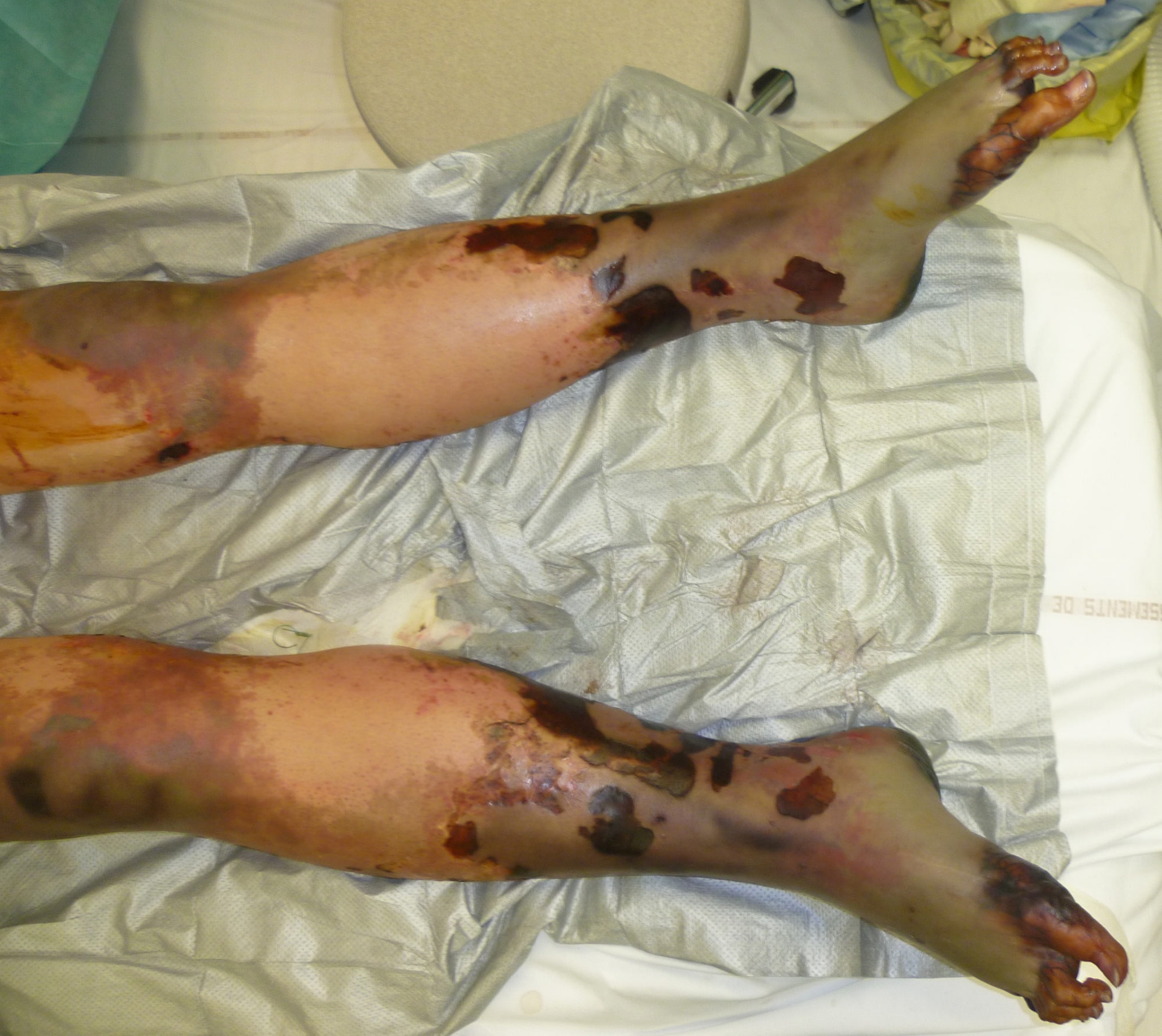**Table 7. SF-36 Dimension Scores, Physical Component Scores and Mental Component Scores in the 6 Patients**

<b>Patients</b>	<b>1</b>	<b>2</b>	<b>3</b>	<b>4</b>	<b>5</b>	<b>6</b>	<b>Mean (± SD)</b>	<b>Median (Q1–Q3)</b>
<b>Dimensions</b>								
Physical functioning	85	75	30	12	55	50	<b>51 (± 27.2)</b>	<b>52.5 (35–70)</b>
Role limitations due to physical health	25	100	0	0	50	25	<b>33 (± 37.6)</b>	<b>25 (6.2–43.7)</b>
Physical pain	100	61	52	12	52	100	<b>63 (± 33.4)</b>	<b>56.5 (52–90.2)</b>
Perceived health	82	37	52	0	57	67	<b>49 (± 28.4)</b>	<b>54.5 (40.7–64.5)</b>
Vitality	55	75	70	5	50	55	<b>52 (± 24.8)</b>	<b>55 (51.2–66.2)</b>
Social functioning	100	87	62.5	12.5	62.5	50	<b>62 (± 30.5)</b>	<b>62.5 (53.1–90.9)</b>
Emotional wellbeing	88	76	80	16	52	76	<b>65 (± 26.7)</b>	<b>76 (58–79)</b>
Role limitations due to emotional functioning	100	100	0	0	33.3	33.3	<b>44 (± 45.5)</b>	<b>33.3 (8.3–83.3)</b>
Health change	75	75	100	50	50	75	<b>71 (± 18.8)</b>	<b>75 (56.2–75)</b>
<b>Physical component summary (PCS)</b>	<b>45.9</b>	<b>42.8</b>	<b>30.1</b>	<b>22.0</b>	<b>41.7</b>	<b>43.1</b>	<b>37.6 (± 9.4)</b>	<b>42.3 (33–43)</b>
<b>Mental component score (MCS)</b>	<b>58.2</b>	<b>55.9</b>	<b>48.8</b>	<b>22.0</b>	<b>39.0</b>	<b>43.8</b>	<b>44.6 (± 13.2)</b>	<b>46.3 (40.1–54.1)</b>

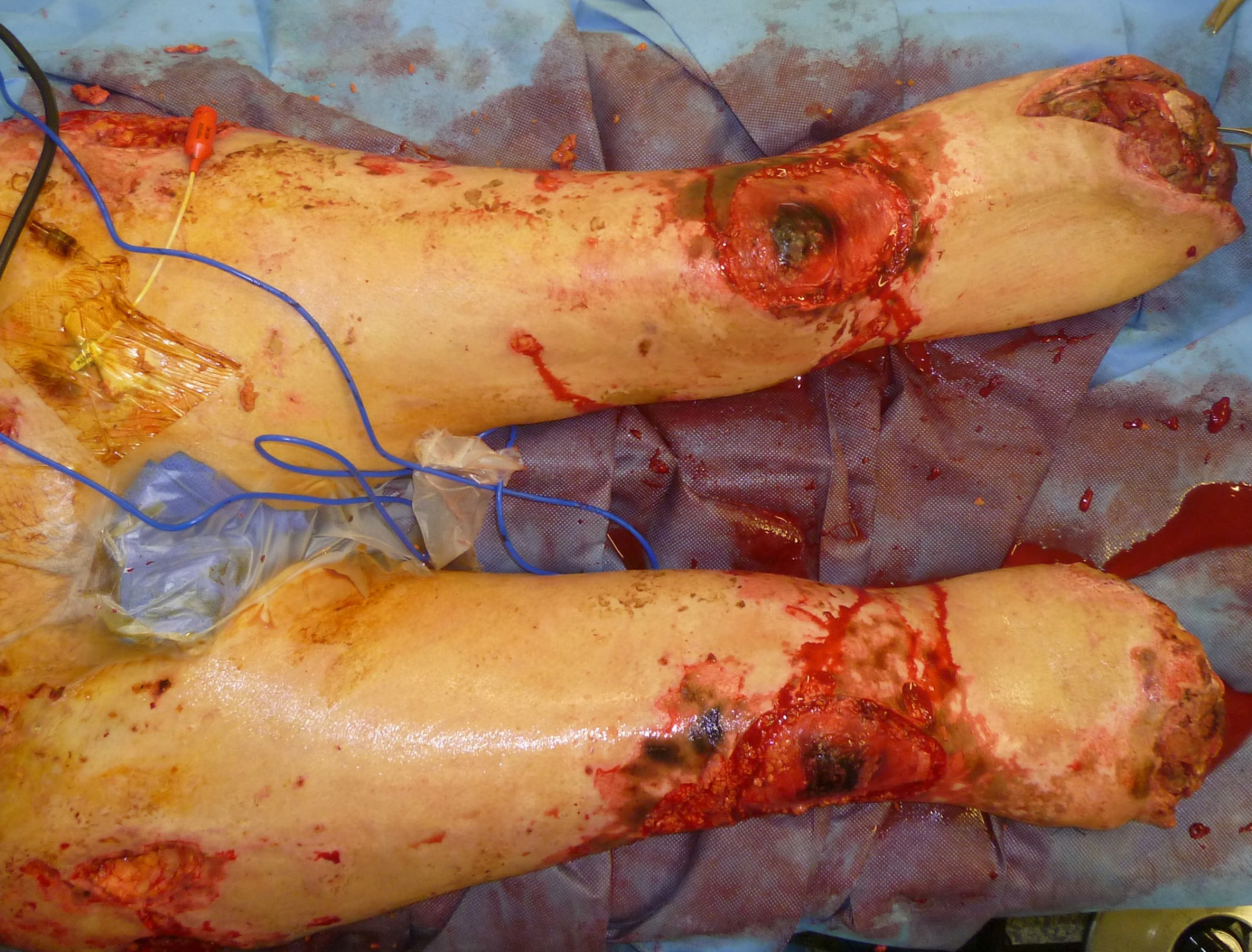
SF-36: score 0 = minimum to 100 = maximum, means (± standard deviations, SD) and medians (1<sup>st</sup> quartile–3<sup>rd</sup> quartile, Q1–Q3)

**Figure 1.** Surgical procedure, patient 2. A. Extensive necrosis of the feet and anterior knees. B. After serial debridements and bilateral transtibial amputation. C. Double free serratus anterior muscle flap for patella coverage, immediate postoperative view. D. Successful healing.

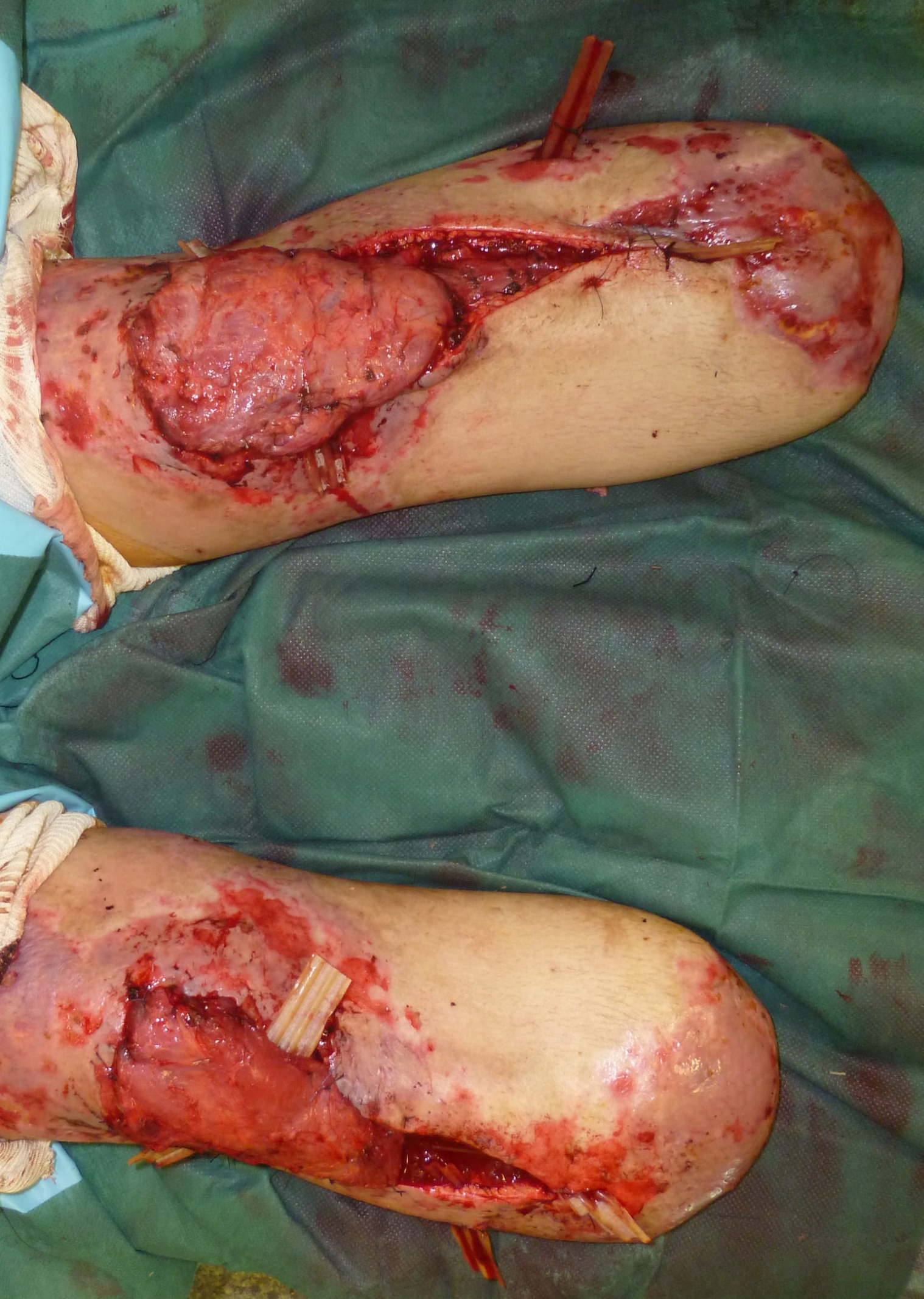




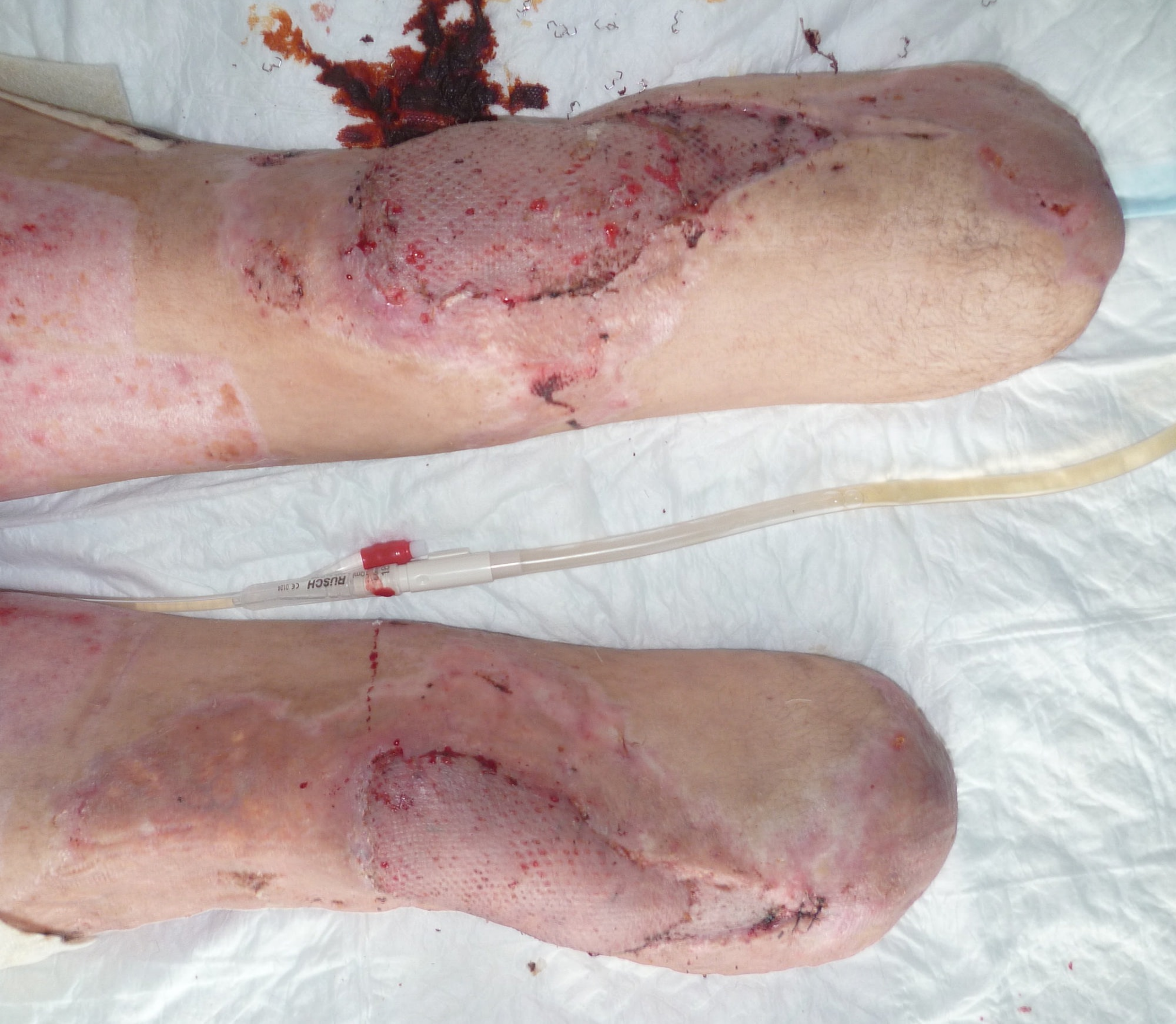










**Figure 2.** Decision tree for preservation of lower limb length and limitation of amputation level in patients with infectious purpura fulminans.

