



HAL
open science

Management of sinus graft infection-a systematic review

Matthias Schlund, J. Meeus, C. Politis, Joel Ferri

► To cite this version:

Matthias Schlund, J. Meeus, C. Politis, Joel Ferri. Management of sinus graft infection-a systematic review. *International Journal of Oral and Maxillofacial Surgery*, 2021, *International Journal of Oral and Maxillofacial Surgery*, 10.1016/j.ijom.2021.09.007 . hal-04009140

HAL Id: hal-04009140

<https://hal.univ-lille.fr/hal-04009140>

Submitted on 22 Jul 2024

HAL is a multi-disciplinary open access archive for the deposit and dissemination of scientific research documents, whether they are published or not. The documents may come from teaching and research institutions in France or abroad, or from public or private research centers.

L'archive ouverte pluridisciplinaire **HAL**, est destinée au dépôt et à la diffusion de documents scientifiques de niveau recherche, publiés ou non, émanant des établissements d'enseignement et de recherche français ou étrangers, des laboratoires publics ou privés.



Distributed under a Creative Commons Attribution - NonCommercial 4.0 International License

Matthias Schlund¹, Jan Meeus², Constantinus Politis², Joël Ferri¹

¹Université de Lille, CHU Lille, INSERM, Service de Chirurgie Maxillo-Faciale et Stomatologie, U1008 – Controlled Drug Delivery Systems and Biomaterial, Lille, France

²OMFS IMPATH Research Group, Department of Imaging and Pathology, Faculty of Medicine, KU Leuven and Department of Oral and Maxillofacial Surgery, University Hospitals Leuven, Leuven, Belgium

Abstract

Sinus graft infections are rare but serious complications, as they are associated with significant morbidity and sinus graft loss. The aim of this study was to systematically review the management of sinus graft infection in order to define which protocols should be implemented. The terms searched in each database were “sinus graft infection management”, “maxillary sinus lift infection”, “maxillary sinus graft infection”, “maxillary sinus elevation infection”, and “maxillary sinus augmentation infection”. The management of the sinus graft infection was assessed. The outcomes evaluated were maxillary sinus health and dental implantation results. The initial search yielded 1190 results. Eighteen articles were included, reporting a total of 3319 patients and 217 sinus graft infections. Drainage was performed with an intraoral approach in 13 studies, an endoscopic approach in two studies, and a combined approach in three studies. In every study, a disease-free sinus was finally obtained in

all patients, but the outcomes of the graft and the dental implant were more varied. It is not possible to define the best treatment protocol for sinus graft infections based on the published data, since the level of evidence is poor. Management is very heterogeneous. This review highlights the necessity of surgical treatment associated with antibiotic therapy.

Keywords: sinus floor augmentation, maxillary sinusitis, surgical wound infection, preprosthetic oral surgical procedure, maxillo-mandibular reconstruction

Introduction

A minimal bone height is the prerequisite for dental implant (DI) placement. In the maxilla, due to the proximity of the maxillary sinus, this prerequisite must frequently be addressed using a procedure called sinus augmentation (or sinus lift or sinus elevation). Brånemark placed his first breakthrough model of DI in humans in 1965¹. Ten years later, in 1974, Tatum performed the first sinus floor augmentation procedure², while the first scientific publication was authored by Boyne and James in 1980³. Sinus augmentation rapidly became a routine procedure, with a high success rate⁴. Alternatives have since been developed, such as angulated implant placement⁵, zygomatic implants⁶, and short implants⁷. However, sinus augmentation remains a mainstay of maxillary dental rehabilitation.

Several modifications of the initial technique described by Tatum have been published, and two approaches are currently in use: lateral antrostomy and transalveolar⁸. A wide array of materials are currently used to perform the sinus

augmentation: bone autograft of intraoral or extraoral origin, bone allograft, bone xenograft, and alloplast calcium phosphate ceramic⁹. Potential complications include intraoperative bleeding, Schneiderian membrane perforation, mucous retention cyst, loss of graft material, migration of the implant, sinus graft infection, and sinusitis¹⁰. Schneiderian perforation is the most frequent complication, which if appropriately handled does not seem to affect DI survival¹¹. Sinus graft infection and sinusitis mostly occur together and are rarely reported individually in the literature¹². These are rare but more serious complications, as they are associated with significant morbidity and sinus graft loss. Moreover, they impair patient quality of life and jeopardize the dental rehabilitation process.

DI placement and sinus augmentation procedures are standardized routine procedures. On the other hand, the management of sinus graft infection has not been standardized and there are various treatment protocols; for instance, although antibiotic therapy is routinely performed, the antibiotics used differ greatly [Au?2]. Furthermore, antibiotic therapy alone is mostly insufficient to treat these patients. The infected material should be treated surgically. Surgical care depends on the experience of the team, available resources, and sensibility [Au?3]. Indeed, patients may be referred to an oral surgeon or an otorhinolaryngologist, or a team including both specialists, who may not share the same point of view, or have the same objective: a disease-free sinus and/or dental rehabilitation.

The aim of this study was to systematically review the management of sinus graft infection in order to define which protocols should be implemented.

Materials and methods

This systematic review was performed according to the Preferred Reporting Items for Systematic Reviews and Meta-Analyses (PRISMA) guidelines¹³. The MEDLINE, Cochrane Library, and clinicaltrials.gov databases were searched. The terms searched in each database were “sinus graft infection management”, “maxillary sinus lift infection”, “maxillary sinus graft infection”, “maxillary sinus elevation infection”, and “maxillary sinus augmentation infection”. There were no limits in the search, which was performed up to December 12, 2020. Studies were eligible if the management of sinus graft infection was assessed. The exclusion criteria were as follows: data mixed with other causes of sinusitis, case reports, technical notes, overviews, consensus statements, publication language other than English, and unavailability of the full text.

The studies were first screened by title and abstract. The full report was then reviewed. Studies were included if none of the exclusion criteria were met. The management of sinus graft infection was assessed. The outcomes evaluated were maxillary sinus health and dental implantation results (possibility of DI placement or DI survival) when the data were available.

Results

The initial search yielded 1190 results (Fig. 1). After the removal of duplicates ($n = 447$), 743 items were screened by title and abstract [Au?2]. Fifty-five publications were eligible based on their title and abstract, of which 37 were excluded: 26 case reports, two technical notes, three overviews, one consensus statement, one article in Russian, one article in Chinese, two unavailable full texts, and one article reporting

mixed data of sinus graft infection with other causes of sinusitis. Finally, 18 articles were included¹⁴⁻³¹.

[Figure 1 here]

A total of 3319 patients were included in these 18 articles, with 217 sinus graft infections. Two studies were prospective^{17,26} and 14 were retrospective^{14-16,18-25,28,29,31}; two studies did not clearly state their design^{27,30} (Table 1) [Au?2].

[Table 1 here]

Eligibility criteria could be divided into two types: studies including patients who underwent sinus grafting with or without simultaneous DI placement ($n = 8$)^{18,21-23,25,27,28,30}, and studies including only patients with infectious complications ($n = 10$)^{14-17,19,20,24,26,29,31}. Every study assessed the management of the sinus graft infection. The grafted material was known in 12 studies, with every type of material being represented^{15,16,18,20-23,27-31}.

The sinus grafting procedure was frequently associated with antibiotic prophylaxis: five studies reported preoperative antibiotic prophylaxis^{15,18,23,27,30}, and eight studies reported postoperative antibiotic prophylaxis^{15,18,20,21,23,25,27,30} (Table 2). Amoxicillin, with or without clavulanic acid, or clindamycin in the case of allergy, was used in every study except one, which used a cephalosporin³⁰. Postoperative antibiotic therapy ranged from 5 to 10 days. This was associated with non-steroidal anti-inflammatory drugs (NSAIDs) in five studies^{15,20,21,23,27} [Au?4] and corticosteroids in one study³⁰.

[Table 2 here]

Most studies included patients treated immediately by the investigators for the sinus graft infection, except three studies in which antibiotic therapy (sometimes multiple courses) were performed beforehand^{19,24,26} and one study in which several DI (26 out of the 34 DI placed) were removed beforehand²⁹.

The antibiotic therapy used to treat the sinus graft infection was more varied than the one used in prophylaxis. Six studies did not specify the type of antibiotic used, or the duration of the therapy^{19,21,25,28,30,31} (Table 2). Amoxicillin was the most frequently used antibiotic, prescribed with clavulanic acid in five studies^{14,15,23,27,29} (one also stating the use of cefazolin, without specifying how many patients received each of the two treatments²⁹) and without clavulanic acid in one study²⁰ [Au?2]. Other antibiotics used were metronidazole¹⁸, clindamycin²², cephalosporins (ceftriaxone²⁶, cefuroxime axetil²⁴ [Au?5], cefazolin²⁹ [Au?5]), and quinolones (ciprofloxacin^{16,24}, levofloxacin^{17,24}).

Antibiotic therapy was initiated preoperatively in two studies^{15,17}. The duration of antibiotic therapy postoperative varied from 7 to 14 days. It was stated to be associated with NSAIDs in five studies^{14-16,21,27}, and aerosol therapy containing antibiotic (gentamicin) and corticosteroids in one study²³.

The antibiotic therapy was mostly associated with surgical treatment. Only two studies relied on antibiotic therapy alone: for 16 out of 30 patients presenting with a sinus graft infection in one study²⁵ and for five cases of sinusitis (differentiated from graft infection) in the other study²³. The surgical protocol was detailed to various degrees, the main point being drainage through an intraoral or endoscopic (functional

endoscopic sinus surgery (FESS)), or combined approach, associated with graft removal. Drainage was performed with an intraoral approach in 13 studies^{14-16,18,20-23,25,27-30}, an endoscopic approach in two studies^{19,31}, and a combined approach in three studies^{17,24,26} (Table 3). Intraoral drainage was often associated with the irrigation of various products: saline¹⁵, hydrogen peroxide^{14,18}, iodine²¹, chlorhexidine^{28,29}, metronidazole^{18,21}, doxycycline²⁷. Sinus graft removal was performed completely in nine studies^{16-18,20-22,24,26,31} and partially in three studies^{15,27,28}, with the removed part based on the surgeon's intraoperative assessment. The sinus graft was left in place in two studies^{14,19}. The management of the graft was not clearly stated in the remaining four studies^{23,25,29,30}. DI were removed in two studies^{16,21}. Additional treatment to the one planned was necessary in eight studies, which included a second course of antibiotic therapy^{17,22,24,26} or a second surgical procedure^{16,20,23,24,26,30}. In most cases, this was performed only for one patient per study, except in the study by Chiapasco et al., in which four patients needed a second antibiotic therapy course, associated with a second procedure (FESS and DI removal) in one case.

[Table 3 here]

In every study, a disease-free sinus was finally obtained in all patients. The outcome of the sinus grafting was stated in 15 studies. The sinus graft was removed completely in nine studies [Au?6], and in two of these studies, a new graft was placed immediately during drainage: bone substitute²⁰ or platelet-rich fibrin (PRF)¹⁸. These grafts, as well as the DI placed (delayed placement [Au?7]¹⁸ or placed simultaneously²⁰), were all successful. In the studies where the graft was completely

removed but DI were placed simultaneously, one study showed DI failure of 63.6% (7/11)²¹ and the other showed one DI failure but the total number of DI placed is unknown²².

Among the studies where the sinus graft was partially removed, one study showed sufficient graft remaining, as delayed [Au?7] DI placement was described as successful in every case²⁷. The other two showed mixed results, with failure of the graft in three out of seven patients and failure of seven out of 12 simultaneously placed DI in the first study¹⁵. The second study showed failure of the graft in six out of nine patients, without any statement regarding the delayed [Au?7] DI placement²⁸.

Of the two studies where the sinus graft was left in place, the one reported by Ayna et al.¹⁴ showed the graft and delayed [Au?7] DI placement to be successful in every case; the study by Jiam et al.¹⁹ did not report the outcomes of the graft or DI. One study did not state the outcome of the graft itself, but compared the outcome regarding DI survival between the patients treated medically and those treated surgically: 30.3% (10/33) of the DI failed after isolated antibiotic therapy, while 4.9% (2/41) failed after surgical treatment²⁵.

Discussion

Maxillary sinus grafting is a frequent procedure with a reliable outcome. The literature is abundant on the most frequent technical intraoperative complication, which is Schneiderian membrane perforation, although it appears that it does not adversely affect DI survival¹¹. On the other hand, sinus graft infection is a severe complication, which is associated with morbidity and dental rehabilitation failure. Only 18 articles treating this complication could be included in the review. It is

difficult to draw conclusions, as the data and treatment protocols were heterogeneous. Furthermore, no study included more than 30 patients with a sinus graft infection, and several included fewer than 10 patients. The limited numbers of patients could be explained by the rarity of sinus graft infection, with rates of between 2% and 5.6% described¹⁰. The studies included in the present review showed an even wider range of occurrence of sinus graft infection, from 0.5% (out of 1874 patients included)¹⁸ and 11.6% (out of 259 patients included)²⁵.

Sinus graft infection cannot be related to other bone substitute infections in the body, as the graft is placed in a septic context (oral³² and sinus^{33,34} bacterial flora). This septic context leads to the widespread use of antibiotic prophylaxis and systematic postoperative antibiotic therapy in this elective surgery. Although widespread, evidence supporting antibiotic usage in dental implantology remains insufficient. Antibiotic prophylaxis using single-dose amoxicillin is recognized by some as effective at preventing DI failures, but not postoperative infections^{35,36}, while others state that definitive conclusions cannot be drawn yet³⁷. There is no evidence supporting the use of postoperative systematic antibiotic therapy after DI placement³⁵⁻³⁷. No randomized clinical trial has yet reported supporting evidence for antibiotic prophylaxis or postoperative antibiotic therapy after sinus augmentation [Au?2]. A consensus statement has been published in favour of amoxicillin–clavulanic acid, or clarithromycin associated with metronidazole in cases of penicillin allergy, as antibiotic prophylaxis and as postoperative antibiotic therapy¹². However, there are authors advocating antibiotic therapy only in cases of Schneiderian membrane perforation³⁴. Based on antibiograms of sinus flora cultures, the antibiotics found to have the greatest efficacy were ampicillin, amoxicillin–clavulanic acid, and ciprofloxacin³⁸.

Antibiotic prophylaxis was mentioned in five studies and postoperative antibiotic therapy in eight studies. Antibiotic prophylaxis was not mentioned in the other studies specifically, but it can be assumed that it was undertaken in most cases [Au?2]. Amoxicillin with or without clavulanic acid was the antibiotic of choice in the studies included, with clindamycin in cases of allergy and not clarithromycin. Further studies should be performed to clarify the best antibiotic for use during sinus grafting. Clindamycin is considered by some authors as a risk factor for loss of the grafted material¹⁸. Amoxicillin, mostly associated with clavulanic acid, was the most frequently prescribed, followed by quinolones and cephalosporins. Only eight out of the 217 patients reviewed required a second course of antibiotics, and only two of the regimens given were stated as targeted antibiotic therapy based on bacterial culture results [Au?2]. It seems that broad-spectrum antibiotic therapy targeting antibiotic-sensitive bacteria is effective [Au?2]. Indeed, the bacteria responsible for sinus graft infections are common bacteria from the oral cavity or the sinus. Systematic bacterial examination may be conducted, but does not have any impact on the antibiotic therapy performed¹⁹.

Surgical treatment of the sinus graft infection associated with antibiotic therapy was most often performed, with 199 out of the 217 patients receiving this treatment [Au?2]. According to some authors, surgical treatment of the infection can be avoided if the graft is well contained under the Schneiderian membrane with only a clear exudate from the surgical incision¹². Among the 21 patients treated without a surgical intervention, normal sinus function was restored in every case, but the outcome regarding the dental rehabilitation was poor. Indeed, 30.3% (10/33) of the DI failed following isolated antibiotic therapy, while 4.9% (2/41) failed following surgical treatment²⁵. Infection of the graft may be associated with biofilm coverage,

especially in the case of acellular grafts such as allograft, xenograft, or alloplast. Antibiotic therapy will treat the active infection but will have no effect on the bacteria protected by the biofilm. The recognized cornerstone of surgical treatment in such cases is graft removal¹², and this was performed in most of the studies included. Preoperative antibiotic therapy was detrimental to the outcome according to Park et al.¹⁵, emphasizing the need for rapid surgical treatment. Unfortunately, some studies did not specify the management of the sinus grafts, which when mobile within the purulent collection can be removed easily, even endoscopically²⁶. Surgical drainage was mostly performed through an intraoral approach, with or without FESS, while isolated FESS was less frequently performed (two out of the 18 studies). It should be noted that a non-endoscopic inferior antrostomy, which is a simple and well-known technique³⁹, was not described in the studies included. DI were systematically removed in only one study¹⁶. The patients included in that study also presented with peri-implantitis, which was the cause for DI removal. Indeed, DI were treated conservatively in the other studies and removed only if necessary.

Every study included reported a disease-free sinus as the final outcome, even if a secondary course of antibiotic therapy or surgical intervention was sometimes necessary. Pathological sinus was an exclusion criterion in most of the studies including consecutive sinus grafting. Therefore the sinus graft infections developed in a well-ventilated functional sinus [Au?2]. A disease-free sinus could be obtained with every treatment studied, including or excluding FESS. FESS does not seem to be mandatory to treat sinus graft infections.

Treatment without maxillary sinus sequelae can be achieved efficiently. The main complication is therefore loss of the graft, and the DI if placed simultaneously, requiring a secondary grafting procedure. Unfortunately, the outcome of the dental

rehabilitation was not stated systematically. Secondary grafting can be more challenging, especially if an oro-antral fistula is present²⁰. It can also lead to the abandonment of fixed prosthodontic treatment, which was the initial request of the patient, and therefore a significant decrease in patient quality of life.

Several methods were advocated to avoid secondary grafting, such as partial graft removal^{15,27,28} or prolonged sub-periosteal drainage¹⁴. When a graft is partially removed, this is based on the subjective decision of the clinician, as there is no means to determine which part of the graft is infected. The outcome is therefore very surgeon-dependent: 100% (8/8) sinus graft success was reported by Urban et al.²⁷, 57.1% (4/7) by Park et al.¹⁵ (with systematic additional grafting at 2 months), and 33.3% (3/9) by Chaushu et al.²⁸. Partial graft removal was associated with local antibiotic therapy (doxycycline or tetracycline) in two studies^{15,27}. Metronidazole has also been advocated as local antibiotherapy included in the initial graft to reduce anaerobic bacterial contamination⁴⁰. Another solution to avoid secondary grafting – prolonged sub-periosteal drainage – was described by Ayna et al.^{14,41}. This solution avoided graft removal, and DI were placed successfully 6 months later. However, the duration of implant survival was unclear [Au?2].

When the graft has been totally removed or lost, secondary grafting is necessary, which can be performed after a healing period. This option may be safer but will delay the final prosthesis delivery. Some authors have described successful secondary grafting during the drainage procedure. Khoury et al.¹⁸ described successful maxillary sinus augmentation with PRF performed immediately after infected graft removal, and further successful DI placement. Indeed, there is no evidence to suggest that more DI failure occurred in sinus lift with or without a bone graft^{9,42}. Kim and Kim²⁰ described successful maxillary sinus augmentation with autograft mixed with

allograft associated with a pedicled buccal fat pad flap for fistula closure and sinus roof reconstruction in four cases, but only three benefitted from delayed [Au?7] DI placement. They stressed the necessity of autograft when a bone substitute is placed in this context. Indeed, autograft should be used in this setting as it is the only osteogenic graft containing a cellular component⁴³, which will protect it against biofilm formation. Another option for one-stage surgical treatment of the infection associated with immediate secondary grafting can be performed using the Le Fort I osteotomy with autograft placement and a pedicled buccal fat pad as graft coverage^{44,45}. This technique allows easy removal of the infected graft, sinus drainage, oro-antral fistula closure if present, and immediate secondary grafting. This technique is safe and reliable, especially in cases of severe maxillary atrophy (Cawood class V and VI)⁴⁶.

The grafted material used in the studies included was heterogeneous, with some using a mix of various bone substitutes. It was therefore not possible to determine whether any particular bone substitute is more prone to infection based on the data collected [Au?2]. It should be noted that when autograft was grafted, it was always mixed with another bone substitute in all of the studies included.

The level of evidence in this review is poor, as 10 out of 18 studies included fewer than 10 patients with a sinus graft infection [Au?2]. No randomized controlled trial has compared the different management strategies for the infected graft [Au?2]. Most of the studies evaluated their own protocol without any control group. Only one study compared isolated antibiotic therapy with surgical treatment²⁵, and one study compared the incidence of long or short preoperative antibiotic therapy versus isolated postoperative antibiotic therapy in a small population (seven patients)¹⁵. The data are therefore mostly empirical. However, it is difficult to study greater series of patients as the incidence rate is low: between 0.5% (in a study including 1874 patients)¹⁸ and

11.6% (in a study including 259 patients)²⁵. Only two studies were prospective, and they were able to include only 14 patients¹⁷ and 20 patients²⁶, respectively.

There is a selection bias, as there were different inclusion criteria: some studies included consecutive sinus augmentation (8/18), while others included sinus graft infections (10/18). When patients undergoing consecutive sinus augmentation are included, the whole protocol of treatment can be known and each case of infection is managed. However, numerous patients are necessary since the incidence is low. When patients presenting with a sinus graft infection are included, it could be inferred that only the most serious patients are referred, as more benign cases could be treated in the community setting.

Some studies included patients undergoing sinus grafting and simultaneous DI placement, while in others the patients underwent only sinus grafting with delayed DI placement. This also represents a selection bias, as simultaneous DI placement is performed in cases with more residual maxillary bone when compared to two-stage surgeries. Hence, it should be expected larger grafts and more difficulty to place DI if the graft is lost in patients undergoing two-stage surgery [Au?8]. There is also a bias due to a lack of data regarding the graft and DI outcomes, whereas the sinus status was systematically stated. However, since a disease-free sinus was always obtained, the outcome is best evaluated on the basis of the graft or DI outcome. Data concerning the precise surgical treatment were very heterogeneous, with the intraoral approach encompassing different types of surgery: complete graft removal, partial graft removal and local antibiotic therapy, irrigation with various products, drain placement without removal of the material, immediate secondary grafting, and DI removal.

It is not possible to define the best treatment protocol for sinus graft infections based on the published data. Further studies should be conducted, ideally with very

large populations. This review highlights the necessity of surgical treatment associated with antibiotic therapy. Graft management is the cornerstone of the surgical care, if most authors advocate its removal, there may be interesting alternatives using local antibiotic therapy or prolonged drainage [Au?9]. We think that the infected graft should be removed in order to avoid major inflammatory reactions, which are responsible for major loss of the reconstructed bone and may prevent further DI placement.

In conclusion, sinus graft infection is a serious complication of sinus augmentation with an incidence of 0.5% to 11.6% based on the studies reviewed. Management is very heterogeneous; every protocol resulted in cure of the sinus, but the outcomes regarding the graft and the DI were more varied. This review highlights the necessity of surgical treatment associated with antibiotic therapy. However, it is not possible to define the best treatment protocol for sinus graft infections based on the published data, since the level of evidence is poor.

Funding

No funds, grants, or other support was received.

Competing interests

The authors have no conflicts of interest to declare.

Ethical approval

Not applicable.

Patient consent

Not applicable.

References

1. Brånemark PI, Hansson BO, Adell R, Breine U, Lindström J, Hallén O, et al. [Au?10] Osseointegrated implants in the treatment of the edentulous jaw. Experience from a 10-year period. *Scand J Plast Reconstr Surg Suppl* 1977; 16: 1–132.
2. Tatum H. Maxillary and sinus implant reconstructions. *Dent Clin North Am* 1986; 30: 207–229.
3. Boyne PJ, James RA. Grafting of the maxillary sinus floor with autogenous marrow and bone. *J Oral Surg* 1980; 38: 613–616.
4. Ting M, Rice JG, Braid SM, Lee CYS, Suzuki JB. Maxillary sinus augmentation for dental implant rehabilitation of the edentulous ridge: a comprehensive overview of systematic reviews. *Implant Dent* 2017; 26: 438–464. doi: 10.1097/ID.0000000000000606
5. Maló P, de Nobre M, Lopes A. Immediate loading of “All-on-4” maxillary prostheses using trans-sinus tilted implants without sinus bone grafting: a retrospective study reporting the 3-year outcome. *Eur J Oral Implantol* 2013; 6: 273–283.
6. Brånemark PI, Gröndahl K, Ohnrell LO, Nilsson P, Petruson B, Svensson B, et al. [Au?10] Zygoma fixture in the management of advanced atrophy of the maxilla: technique and long-term results. *Scand J Plast Reconstr Surg Hand Surg* 2004; 38: 70–85. doi: 10.1080/02844310310023918

7. Papaspyridakos P, De Souza A, Vazouras K, Gholami H, Pagni S, Weber HP. Survival rates of short dental implants (≤ 6 mm) compared with implants longer than 6 mm in posterior jaw areas: a meta-analysis. *Clin Oral Implants Res* 2018; 29(Suppl 16): 8–20. doi: 10.1111/clr.13289
8. Mohan N, Wolf J, Dym H. Maxillary sinus augmentation. *Dent Clin North Am* 2015; 59: 375–88. doi: 10.1016/j.cden.2014.10.001
9. Esposito M, Felice P, Worthington HV. Interventions for replacing missing teeth: augmentation procedures of the maxillary sinus. *Cochrane Database Syst Rev* 2014; 5: CD008397. doi: 10.1002/14651858.CD008397.pub2
10. Testori T, Weinstein T, Taschieri S, Wallace SS. Risk factors in lateral window sinus elevation surgery. *Periodontol 2000* 2019; 81: 91–123. doi: 10.1111/prd.12286
11. Al-Dajani M. Incidence, risk factors, and complications of Schneiderian membrane perforation in sinus lift surgery: a meta-analysis. *Implant Dent* 2016; 25: 409–415. doi: 10.1097/ID.0000000000000411
12. Testori T, Drago L, Wallace SS, Capelli M, Galli F, Zuffetti F, et al. [Au?10] Prevention and treatment of postoperative infections after sinus elevation surgery: clinical consensus and recommendations. *Int J Dent* 2012; 2012: 365809. doi: 10.1155/2012/365809
13. Moher D, Liberati A, Tetzlaff J, Altman DG; PRISMA Group. Preferred reporting items for systematic reviews and meta-analyses: the PRISMA statement. *PLoS Med* 2009; 6: e1000097. doi: 10.1371/journal.pmed.1000097
14. Ayna M, Ail Y, Wiltfang J, Gluses A. Histological aspects of a novel technique used for the management of infections secondary to sinus bone grafting. *J Craniofac Surg* 2020; 31: e560–e563. doi: 10.1097/SCS.00000000000006540

15. Park WB, Kang KL, Han JY. Intraoral approach for sinus graft infection following lateral sinus floor augmentation with simultaneous implant placement: a clinical case series. *J Oral Implantol* 2020; 46: 253–262. doi: 10.1563/aaid-joi-D-18-00296
16. Park WB, Han JY, Oh SL. Maxillary sinusitis associated with peri-implantitis at sinus floor augmented sites: case series. *Implant Dent* 2019; 28: 484–489. doi: 10.1097/ID.0000000000000922
17. Saibene AM, Collurà F, Pipolo C, Bulfamante AM, Lozza P, Maccari A, et al. [Au?10] Odontogenic rhinosinusitis and sinonasal complications of dental disease or treatment: prospective validation of a classification and treatment protocol. *Eur Arch Otorhinolaryngol* 2019; 276: 401–406. doi: 10.1007/s00405-018-5220-0
18. Khoury F, Javed F, Romanos GE. Sinus augmentation failure and postoperative infections associated with prophylactic clindamycin therapy: an observational case series. *Int J Oral Maxillofac Implants* 2018; 33: 1136–1139. doi: 10.11607/jomi.6517
19. Jiam NTL, Goldberg AN, Murr AH, Pletcher SD. Surgical treatment of chronic rhinosinusitis after sinus lift. *Am J Rhinol Allergy* 2017; 31: 271–275. doi: 10.2500/ajra.2017.31.4451
20. Kim YK, Kim SG. A retrospective analysis of the retreatment of failed sinus bone grafts. *Implant Dent* 2016; 25: 450–454. doi: 10.1097/ID.0000000000000420
21. Chirilă L, Rotaru C, Filipov I, Săndulescu M. Management of acute maxillary sinusitis after sinus bone grafting procedures with simultaneous dental implants placement—a retrospective study. *BMC Infect Dis* 2016; 16(Suppl 1): 94. doi: 10.1186/s12879-016-1398-1

22. Kayabasoglu G, Nacar A, Altundag A, Cayonu M, Muhtarogullari M, Cingi C. A retrospective analysis of the relationship between rhinosinusitis and sinus lift dental implantation. *Head Face Med* 2014; 10: 53. doi: 10.1186/1746-160X-10-53
23. Moreno Vazquez JC, Gonzalez de Rivera AS, Gil HS, Mifsut RS. Complication rate in 200 consecutive sinus lift procedures: guidelines for prevention and treatment. *J Oral Maxillofac Surg* 2014; 72: 892–901. doi: 10.1016/j.joms.2013.11.023
24. Felisati G, Chiapasco M, Lozza P, Saibene AM, Pipolo C, Zaniboni M, et al. [Au?10] Sinonasal complications resulting from dental treatment: outcome-oriented proposal of classification and surgical protocol. *Am J Rhinol Allergy* 2013; 27: e101–e106. doi: 10.2500/ajra.2013.27.3936
25. Kim YK, Hwang JY, Yun PY. Relationship between prognosis of dental implants and maxillary sinusitis associated with the sinus elevation procedure. *Int J Oral Maxillofac Implants* 2013; 28: 178–183. doi: 10.11607/jomi.2739
26. Chiapasco M, Felisati G, Zaniboni M, Pipolo C, Borloni R, Lozza P. The treatment of sinusitis following maxillary sinus grafting with the association of functional endoscopic sinus surgery (FESS) and an intra-oral approach. *Clin Oral Implants Res* 2013; 24: 623–629. doi: 10.1111/j.1600-0501.2012.02440.x
27. Urban IA, Nagursky H, Church C, Lozada JL. Incidence, diagnosis, and treatment of sinus graft infection after sinus floor elevation: a clinical study. *Int J Oral Maxillofac Implants* 2012; 27: 449–457.
28. Chaushu G, Mardinger O, Peleg M, Ghelfan O, Nissan J. Analysis of complications following augmentation with cancellous block allografts. *J Periodontol* 2010; 81: 1759–1764. doi: 10.1902/jop.2010.100235

29. Anavi Y, Allon DM, Avishai G, Calderon S. Complications of maxillary sinus augmentations in a selective series of patients. *Oral Surg Oral Med Oral Pathol Oral Radiol Endod* 2008; 106: 34–38. doi: 10.1016/j.tripleo.2007.09.021
30. Barone A, Santini S, Sbordone L, Crespi R, Covani U. A clinical study of the outcomes and complications associated with maxillary sinus augmentation. *Int J Oral Maxillofac Implants* 2006; 21: 81–85.
31. Doud Galli SK, Lebowitz RA, Giacchi RJ, Glickman R, Jacobs JB. Chronic sinusitis complicating sinus lift surgery. *Am J Rhinol* 2001; 15: 181–186. doi: 10.2500/105065801779954120
32. Verma D, Garg PK, Dubey AK. Insights into the human oral microbiome. *Arch Microbiol* 2018; 200: 525–540. doi: 10.1007/s00203-018-1505-3
33. Brook I. The microbiology of normal non-inflamed sinuses. *B-ENT* 2016; 12: 297–304.
34. Peleg O, Blinder D, Yudovich K, Yakirevitch A. Microflora of normal maxillary sinuses: does it justify perioperative antibiotic treatment in sinus augmentation procedures. *Clin Oral Investig* 2019; 23: 2173–2177. doi: 10.1007/s00784-018-2662-0
35. Rodríguez Sánchez F, Rodríguez Andrés C, Arteagoitia I. Which antibiotic regimen prevents implant failure or infection after dental implant surgery? A systematic review and meta-analysis. *J Craniomaxillofac Surg* 2018; 46: 722–736. doi: 10.1016/j.jcms.2018.02.004
36. Esposito M, Grusovin MG, Worthington HV. Interventions for replacing missing teeth: antibiotics at dental implant placement to prevent complications. *Cochrane Database Syst Rev* 2013; 2013: CD004152. doi: 10.1002/14651858.CD004152.pub4

37. Braun RS, Chambrone L, Khouly I. Prophylactic antibiotic regimens in dental implant failure: a systematic review and meta-analysis. *J Am Dent Assoc* 2019; 150: e61–e91. doi: 10.1016/j.adaj.2018.10.015
38. Carreño Carreño J, Gómez-Moreno G, Aguilar-Salvatierra A, Martínez Corriá R, Menéndez López-Mateos ML, Menéndez-Núñez M. The antibiotic of choice determined by antibiogram in maxillary sinus elevation surgery: a clinical study. *Clin Oral Implants Res* 2018; 29: 1070–1076. doi: 10.1111/clr.12835
39. Fernández-Olarte H, Gómez-Delgado A, López JP, Castro-Núñez J. The use of inferior meatal antrostomy to decrease sinusitis with the placement of zygomatic implants. *Int J Oral Maxillofac Implants* 2021; 36: 126–130. doi: 10.11607/jomi.8507
40. Choukroun J, Simonpieri A, Del Corso M, Mazor Z, Sammartino G, Dohan Ehrenfest DM. Controlling systematic perioperative anaerobic contamination during sinus-lift procedures by using metronidazole: an innovative approach. *Implant Dent* 2008; 17: 257–270. doi: 10.1097/ID.0b013e318181349a
41. Ayna M, Gülses A, Mede I. Management of infection after grafting of the sinus bone. *Br J Oral Maxillofac Surg* 2017; 55: 198–199. doi: 10.1016/j.bjoms.2016.06.021
42. Silva L deF, de Lima VN, Faverani LP, de Mendonça MR, Okamoto R, Pellizzer EP. Maxillary sinus lift surgery—with or without graft material? A systematic review. *Int J Oral Maxillofac Surg* 2016; 45: 1570–1576. doi: 10.1016/j.ijom.2016.09.023
43. Cawood JI, Stoelinga PJW, International Academy for Oral and Facial Rehabilitation. International Academy for Oral and Facial Rehabilitation—consensus report. *Int J Oral Maxillofac Surg* 2006; 35: 195–198. doi: 10.1016/j.ijom.2005.09.008

44. Pigache P, Anavekar N, Raoul G, Ferri J. Maxillary reconstruction for sinus lift complications with oro-antral fistula: the Le Fort I approach. *J Craniofac Surg* 2016; 27: 464–468. doi: 10.1097/SCS.0000000000002383
45. Schlund M, Nicot R, Lauwers L, Raoul G, Ferri J. Le Fort I osteotomy and calvarial bone grafting for severely resorbed maxillae. *J Craniomaxillofac Surg* 2016; 44: 859–867. doi: 10.1016/j.jcms.2016.04.015
46. Poli PP, de Nunes Lima V, Souza FÁ, Garcia Junior IR, Maiorana C. Clinical outcome of dental implant therapy in association with Le Fort I osteotomy preprosthetic surgery: a systematic review. *Int J Oral Maxillofac Implants* 2019; 34: 47–60. doi: 10.11607/jomi.6830

Figure caption

Fig. 1. Flow chart showing the article selection in accordance with the Preferred Reporting Items for Systematic Reviews and Meta-analyses statement (PRISMA).

Identification

Records identified through
database searching
(n = 1190)

Additional records identified
through other sources
(n = 0)

Screening

Records after duplicates removed
(n = 743)

Records screened
(n = 743)

Records excluded
(n = 688)

Eligibility

Full-text articles assessed
for eligibility
(n = 55)

Full-text articles excluded,
with reasons
(n = 37)
Case reports (n=26)
Technical notes (n=2)
Overview (n=3)
Consensus statement (n=1)
Full text unavailable (n=2)
Full text not in English (n=2)
Mixed data (n=1)

Included

Studies included in
qualitative synthesis
(n = 18)

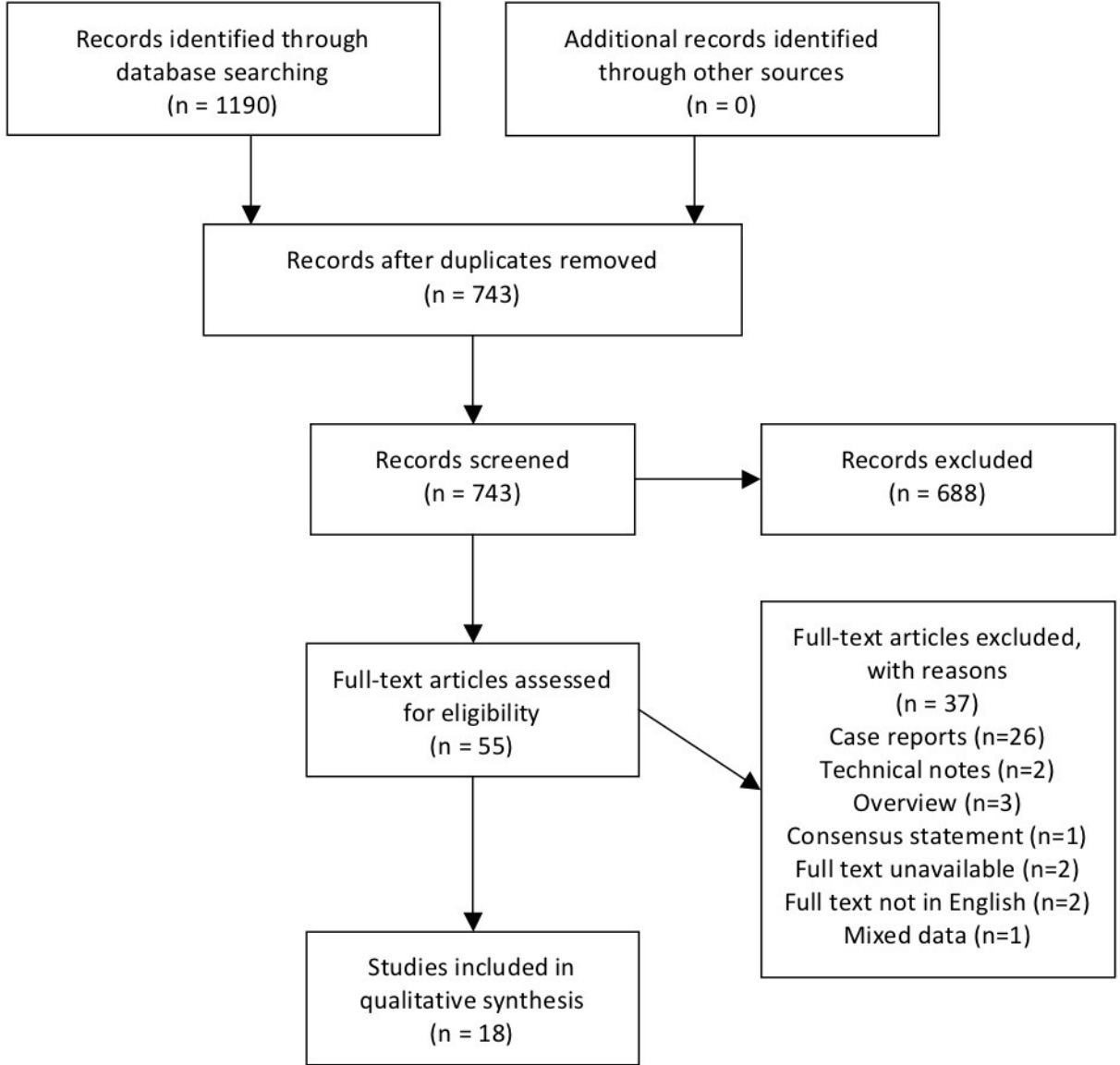


Table 1. Description of the included studies.

Author, year, Ref.	Eligibility criteria	Study design	Number of patients included	Number of sinuses included	Number of patients with SG infection	Grafted material
Ayna et al, 2020 ¹⁴	Sinus graft infection	Retrospective	17	?	17 (100%)	?
Park et al, 2020 ¹⁵	Sinus graft infection (simultaneous DIP)	Retrospective	7	?	7 (100%)	Allograft or xenograft (bovine) or xenograft + alloplast
Park et al, 2019 ¹⁶	Sinus graft infection	Retrospective	8	?	8 (100%)	Xenograft (bovine)
Saibene et al, 2019 ¹⁷	Sinus graft infection (+ sinonasal complication of dental treatment)	Prospective	128	137	14 (10.9%)	?
Khoury et al, 2018 ¹⁸	Sinus graft	Retrospective	1874	?	9 (0.5%)	Alloplast + Autograft
Jiam et al, 2017 ¹⁹	Sinus graft infection	Retrospective	9	13	9 (100%)	?
Kim and Kim, 2016 ²⁰	Sinus graft (retreatment following previous failure)	Retrospective	7	?	4 (57.1%)	Autograft + allograft
Chirilă et al, 2016 ²¹	Sinus graft (simultaneous	Retrospective	116	151	5 (4.3%)	Various mix of xeno/allo/autograft

	DIP)					(oral) + alloplast
Kayabasoglu et al, 2014 ²²	Sinus graft (simultaneous DIP)	Retrospective	94	145	4 (4.3%)	Allograft
Moreno Vazquez et al, 2014 ²³	Sinus graft	Retrospective	127	202	14 (11.0%)	Xenograft (bovine) + autograft (iliac or tibial or filtered bone) or bone block grafts
Felisati et al, 2013 ²⁴	Sinus graft infection (+ sinonasal complication of dental treatment)	Retrospective	257	?	25 (9.7%)	?
Kim et al, 2013 ²⁵	Sinus graft (simultaneous DIP)	Retrospective	259	338	30 (11.6%)	?
Chiapasco et al, 2013 ²⁶	Sinus graft infection	Prospective	20	23	20 (100%)	?
Urban et al, 2012 ²⁷	Sinus graft	?	198	274	8 (4.0%)	Autograft (oral) + xenograft (bovine) or xenograft alone
Chaushu et al, 2010 ²⁸	Sinus graft (simultaneous DIP)	Retrospective	101	32	9 (8.9%)	Allograft bone block

Anavi et al, 2008 ²⁹	Sinus graft infection	Retrospective	13	?	13 (100%)	Xenograft (bovine)
Barone et al, 2006 ³⁰	Sinus graft	?	70	124	7 (10%)	Autograft (oral or iliac) or autograft 50% + xenograft (porcine) 50%
Doud Galli et al, 2001 ³¹	Sinus graft infection	Retrospective	14	24	14 (100%)	Alloplast (hydroxyapatite) alone or + autograft (iliac) (4/14)

DIP, dental implant placement; SG, sinus graft.

Table 2. Antibiotic therapy in the included studies.

Author, year, Ref.	Antibiotic prophylaxis	SG postoperative therapy	Management of SG infection, prior to care by authors	Management of SG infection
[Au?11]				
Ayna et al, 2020 ¹⁴	?	?	?	Amoxicillin–clavulanic acid 10 days + NSAIDs + nasal spray
Park et al, 2020 ¹⁵	Amoxicillin (or clindamycin)	Amoxicillin–clavulanic acid 7 days + NSAIDs	– [Au?12]	Amoxicillin–clavulanic acid 7 days (2/7) or 14 days (2/7) preoperatively + 14 days postoperatively (7/7) (or levofloxacin) + NSAIDs
Park et al, 2019 ¹⁶	?	?	– [Au?12]	Ciprofloxacin 14 days + NSAIDs
Saibene et al, 2019 ¹⁷	?	?	– [Au?12]	Levofloxacin 5 days preoperatively + 10 days postoperatively (or cefuroxime axetil)
Khoury et al, 2018 ¹⁸	Amoxicillin (or clindamycin)	Amoxicillin (or clindamycin) 10 days	– [Au?12]	Metronidazole 7 days
Jiam et al, 2017 ¹⁹	?	?	Antibiotic therapy (8/9), DI removal	Antibiotic therapy

			(4/9), intraoral drainage (1/9)	
Kim and Kim, 2016 ²⁰	?	Amoxicillin 7 days	- [Au?12]	Amoxicillin 7 days
Chirilă et al, 2016 ²¹	- [Au?12]	Clindamycin 5 days + NSAIDs	- [Au?12]	Antibiotic therapy and NSAIDs
Kayabasoglu et al, 2014 ²²	?	?	- [Au?12]	Clindamycin 10 days
Moreno Vazquez et al, 2014 ²³	Amoxicillin- clavulanic acid + dexamethasone	Amoxicillin-clavulanic acid 8 days + NSAIDs	- [Au?12]	Amoxicillin-clavulanic acid + fluticasone + aerosol therapy (gentamicin, mesna, fluocinolone, budesonide) 14 days
Felisati et al, 2013 ²⁴	?	?	Medical treatment	Cephalosporin therapy (cefazolin during hospitalization + cefuroxime axetil 6-7 days after discharge) OR quinolone therapy (levofloxacin or ciprofloxacin during hospitalization + 8-9 days after discharge)
Kim et al, 2013 ²⁵	- [Au?12]	Antibiotic therapy 5 days	- [Au?12]	Antibiotic therapy

		+ NSAIDs		
Chiapasco et al, 2013 ²⁶	?	?	Antibiotic therapy	Ceftriaxone 7–10 days
Urban et al, 2012 ²⁷	Amoxicillin (or clindamycin)	Amoxicillin (or clindamycin) 7 days + NSAIDs	– [Au?12]	Amoxicillin–clavulanic acid 7 days + NSAIDs + nasal decongestant
Chaushu et al, 2010 ²⁸	?	?	– [Au?12]	Antibiotic therapy
Anavi et al, 2008 ²⁹	?	?	26 DI removed out of 34 placed	Amoxicillin–clavulanic acid or cefazolin
Barone et al, 2006 ³⁰	Cephalosporin + dexamethasone	Cephalosporin 5 days + dexamethasone	– [Au?12]	Antibiotic therapy
Doud Galli et al, 2001 ³¹	?	?	– [Au?12]	Antibiotic therapy

DI, dental implant; NSAID, non-steroidal anti-inflammatory drug; SG, sinus graft.

Table 3. Surgical care and outcomes in the included studies. [Au?13]

Author, year, Ref.	Intraoral drainage	Endoscopic drainage (FESS)	Graft removal	Implant removal	Additional treatment if necessary	Outcome		
						Sinus	Graft	Implant
Ayna et al, 2020 ¹⁴	+ (+ H ₂ O ₂ irrigations)	-	-	-	-	Disease-free sinus	Initial SG success	Delayed [Au?7] DIP successful
Park et al, 2020 ¹⁵	+ (+ saline irrigations)	-	+ (partial)	-	-	Disease-free sinus	Initial SG success (4/7), SG failure (3/7)	7/12 DI failed
Park et al, 2019 ¹⁶	+ (4/8)	-	+ (4/8)	+ (8/8)	1 second procedure for OAF closure	Disease-free sinus	SG removed (4/8)	DI removed
Saibene et al, 2019 ¹⁷	+	+	+	-	1 second course of antibiotic therapy	Disease-free sinus (1 lost to follow-up)	SG removed	x [Au?14]
Khoury et al, 2018 ¹⁸	+ (+ H ₂ O ₂ and metronidazole irrigations) + PDT	-	+	-	-	Disease-free sinus	SG (PRF) performed during drainage,	Delayed [Au?7] DIP successful

Jiam et al, 2017 ¹⁹	-	+	-	-	-	Disease-free sinus	successful ?	?
Kim and Kim, 2016 ²⁰	+ (+ irrigations)	-	+	-	1 second procedure (intraoral drainage)	Disease-free sinus	SG performed during drainage, successful	5/5 DI successful
Chirilă et al, 2016 ²¹	+ (+ iodine or metronidazole irrigations)	-	+	+ (3/5)	-	Disease-free sinus	SG removed	7/11 DI removed
Kayabasoglu et al, 2014 ²²	+	-	+	-	1 second course of antibiotic therapy	Disease-free sinus	SG removed	1 DI failed
Moreno Vazquez et al, 2014 ²³	+ (9/14)	-	?	-	1 FESS	Disease-free sinus	?	?
Felisati et al, 2013 ²⁴	+	+	+	-	1 second procedure (DI removal); 2 specific antibiotic therapy	Disease-free sinus	SG removed	x [Au?14]

Kim et al, 2013 ²⁵	+ (14/30)	-	?	-	-	Disease-free sinus	?	10/33 DI failed after isolated antibiotic therapy; 2/41 DI failed after surgical treatment
Chiapasco et al, 2013 ²⁶	+	+	+	-	1 second procedure (intraoral + FESS + DI removal); 4 second course of antibiotic therapy	Disease-free sinus	SG removed	x [Au?14]
Urban et al, 2012 ²⁷	+ (+ local doxycycline)	-	+ (partial)	-	-	Disease-free sinus	Initial SG success	Delayed [Au?7] DIP successful
Chaushu et al, 2010 ²⁸	+ (+ chlorhexidine irrigation)	-	+ (partial)	-	-	Disease-free sinus	Initial SG success (3/9), SG failure (6/9)	?
Anavi et al, 2008 ²⁹	+ (+ chlorhexidine irrigation)	-	?	-	-	Disease-free sinus	SG failure	x [Au?14]

Barone et al, 2006 ³⁰	+	-	?	-	2 FESS	Disease-free sinus	SG failure	x [Au?14]
Doud Galli et al, 2001 ³¹	-	+	+	-	-	Disease-free sinus	SG removed	x [Au?14]

DI, dental implant; DIP, dental implant placement; FESS, functional endoscopic sinus surgery; OAF, oro-antral fistula; PDT, photodynamic therapy; PRF, platelet-rich fibrin; SG, sinus graft. [Au?15]