



HAL
open science

The evolving role of neurosurgery for central nervous system metastases in the era of personalized cancer therapy

Philipp Karschnia, Emilie Le Rhun, Michael A. Vogelbaum, Martin J. van den Bent, Stefan J. Grau, Matthias Preusser, Riccardo Soffietti, Louisa von Baumgarten, Manfred Westphal, Michael Weller, et al.

► To cite this version:

Philipp Karschnia, Emilie Le Rhun, Michael A. Vogelbaum, Martin J. van den Bent, Stefan J. Grau, et al.. The evolving role of neurosurgery for central nervous system metastases in the era of personalized cancer therapy. *European Journal of Cancer*, 2021, *European Journal of Cancer*, 156, pp.93-108. 10.1016/j.ejca.2021.07.032 . hal-04009526v1

HAL Id: hal-04009526

<https://hal.univ-lille.fr/hal-04009526v1>

Submitted on 1 Mar 2023 (v1), last revised 21 Apr 2023 (v2)

HAL is a multi-disciplinary open access archive for the deposit and dissemination of scientific research documents, whether they are published or not. The documents may come from teaching and research institutions in France or abroad, or from public or private research centers.

L'archive ouverte pluridisciplinaire **HAL**, est destinée au dépôt et à la diffusion de documents scientifiques de niveau recherche, publiés ou non, émanant des établissements d'enseignement et de recherche français ou étrangers, des laboratoires publics ou privés.



Distributed under a Creative Commons Attribution - NonCommercial - NoDerivatives 4.0 International License



Review

The evolving role of neurosurgery for central nervous system metastases in the era of personalized cancer therapy



Philipp Karschnia ^{a,b}, Emilie Le Rhun ^c, Michael A. Vogelbaum ^d,
 Martin van den Bent ^e, Stefan J. Grau ^f, Matthias Preusser ^g,
 Riccardo Soffietti ^h, Louisa von Baumgarten ^{a,b}, Manfred Westphal ⁱ,
 Michael Weller ^j, Joerg-Christian Tonn ^{a,b,*}

^a Department of Neurosurgery, Ludwig-Maximilians-University School of Medicine, Munich, Germany

^b German Cancer Consortium (DKTK), Partner Site Munich, Germany

^c Department of Neurosurgery & Clinical Neuroscience Center, University Hospital and University of Zurich, Zurich, Switzerland

^d Department of NeuroOncology, Moffitt Cancer Center, Tampa, FL, USA

^e Department of Neurology, Erasmus MC Cancer Institute, Rotterdam, the Netherlands

^f Department of Neurosurgery, University Hospital of Cologne, Cologne, Germany

^g Department of Medicine I, Division of Oncology, Medical University of Vienna, Vienna, Austria

^h Department of Neuro-Oncology, University and City of Health and Science Hospital, Turin, Italy

ⁱ Department of Neurosurgery, University Hospital Hamburg, Hamburg, Germany

^j Department of Neurology & Clinical Neuroscience Center, University Hospital and University of Zurich, Zurich, Switzerland

Received 28 May 2021; received in revised form 21 July 2021; accepted 26 July 2021

Available online 20 August 2021

KEYWORDS

Metastasis;
 Cerebral;
 CNS;
 Neurological surgery;
 Quality of life

Abstract Recent therapeutic advances involving the use of systemic targeted treatments and immunotherapeutic agents in patients with advanced cancers have translated into improved survival rates. Despite the emergence of such promising pharmacological therapies and extended survival, the frequency of metastases in the central nervous system has steadily increased. Effective medical and surgical therapies are available for many patients with brain metastases and need to be incorporated into multi-disciplinary care protocols. The role of neurosurgeons is evolving within these multi-disciplinary care teams. Surgical resection of brain metastases can provide immediate relief from neurological symptoms due to large lesions and provides the histopathological diagnosis in cases of no known primary malignancy. In situations where immunotherapy is part of the oncological treatment plan, surgery may be

* Corresponding author: Chair of the Department of Neurosurgery, Ludwig Maximilians University School of Medicine, Marchioninistrasse 15, 81377, Munich, Germany. Fax: +49 (0)89 4400-72592.

E-mail address: Joerg.Christian.Tonn@med.uni-muenchen.de (J.-C. Tonn).

proposed for expeditious relief of edema to remove the need for steroids. In patients with multiple brain metastases and mixed response to therapeutics or radiosurgery, tumour resampling allows tissue analysis for druggable targets or to distinguish radiation effects from progression. Ventriculo-peritoneal shunting may improve quality of life in patients with hydrocephalus associated with leptomeningeal tumour dissemination and may allow for time to administer more therapy thus prolonging overall survival. Addressing the limited efficacy of many oncological drugs for brain metastases due to insufficient blood–brain barrier penetration, clinical trial protocols in which surgical specimens are analysed after pre-surgical administration of therapeutics offer pharmacodynamic insights. Comprehensive neurosurgical assessment remains an integral element of multi-disciplinary oncological care of patients with brain metastases and is integral to tumour biology research and therapeutic advancement. © 2021 The Author(s). Published by Elsevier Ltd. This is an open access article under the CC BY-NC-ND license (<http://creativecommons.org/licenses/by-nc-nd/4.0/>).

1. Introduction

Central nervous system (CNS) metastases arise from haematogenous dissemination of cells from an extracranial primary cancer to the CNS. An estimated 20–40% of patients with metastatic solid cancers are expected to develop brain metastases [1]. Patients with melanoma or carcinoma of the lung and breast are at particularly high risk, and recent therapeutic advances have translated into favorable outcomes for patients with those cancers [2,3]. Given that patients with cancer are expected to survive longer turning cancer into a chronic disease, and that many of these new therapeutics do not have access to the CNS, the risk of brain metastasis over the lifetime of these patients is expected to increase [4].

A relevant number of patients with clinically symptomatic brain metastases succumb to their intracranial tumour(s) despite control of extracranial disease [5]. Clinical divergence in response to anti-tumour therapy might be explained not only by insufficient penetration of therapeutic agents across the blood–brain barrier/blood–tumour barrier, but also by the finding that the genetic profiles of brain metastases may differ from those of the primary tumours [6]. Approximately 50% of brain metastases may harbor clinically relevant mutations, which are not present in the primary tumour [7]. The number of actionable mutations as well as the extent of genomic discrepancies between the primary tumours and their respective brain metastases depends on the histologic tumour subtype [8–10], and a thorough tissue-based analysis of brain metastasis may help to guide therapy. With an increasing understanding of the individual cellular and molecular tumour targets available in a cancer, novel personalized treatment strategies are emerging [11]. Effective (targeted) medical and surgical therapies are available for subgroups of brain metastasis patients when targetable individual tumour- and patient-specific factors are present [12,13]. Accordingly, treatment of brain metastasis patients

needs to be performed in the setting of multi-disciplinary care teams that can discuss and consider the full range of therapeutic options. Neurosurgical approaches play an important role in the range of multi-disciplinary therapies, and the indications for surgical treatment of brain metastases are currently evolving. In this review, we provide a critical overview of the changing role of neurosurgery for brain metastases. We outline recent results from clinical studies and discuss current challenges, ongoing studies, and future directions.

2. Current state of pharmacological therapies: targeted therapies and immunotherapies

The number of novel effective systemic treatment options, such as immune checkpoint inhibitors and drugs that target molecular alterations in key oncogenic drivers (targeted therapies) is continuously increasing (Table 1 and Table 2). These advances have translated into a relevant clinical benefit and changed the management of many patients with brain metastases according to molecular subtypes [14–16]. New therapies may therefore offer additional, often effective therapeutic options even in patients with heavily pre-treated brain metastases, thus potentially justifying another surgical intervention.

For melanoma patients, the survival of patients with brain metastases has improved after the introduction of BRAF inhibitors (vemurafenib, dabrafenib) combined with MEK inhibitors and immune checkpoint inhibitors such as ipilimumab, nivolumab, and pembrolizumab. BRAF mutations in malignant melanoma are highly preserved during formation of brain metastases, and presence of BRAF mutations at the primary tumour site therefore predicts BRAF mutations also in cerebral metastatic sites [17,18]. Even in the absence of targetable mutations, the combination of the PD1 inhibitor nivolumab and the CTLA4 inhibitor ipilimumab is effective in the treatment of brain metastases from malignant melanoma [12,19,20]. Given a

Table 1
Targeted therapies in the treatment of brain metastasis.

Molecular target	Substance class	Substance
Targeted therapies for brain metastasis of NSCLC		
EGFR (29% of NSCLC BM) [114]	Tyrosin kinase inhibitor	Gefitinib
	First generation	Erlotinib
	Second Generation	Afatinib
	Third Generation	Osimertinib
ALK (5% of NSCLC BM) [115]	Tyrosin kinase inhibitor	Crizotinib
	First generation	
	Second Generation	Ceritinib
		Alectinib
		Brigatinib
	Third Generation	Lorlatinib
MEK	Small molecule MEK inhibitor	Trametinib
BRAF	Small molecule BRAF inhibitor	Dabrafenib
NTRK	Small molecule NTRK inhibitor	Larotrectinib
	Small molecule NTRK/ROS inhibitor	Entrectinib
Targeted therapies for brain metastasis of breast cancer		
HER2 (25% of breast cancer BM) [116]	Monoclonal antibody	Trastuzumab
		Pertuzumab
	Antibody drug conjugate	Trastuzumab-Emantansin (T-DM1)
	Tyrosin kinase inhibitor	Lapatinib
		Neratinib
		Tucatinib
CDK4/6	Small molecule CDK4/CDK6 inhibitor	Palbociclib
		Abemaciclib
BRCA1/BRCA2	Small molecule PARP inhibitor	Olaparib
		Talazoparib
PIK3CA	Small molecule PIK3CA inhibitor	Alpelisib
Targeted therapies for brain metastasis of melanoma		
BRAF (50% of melanoma BM) [117]	Small molecule BRAF inhibitor	Vemurafenib
		Dabrafenib
		Encorafenib
	Small molecule MEK inhibitor	Trametinib
		Cobimetinib
		Binimetinib

Molecular targets, substance classes, and substances are given for the most frequently used targeted therapies utilized for the treatment of brain metastases. Abbreviations: BM: brain metastases; NSCLC: non-small cell lung cancer.

relatively high response rate of about 50% (although of variable durability), this immunotherapeutic combination is therefore now considered standard first-line therapy in previously untreated, asymptomatic and rather small brain metastases from malignant melanoma [21]. In patients with ALK or EGFR mutated non-small cell lung cancer (NSCLC), several generations of EGFR and ALK inhibitors with increasing CNS permeability have been developed and show relevant intracranial activity, also improving overall survival [22]. Notably, NSCLC harboring ALK rearrangement or EGFR mutation appears to have a higher cumulative incidence of brain metastases compared to tumours without such molecular markers [23]. Discordance in regard to EGFR status between brain metastases and matched NSCLC samples has been reported in 0–33% of cases (also including presence of EGFR mutations within brain metastases in the absence of respective findings in the primary tumour), whereas the discordance rate for ALK rearrangements might be somewhat lower and in the range of

0–13% [18]. HER-2-targeted therapies (monoclonal antibodies and tyrosine kinase inhibitors), alone or in combination, produced substantial intracranial responses in patients with HER-2 positive breast cancer brain metastasis [24]. Reexamination of brain metastasis tissue for the presence of HER-2 is recommended given that a brain metastasis-specific change in HER-2 status of has been reported in 14% of breast cancer patients [18,25]. Immune checkpoint inhibitors have

Table 2
Immune checkpoint inhibitors.

Molecular target	Substance class	Substance
CTLA4	Monoclonal antibody	Ipilimumab
PD-1	Monoclonal antibody	Nivolumab
		Pembrolizumab
PD-L1	Monoclonal antibody	Atezolizumab
		Durvalumab
		Avelumab

Molecular targets, substance classes, and substances are given for immune-checkpoint inhibitors approved in the United States and Europe for the treatment of solid cancers.

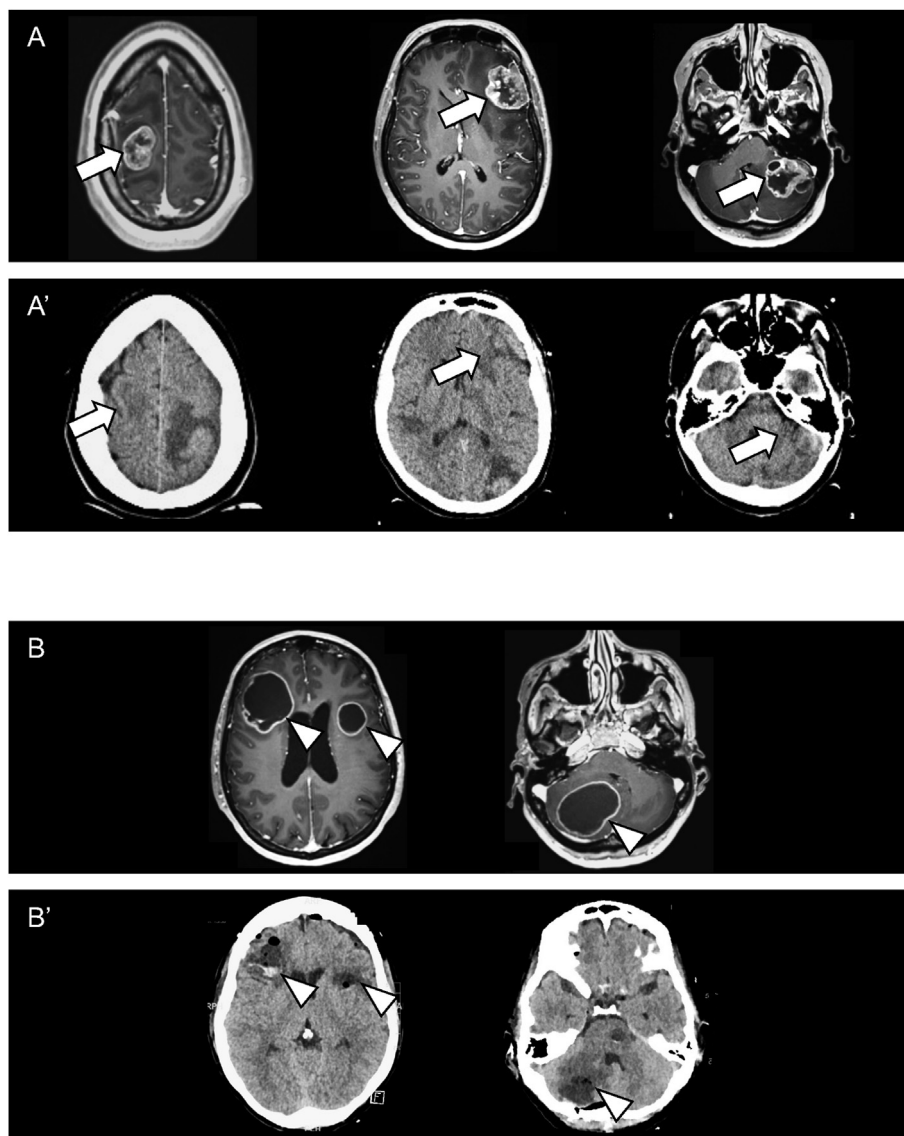


Fig. 1. Surgical resection of multiple metastases enabling further therapy. A: Gd-enhanced MRI of a 39-year-old female with known breast cancer developing a left-sided hemiparesis. The dilemma consisted of a large metastasis threatening hydrocephalus, a left frontal metastasis with signs of dysphasia, and the symptomatic right sided lesion in addition to 6 more lesions (arrows). A': As there was a surgical indication for each lesion, all lesions were removed in one session without any sequelae as seen on the CT immediately post-OP before awakening the patient after the successive craniotomies. WBRT was started four weeks after surgery. B: Gd-enhanced MRI of a 50-year-old non-smoker who presented with headache and nuchal pain thought to arise from the cervical spine. On MRI, three lesions (arrowheads) with initial signs of hydrocephalus were seen; and subsequently a suspicious lesion was found in the lung. B': Analogous CT on the way between surgery and post-OP ward showing uneventful removal in one session of all three lesions, each of which had a surgical indication. This enabled molecular analysis showing an Exon 19 EGFR mutation as well as a p53 mutation allowing targeted therapy in addition to WBRT, which in the presence of the lesions would have had to be abandoned with high probability due to exhausted brain compliance with mass effect and hydrocephalus.

shown promising benefits in the treatment of patients with brain metastasis from NSCLC without targetable mutations and are under investigation in patients with brain metastases from triple negative breast cancer [14,15]. New actionable targets for brain metastasis of NSCLC (e.g. ROS1 rearrangements, NTRK fusions) and breast cancer (cyclin-dependent kinases (CDK) 4/6) hold promise for further investigations [16]. Since the number of treatment options is expected to further

increase, it will be essential to optimally orchestrate surgery or other local therapies with targeted therapies or immunotherapeutic approaches.

3. Indications and oncological considerations for surgery

Neurosurgical resection of a brain metastasis is traditionally recommended for patients presenting with a limited number of intracranial lesions, who have a good

performance status and have controlled or potentially controllable extracranial disease, or who have mass effect that must be relieved within a short time window due to clinical presentation [14]. Complete resection of contrast-enhancing tumour in patients with two or three metastases may yield survival outcomes similar to those in patients with one metastasis only [26,27], and surgery for three metastases is commonly considered as an upper-limit from an oncological standpoint (although there may be additional, small metastases present that do not require surgical resection) [14]. Approximately 30% of brain metastasis patients initially present with only one lesion, whereas around one third of patients are found to have four or more metastases on initial brain imaging [28].

Neurosurgical resection of more than three metastatic lesions has traditionally not been routinely performed, and the need to resect more than three tumours was typically an exclusion criterion in study protocols evaluating the role for surgery [29]. Given that this limit is not based on prospective data, a general cut-off of three brain metastases cannot be categorically applied and there will be patients with new disease in the CNS with otherwise controlled systemic disease and excellent performance status, where there might be a role for surgery to prevent imminent demise, reverse neurologic deficits, and improve overall outcomes [30]. More recently the focus of neurosurgical decision-making has moved towards reduction of tumour-associated symptoms rather than the mere consideration of the number of metastases, as the resection of a symptomatic mass may improve a patient's neurological as well as general conditions and facilitate the feasibility of systemic therapy. In this context, surgery may be considered in patients with poor performance status if the latter is caused by the mass effect produced by the cerebral tumour [31]. In addition, a combination of different treatment measures may lead to cerebral disease control also in patients with multiple metastases, in particular if good systemic treatment options are available [32].

3.1. Enabling further medical therapy

With respect to the importance a patient's overall clinical status in multimodal therapeutic decision-making, the resection of a symptomatic mass may be considered even in presence of multiple tumours [31,33]. Removal of multiple lesions may provide important time for the patient's condition to improve to a point where, depending on histology and marker assessment in the removed specimens, additional medical therapy may provide additional disease control with an acceptable quality of life (Fig. 1) [34].

Moreover, patients presenting with tumours that produce a large volume of edema commonly require steroids [35]. Edema may result from a newly diagnosed metastasis or may evolve or reoccur subsequent to

radiosurgery which may have transformed a lesion into radionecrosis. Apart from the detrimental long-term effects of steroids on muscle, bone, and metabolism among other side effects, a recently emerging aspect is their interference with immunotherapy which is increasingly part of new therapeutic paradigms such as immune checkpoint inhibition and cellular immunotherapy [36,37]. Removal of the mass will not only establish a diagnosis (especially when radionecrosis is considered) but will allow patients to start immunotherapy or access clinical trials evaluating immunotherapies from which they are currently excluded, e.g. NCT01844505 in melanoma patients or NCT02763579 in lung cancer patients. Especially in patients with a large metastases and edema, surgical removal of the metastasis is more likely to rapidly alleviate edema than any radiotherapeutic approach alone [38]. The issue of interference of immunotherapy by steroids is currently evaluated in a clinical trial that includes melanoma patients (NCT03563729) addressing the question whether immune checkpoint inhibition might be also effective in individuals who require chronic steroid treatment. Results from this prospective cohort will clarify whether large steroid-requiring lesions indeed should be removed prior to immunotherapy. In turn, immunotherapy followed by surgery warrants also evaluation as some data suggest increased efficacy compared to immunotherapy alone [13]. Tumour resection, however, has to be considered in the context of the impact of postoperative recovery time after surgery and the risk of neurological sequelae with a decreased performance status which is a critical inclusion criterion in most trials.

3.2. Cognitive function and quality of life: impact of radiotherapy and localized treatments

Whole-brain radiotherapy (WBRT) or stereotactic radiosurgical treatment of the surgical resection cavity has been associated with improved local intracranial disease control [27,39], and stereotactic fractionated radiosurgery might be considered for large (>2–3 cm) unresectable lesions not qualifying for radiosurgery [14]. Although single fraction and fractionated stereotactic radiosurgery are less likely to produce cognitive decline than the historically more frequently used WBRT [40], the adverse effects of any form of radiotherapy on neurocognitive function and its substantial impact on quality of life needs to be carefully weighed against its potential benefit to survival [41–44]. High-level evidence data are scarce, but localized treatment approaches such as surgery plus radiosurgery or radiosurgery appear to result in a lower degree of cognitive deterioration than when WBRT is used [40,45]. This finding is of particular relevance given that the prognosis in subgroups of brain metastasis patients is improving. Therefore, patients may be more likely to experience long-term side-effects of anti-cancer therapy.

4. Surgical concepts

In contrast to primary brain tumours, local cure by complete surgical resection (with perioperative radiosurgery) can be in principle achieved for brain metastases given the inherent biologic differences in regard to growth pattern between primary and secondary brain tumours [46]. A central goal of surgery is therefore to remove all tumour tissue visible on imaging, and early postoperative MRI is recommended as residual tumour is detected in up to 20% of patients [14,47]. This imaging influences the planning of post-operative treatments including planning of adjuvant radiosurgery or consideration of a second surgery to complete the resection [48]. Surgery for malignancies outside the brain follows the oncological principle of *en bloc* resection where the complete tumour is removed without violating its structural integrity. Such an approach may decrease tumour cell spillage and is also the goal wherever possible in the neurosurgical approach to brain metastases. Patel *et al.* reported on a large retrospective series of 570 patients with previously untreated single brain metastases [49] and found that *en bloc* resection resulted in decreased local recurrence compared to piecemeal resection. Suki *et al.* analysed 379 patients with metastatic posterior fossa lesions and showed that patients undergoing a piecemeal resection are at increased risk for leptomeningeal dissemination [50]. Similar findings have been made in patients with supratentorial metastases [51], and are supported by more recent data [52]. However, all these data report on heterogenous cohorts of patients with different adjuvant and/or systemic treatment regimens and were generated prior to the introduction of effective systemic therapies for several types of cancer associated with brain metastases. Of note, the use of *en bloc* resection appears not to be associated with an increased rate of postoperative neurological complications even when tumours involve eloquent brain regions [53]. As tumour cells may invade the parenchyma beyond macroscopic tumour margins [46], more aggressive surgical approaches including resecting a thin layer of surrounding tissue on the lesion have been evaluated. Based on a retrospective cohort of 94 patients with non-eloquent brain metastases, Yoo *et al.* postulated that better local tumour control might be achieved when resection margins are intraoperatively analysed so that no malignant growth extends past the margins of the resected tumour [54]. On the contrary, a recent retrospective study reported no relevance of tumour remnants for local control or survival if patients underwent further (radio-)oncological treatment [55]. Furthermore, a prospective randomized trial by Mahajan *et al.* compared post-operative stereotactic radiosurgery and observation only in completely resected brain metastases and observed a significant difference in local control when postoperative radiosurgery was applied,

independent of the method of resection [39]. This can be interpreted as a strong indirect proof that an aggressive local therapy substantially lowers the risk of local recurrence.

Keeping in mind the importance of neurological integrity of the patients, radicality of resection should not be obtained at the expense of functional outcome. Safe maximal resection particularly in critical functional areas might be improved by intraoperative neuromonitoring [56]. Fluorescence-guided resection in brain metastases has been described [57]; however, the use of 5-aminolevulinic acid (ALA) does not seem to translate into improved local control or survival in patients with brain metastases [58]. This might be due to inconsistent fluorescence of brain metastases (ranging from 25 to 83% depending on the type of primary tumour, with less common fluorescence in melanoma metastases and more common fluorescence in ductal breast cancer metastases) [58–60], a less strict correlation of extent of resection and outcome compared to primary brain tumours [55,61], and the use of stereotactic radiosurgery as an effective salvage therapy [39]. Importantly, the presence of 5-ALA fluorescence *per se* has been shown to be associated with more favorable survival and lower local relapse rates, which potentially points towards a role of 5-ALA as a marker tumour infiltration and angiogenesis [59]. On a cautionary note, a 2% risk for iatrogenic CNS infections during the postoperative setting as well as surgery-related neurological deficits may not only critically delay the initiation of systemic therapy [31,62], but may also cause or aggravate cognitive impairment [63].

4.1. Timing of surgery

Potential side effects of medical anti-tumour therapies may interfere with surgical procedures within the brain: chemotherapies may induce thrombocytopenia and leukocytopenia which increases the risk for intraoperative and postoperative haemorrhages or infections [62]; and steroids, anti-angiogenic agents, as well as ongoing chemo- or radiotherapy adversely affect wound healing [64,65]. Deferring surgery might not be an option in selected patients; however, elective cases should not be scheduled around an expected blood cell count nadir, steroids should be tapered whenever possible, and an interval of at least four weeks between administration of anti-angiogenic agents targeting the vascular endothelial growth factor pathway and surgery is recommended [64]. Thus, timing of the surgical procedure within the framework of different therapeutic modalities is crucial. The best timing and sequence of the combination of surgery and stereotactic radiotherapy is also currently questioned, and trials are ongoing to answer this question (NCT03368625, NCT04474925).

5. Suspected recurrent disease and repetitive tissue analysis

Therapy-associated neuroimaging changes are frequently seen after stereotactic radiosurgery and may represent progressive disease or radiation necrosis. Less well characterized are inflammatory reactions in the context of the novel immunotherapeutic approaches. Imaging criteria to distinguish progressive disease from therapy-induced changes have been proposed [66–68]. Recent studies utilizing advanced imaging approaches such as amino acid PET have demonstrated changes in disease dynamics which differ from MRI changes [69]. Definitive diagnosis for further therapy planning such as inclusion into or termination of clinical trials requires tissue analysis particularly when imaging modalities are inconclusive [70,71]. Thus, either resection or at least biopsy are then to be considered. However, the histological diagnosis of radiation necrosis can be difficult, and commonly histological features of radiation necrosis and viable tumour coexist.

For non-resectable lesions, stereotactic biopsy is an established and safe method to acquire viable tissue from tumours anywhere in the brain, mostly from deep-seated or midline lesions [72]. Given that there is an increasing number of therapies directed against individual tumour targets, there may evolve a need for repetitive tissue-based analysis along the disease course [7]. Tissue sampling from multiple metastases might allow to assess a presumed molecular heterogeneity of signaling pathway deregulations which might be targetable. It will be crucial that image guided tumour sampling techniques are reliably implemented at large oncological institutions given the need for tumour tissue facilitating repetitive in-depth molecular analysis. Correlation of such tumour findings with circulating biomarkers (refer to 'liquid biopsies' paragraph) may eventually allow for less-invasive continuous monitoring of disseminated oncological disease including involvement of the CNS [73]. Given that biopsies might be accompanied by risks such as infection or, rarely, seeding of tumour cells, meticulous surgical techniques are necessary for avoidance [74,75].

6. Leptomeningeal dissemination

Involvement of the subarachnoid space and leptomeninges by solid extracranial tumours occurs in 5–8% of metastatic cancer patients and is denoted by the term 'leptomeningeal metastasis' [76]. Although thought of as a relatively rare event, leptomeningeal dissemination identifies a patient population with a devastating median overall survival of only few months [77]. Given this generally poor prognosis, the decision to pursue anti-tumour therapy must be discussed considering clinical performance score, systemic disease

status, and patient preference. [78] The major treatment modalities include intrathecal pharmacotherapy, systemic pharmacotherapy, and focal radiotherapy [76]. There is renewed interest in intrathecal chemotherapy after the positive trial for liposomal cytarabine, a drug currently no longer manufactured, in leptomeningeal metastasis from breast cancer [79], and disease characteristics defined in the EANO ESMO guidelines may help to identify patients most likely to benefit from intrathecal therapy [76,80]. Moreover, immunotherapy may represent a promising therapeutic avenue in leptomeningeal dissemination from solid malignancies [81]. Targeted therapies may also achieve considerable clinical response in selected cases of leptomeningeal metastases (positive for targetable molecular alterations in key oncogenic drivers like EGFR, ALK, BRAF, or HER-2) [82,83]; however, also these approaches warrant prospective evaluation.

6.1. Ventricular reservoir placement

Neurosurgical placement of a ventricular reservoir can be considered for patients with leptomeningeal dissemination with positive cerebrospinal fluid (CSF) cytology who are candidates for tumour-specific intrathecal treatment. Pharmacotherapy administered through a ventricular reservoir has been shown to be superior to lumbar puncture in terms of homogeneous drug distribution, accuracy of injections into the subarachnoid space, and, based on these factors, potentially also survival [84]. Procedural risk of neurosurgical reservoir placement is low and mainly limited to infections and haemorrhages [84]; however, neurotoxicity from intrathecal chemotherapy may be encountered with specific drugs such as methotrexate and may reduce quality of life [41,77]. New agents, including immunotherapy, are currently explored in this setting. In perspective, repetitive CSF analyses may also be helpful for monitoring the evolution of cancer metastatic to the CNS under therapeutic pressure [85].

6.2. Ventriculo-peritoneal shunting

Up to two third of patients with leptomeningeal dissemination may present with abnormal CSF flow on radionuclide studies caused by dissemination of metastatic cells into Virchow-Robin spaces resulting in impaired CSF resorption, tumour adhesions obstructing CSF passage, or a combination of these mechanisms [86,87]. Cerebrospinal fluid flow abnormalities, depending on the severity of the flow reduction, may translate into hydrocephalic symptoms, and are also associated with increased risk of intrathecal therapy-related toxicities given inhomogeneous intraventricular drug distribution, and less favorable survival. Accordingly, ventriculo-peritoneal shunting does not only alleviate symptoms attributed to hydrocephalus in

approximately 80–90% of such patients [88–91], but has even been linked to improved overall survival after the diagnosis of leptomeningeal dissemination has been established [92], potentially by facilitating further tumour-specific interventions. Although there has been concern that metastatic cells within the CSF may increase the risk for obstructive shunt malfunction, Omuro *et al.* [90] reported on a cohort of 37 patients with leptomeningeal dissemination and only three patients experienced shunt malfunction. Median overall survival after shunt placement was highly limited in this study with only 2 months, but it remains to be noted that the majority of shunts remained functional throughout the patients' lifetimes.

Brain metastases patients may also present with hydrocephalus in the absence of leptomeningeal dissemination (e.g. in the setting of posterior fossa disease and obstructive hydrocephalus). Nigim *et al.* [89] characterized a cohort of 59 brain metastases patients (37% of patients with leptomeningeal dissemination) and found a symptom relief rate of 93% with only one single case of shunt obstruction. Mean overall survival after shunt implantation was 6.4 months, and at twelve-month follow-up 87% of the ventriculo-peritoneal shunts in the patients alive seemed to sufficiently drain CSF. Technical advances such as neuronavigation and associated guidance systems, ultrasonography, or endoscopy may help to achieve optimal intracranial catheter positioning [93], and therefore may decrease the risk of shunt failure [94]. Intrathecal treatment is not recommended in patients with symptomatic hydrocephalus who require a ventriculo-peritoneal shunt. However, ventriculo-peritoneal shunts with on-off valves have been found to reliably allow the intraventricular administration of therapeutics without compromising shunt efficacy [95]. Ventriculo-peritoneal shunting bears a procedural morbidity of about 10% in patients with brain metastases (which is high compared to the mechanically less complex system of reservoir placement only) [89]. Importantly, the high symptom control rate in patients in need of a shunting procedure justifies such an operation

even in this particularly frail cohort [89]. Peritoneal dissemination of malignant cells through the shunt system has also been described [96–98], but appears to be rare [90,99]. Taken together, ventriculo-peritoneal shunting might be a pivotal factor to neurosurgically improve quality of life and possibly survival in cancer patients with leptomeningeal dissemination.

7. Future perspectives

7.1. Window-of-opportunity trials

Apart from the clinical necessities described so far, surgical resection of brain metastases, in the setting of a clinical trial, may offer new, urgently needed pharmacodynamic information that will inform on the utility of systemically administered therapies. In 'window-of-opportunity' clinical trials the essential question as to whether a therapeutic reaches the brain metastasis at a sufficient concentration and whether there is enough of a biological impact to expect clinical efficacy may be answered [100]. Patients that are planned to undergo surgical of a metastasis can be enrolled in a such a trial where the therapeutic is given for days or hours before surgery and the subsequent surgical specimen is used to evaluate drug concentration and biological (Fig. 2). These assessments inform on whether the therapy can penetrate the blood–tumour barrier, and the extent of target coverage can be determined [100]. These evaluations may be complemented by molecular profiling of the tumour tissue to gather correlative information that will eventually guide treatment decisions for the administration of targeted agents [16]. Moreover, effects from novel treatments (such as combinations of immunotherapies) on the tumour microenvironment might be assessed. Importantly, such 'window-of-opportunity' studies can only be conducted when side effects of the administered pharmacotherapy are sufficiently known to not include toxicities that impact on the safety of for surgical interventions. An overview of completed and ongoing

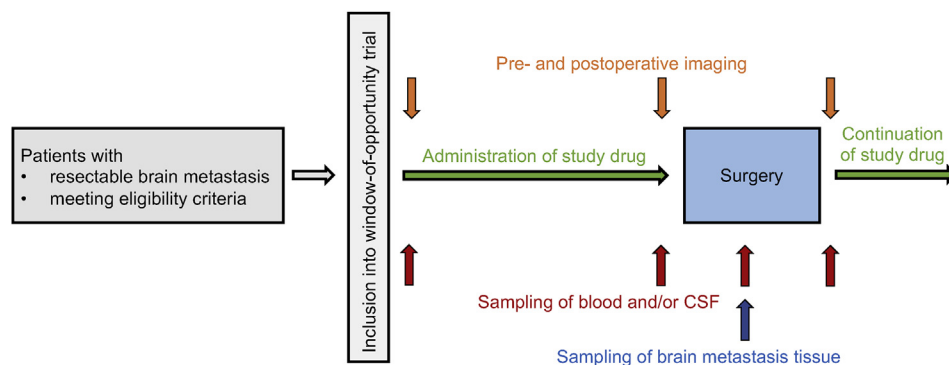


Fig. 2. **Window-of-opportunity trials.** Schematic depiction of the window-of-opportunity trial concept. Brain metastasis patients included in such trials receive a study drug for a pre-defined period of time prior to undergoing surgical brain metastasis resection. Adapted from Preusser *et al.* in ESMO Open, 2018.

Table 3

Selected window of opportunity studies for patients with brain metastases.

Studies	Tumour type, design, primary endpoint	Drug, dose and schedule prior to surgery, number of patients	Specimens and assessments	Results
Completed and published				
NCT00795678 Morikawa et al., 2015 [118]	BM from breast cancer requiring surgical resection phase 0 study determination of the concentration of capecitabine and lapatinib in BM	capecitabine (n = 8) HER2-: single pre-operative dose (1250 mg/m ²) 2–3 h before surgery lapatinib (n = 4) HER2+: 1250 mg daily for 2–5 days, last dose 2–3 h before surgery One HER2+ patient received capecitabine rather than lapatinib	BM tissue, CSF, blood lapatinib capecitabine and its prodrug metabolites: 5'-deoxy-5-fluorocytidine (5'-DFCR), 5'-deoxy-5-fluorouridine (5'-DFUR), and 5-FU concentration both measured by LC-MS/MS	capecitabine: median serum maximum concentration values: 9.16 μM for capecitabine, 19.0 μM for 5'-DFCR, 26.1 μM for 5'-DFUR, 1.53 μM for 5-FU. median BM concentrations (BM concentrations varied 15- to 150-fold): 0.81 μM for capecitabine, 1.52 μM for 5'-DFCR, 0.27 μM for 5'-DFUR, 1.81 μM for 5-FU. median BM-to-serum ratio: 0.28 for capecitabine, 0.36 for 5'-DFCR, 0.06 for 5'-DFUR, 5.64 for 5-FU lapatinib: serum lapatinib concentrations at the time of tumour resection, comparable average, ranging from 2.4 to 6.5 μM. BM concentrations: differed greatly, ranging from 1.0 μM to 63 μM. A strong correlation between the number of preoperative doses of lapatinib and BM drug concentration was noted. BM-to-serum ration: marked variation, ranging from 0.19 to 9.8, demonstrating that heterogeneity among tumours cannot be explained simply by serum exposure level.
NCT02308020 Tolaney et al., 2020 [119]	BM from breast cancer or NSCLC randomized phase 2 trial intracranial objective response rate to abemaciclib in patients with BM or leptomeningeal metastases (arm D: patients with surgical indication for BM)	abemaciclib 200 mg twice daily ≥1 abemaciclib dose 9 patients planned, 8 patients available with BM tissue, CSF and plasma	BM tissue, CSF, blood samples abemaciclib and its active metabolites LSN2839576 (M2) and LSN3106726 (M20) concentration measured by LC-MS/MS	average unbound ratio of abemaciclib, M2 and M20 between BM tissue and plasma concentrations of 5.6 (range, 0.6–14.0) average concentrations of 96-fold -(CDK4) and 19-fold (CDK6) above <i>in vitro</i> IC ₅₀
NCT01494662 Freedman et al., 2020 [120]	BM from HER2-positive breast cancer phase 2 trial, cohort 2: BM with surgical indication ability to administer neratinib before clinically recommended craniotomy in patients with HER2-positive breast cancer; determine neratinib concentrations in the CNS, post-operative neratinib maintenance	neratinib 240 mg orally once a day for 7 to 21 days preoperatively 5 patients enrolled, 1 with leptomeningeal metastasis; available for analysis: 1 BM tissue (8 sampling locations) without paired CSF or blood, 3 CSF samples, with paired blood samples in 2 cases	BM tissue, CSF, blood samples neratinib concentrations assessed by liquid chromatography-tandem mass spectrometry distribution in parenchymal brain tissue by spatially resolved surface sampling, mass spectrometry approach, with liquid extraction surface analysis ion trap MS	neratinib concentration: 46 to 532 ng/mL (approximately equivalent to 1–10x plasma level concentrations measured for other patients in this cohort) in the 3 CSF collected at the time of craniotomy, concentrations were below the limit of detection (<1.50 ng/mL), while the corresponding plasma concentrations for 2 of these patients were 34.3 and 53.8 ng/mL variable neratinib distribution between 46 and 533 ng/mL in BM samples, between 48 and 233 ng/mL in surrounding fibrous tissue
Completed or ongoing, not yet published (source ClinicalTrials.gov)				
NCT00837928 completed	non-CNS cancer with 1–4 BM phase 1 study recommended phase 2 dose of bendamustine combined with post-surgical fractionated stereotactic	bendamustine 40 mg/m ² i.v. on days 1, 2 and 3 prior to surgery; fractionated stereotactic radiotherapy within 4 weeks after	BM, brain margin, leptomeninges, CSF and plasma in patients undergoing surgery bendamustine hydrochloride drug quantification	not applicable

(continued on next page)

Table 3 (continued)

Studies	Tumour type, design, primary endpoint	Drug, dose and schedule prior to surgery, number of patients	Specimens and assessments	Results
	radiotherapy	surgery. 18 participants	utilizing high-performance LC-MS/MS	
NCT02015117 active, not recruiting	non-CNS cancer with measurable or evaluable BM phase 1 cohort B: to quantify trametinib in BM tissue	trametinib once daily (dose not specified) on days 1–14 before surgery 30 participants	BM, brain margin, leptomeninges, CSF trametinib drug quantification utilizing high-performance LC-MS/MS	not applicable
NCT02338037 active, not recruiting	BM resection or biopsy for differentiation between tumour progression versus treatment-induced effects following radiation therapy and/or chemotherapy early phase 1 determination of the neuropharmacokinetic profile of eribulin mesylate: time of maximum concentration observed for eribulin mesylate; maximum concentration of eribulin mesylate; area under the curve for eribulin mesylate; half-life for eribulin mesylate; ratio of area under the curve of eribulin mesylate in dialysate to plasma	eribulin mesylate tumour resection or biopsy and microdialysis catheter placed on day 0. At least 24 h later, eribulin mesylate i.v. over 2–5 min on day 1. Serial brain fluid samples collected for 72 h. 8 participants	dialysate, blood samples BM defined as tumour (enhancing tissue) and normal brain (non-enhancing tissue) when technically feasible to place two microdialysis catheters in a study patient eribulin mesylate pharmacokinetic data will be presented using descriptive statistics and graphical methods. method for assessment of concentration not provided	not applicable
NCT01978236 terminated due to the limited enrollment	BM from BRAF-mutant melanoma phase 2 concentrations of dabrafenib, its metabolites hydroxy-, carboxy- and desmethyl-dabrafenib in plasma, in BM and CSF (cohort A) concentrations of dabrafenib, its metabolites hydroxy-, carboxy- and desmethyl-dabrafenib trametinib in CSF (cohort B)	dabrafenib and combination of dabrafenib and trametinib cohort A (n = 6 enrolled/15 planned): dabrafenib 150 mg twice daily for 7 to 14 days prior to surgery cohort B (n = 0 enrolled/15 planned): dabrafenib 150 mg twice daily plus trametinib 2 mg once daily for 7 to 14 days prior to surgery ketoconazole orally once daily on days 1–4 before surgery (dose not specified) 19 participants	BM tissue, CSF, blood samples dabrafenib, its metabolites hydroxy-, carboxy- and desmethyl-dabrafenib drug concentration measured by LC-MS/MS spatial distribution in the tissue samples were determined using an investigative MALDI analysis method BM tissue, CSF, blood samples ketoconazole levels of ketoconazole in serum relative to enhancing brain tumour tissue and blood brain penetration of	BM concentration, range (ng/mL) (n = 6) dabrafenib: 0–124; hydroxy-dabrafenib: 0–261; carboxy-dabrafenib: 81–898; desmethyl-dabrafenib: 1–197 Plasma concentration, range (ng/mL) (n = 6) dabrafenib pre-surgery: 2.54–953; dabrafenib post-surgery: 1.24–137; desmethyl-dabrafenib pre-surgery: 150–1530; desmethyl-dabrafenib post-surgery: 79.1–1310; hydroxy-dabrafenib pre-surgery: 4.72–644; hydroxy-dabrafenib post-surgery: 1.5–197; carboxy-dabrafenib pre-surgery: 621–4580 carboxy-dabrafenib post-surgery: 127–2770 CSF: (n = 1) dabrafenib: 0; hydroxy-dabrafenib: 2.30; carboxy-dabrafenib: 2.26; desmethyl-dabrafenib: 36.9 (https://www.clinicaltrials.gov/ct2/show/NCT01978236?term=NCT01978236&draw=2&rank=1)
NCT03796273 recruiting	BM from breast cancer and glioma early phase 1 randomization between ketoconazole followed by surgery and standard surgery determination of alteration by ketoconazole of the			not applicable

Table 3 (continued)

Studies	Tumour type, design, primary endpoint	Drug, dose and schedule prior to surgery, number of patients	Specimens and assessments	Results
	tGLI1 activation signature consisting of 8 tGLI1-regulated genes (CD24, CD44, VEGF-A, VEGF-C, VEGFR2, TEM7, OCT-4, heparanase) in tGLI1-expressing brain tumour samples		ketoconazole in serum relative to CSF and serum relative to non-enhancing brain tissue (exploratory recurrent glioma patients only). measurement by mass spectroscopy	
NCT00547131 completed	secondary and exploratory objectives include pharmacokinetics of ketoconazole primary or metastatic brain tumour phase I determination of the feasibility of microdialysis for assessing the intracerebral distribution of temozolomide in patients with primary or metastatic brain tumours secondary outcome measures include systemic and intracerebral pharmacokinetic profile of temozolomide using a microdialysis catheter	temozolomide, at least 25 h but no more than 72 h after placement of the catheter, patients receive a single dose of oral temozolomide (dose unspecified) 12 participants	dialysate, blood samples temozolomide concentration measured by LC-MS/MS	not applicable

Abbreviations: BM: brain metastases; CDK: cyclin-dependent kinase, CNS: central nervous system; CSF: cerebrospinal fluid; LC-MS/MS: liquid chromatography tandem mass spectrometry; n: number; neg: negative; pos: positive; MALDI: matrix assisted laser desorption ionization; NSCLC, non-small cell lung cancer; 5'-DFCR: 5'-deoxy-5-fluorocytidine; 5'-DFUR: 5'-deoxy-5-fluorouridine.

clinical trials pursuing this approach is provided in [Table 3](#). Overall, such trials obviously face major logistic challenges, but constitute a so far underexplored opportunity to acquire a better understanding of how to develop active pharmacotherapies for patients with brain metastases. The design of such trials must carefully balance the intent to advance clinical science and the potential benefits for patients to consent to the study. An option to continue treatment on the tested drug after surgery commonly facilitates recruitment.

7.2. Local adjuvant therapy

Prior randomized trials have shown conclusively that there is a high risk of local tumour recurrence even after complete surgical resection on imaging unless WBRT [101] or radiosurgery [39] is used as an adjuvant. There has also been interest in the use of

intraoperative adjuvants for local control. Most efforts have focused on the use of local radiotherapy (brachytherapy) approaches, which has included the use of permanently implanted radioactive seeds [102], liquid brachytherapy within an implanted balloon [103], and intraoperative brachytherapy with a portable device [104]. Although these approaches may have shown success in terms of maintenance of local control, many have been associated with a higher risk of radiation-related complications than what has been reported for WBRT or radiosurgery. A more recently developed technology combines the use of cesium-131 radiation seeds with an implanted substrate that improves dosimetry [105]; how this will compare over time to more established techniques remains to be determined. Yet another technology which is increasingly used is MR-guided laser induced hyperthermia (LITT) to ablate abnormal tissue — frequently

metastases – for which different devices are available allowing precise thermometry [106]. The concept of local delivery of chemotherapy has also been explored but has not yet been subjected to an adequately powered, efficacy oriented clinical trial [107,108].

7.3. Liquid biopsies

A seemingly easily applicable surrogate for tumour tissue is a ‘liquid biopsy’. [73]. Liquid biopsy comprises several techniques to detect and analyse circulating cell-free tumour DNA (ctDNA), circulating tumour cells, circulating RNA (ctRNA), and tumour-derived exosomes in biofluids. For CNS malignancies, this most commonly occurs through CSF analysis; however, it has also been successfully demonstrated using plasma and urine samples.

DNA extracted from the CSF is enriched in ctDNA with a relative absence of genomic DNA [109]. However, the detection rate of genomic alterations in the CSF versus plasma has been reported as higher in the context of leptomeningeal metastases than in the context of brain metastases [110]. The identification of actionable mutations using CSF liquid biopsy may be used to guide subsequent therapy [111], and serial analysis has been shown to reflect molecular tumour changes, such as acquisition of resistance-associated EGFR^{T790M} or ERBB2/4 mutations in response to the administration of the respective targeted inhibitors [73,112]. Furthermore, ctDNA levels follow the changes in brain tumour burden, providing potential biomarkers to monitor brain malignancies [113]. However, the optimal use of liquid biopsies for diagnosis, monitoring, and guidance of treatment decisions has yet to be defined in prospective validation studies.

8. Conclusions

The role of neurosurgical care for brain metastases is evolving in the context of emerging personalized approaches to patients with cancer metastatic to the CNS. Surgical resection of brain metastases might be beneficial particularly for large tumours producing neurological symptoms or a requirement for steroids when immunotherapy is contemplated, and improved outcomes can be achieved utilizing novel surgical approaches. In addition, analysis of surgical tissue specimens may permit unique insights into the pharmacodynamics of pre-surgically administered therapeutic agents and represents one rationale to include surgery into clinical trial protocols. In patients with multiple brain metastases and mixed response to therapeutic agents or diagnostic uncertainty, repetitive tumour sampling may facilitate the understanding of escape mechanisms and the branched evolution of cancer. Ventriculo-peritoneal shunting may not only

substantially improve quality of life in patients with leptomeningeal dissemination but may also prolong overall survival by allowing for use of additional therapeutic options. Consideration of these neurosurgical approaches is essential to the highest quality of multidisciplinary care for patients with brain metastases.

Funding

This research did not receive any specific grant support from funding agencies in the public, commercial, or not-for-profit sectors.

Conflict of interest statement

The authors declare the following financial interests/personal relationships which may be considered as potential competing interests: **Philipp Karschnia** reports research grants from the ‘Support Program for Research and Teaching’ (FöFoLe) at the Ludwig-Maximilians-University Munich, the ‘Society for Research and Science of the LMU Faculty of Medicine’ (WiFoMed), the Friedrich Baur Foundation, and the ‘Familie Mehdorn’ Foundation. **Emilie Le Rhun** reports receiving honoraria for lectures or advisory board from AbbVie, Adastral, Daiichi Sankyo, LEO Pharma, Seagen, and Tocagen. **Michael Vogelbaum** reports indirect equity and patient royalty interests from Infuseon Therapeutics; honoraria from Celgene and Cellinta; and research grants from Celgene and Oncosynergy. **Martin van den Bent** reports consultant roles for Celgene, BMS, Agios, Boehringer, Abbvie, Bayer, Carthera, Nerviano, and Genenta. **Matthias Preusser** reports honoraria for lectures, consultation or advisory board participation from the following for-profit companies: Bayer, Bristol-Myers Squibb, Novartis, Gerson Lehrman Group (GLG), CMC Contrast, GlaxoSmithKline, Mundipharma, Roche, BMJ Journals, MedMedia, Astra Zeneca, AbbVie, Lilly, Medahead, Daiichi Sankyo, Sanofi, Merck Sharp & Dome, Tocagen, and Adastral. MP also reports supported clinical trials and contracted research conducted from the following for-profit companies with payments made to his institution: Böhlinger-Ingelheim, Bristol-Myers Squibb, Roche, Daiichi Sankyo, Merck Sharp & Dome, Novocure, GlaxoSmithKline, and AbbVie. **Michael Weller** reports research grants from Abbvie, Adastral, Merck, Sharp & Dohme (MSD), Merck (EMD), Novocure, Piquor, and Roche; honoraria for lectures or advisory board participation or consulting from Abbvie, Adastral, Basilea, Bristol Meyer Squibb (BMS), Celgene, Merck, Sharp & Dohme (MSD), Merck (EMD), Novocure, Orbus, Roche, Tocagen, and yMabs. **Joerg-Christian Tonn** reports consultant/speaker honoraria from BrainLab and Carthera and royalties from Springer Publisher Intl. Stefan

J. Grau, Riccardo Soffietti, Louisa von Baumgarten, and Manfred Westphal have no conflicts of interest.

Acknowledgments

The generous financial support of Dr. Dirk Ippen and Mrs. Marlene Ippen for bearing the publication charges is thankfully acknowledged. This research did not receive any further specific grant from funding agencies in the public, commercial, or not-for-profit sectors.

References

- [1] Achrol AS, Rennert RC, Anders C, et al. Brain metastases. *Nat Rev Dis Primers* 2019;5:5.
- [2] Larkin J, Chiarion-Sileni V, Gonzalez R, et al. Five-year survival with combined nivolumab and ipilimumab in advanced melanoma. *N Engl J Med* 2019;381:1535–46.
- [3] Hellmann MD, Paz-Ares L, Bernabe Caro R, et al. Nivolumab plus ipilimumab in advanced non-small-cell lung cancer. *N Engl J Med* 2019;381:2020–31.
- [4] Davis FG, Dolecek TA, McCarthy BJ, Villano JL. Toward determining the lifetime occurrence of metastatic brain tumors estimated from 2007 United States cancer incidence data. *Neuro Oncol* 2012;14:1171–7.
- [5] Goldberg SB, Schalper KA, Gettinger SN, et al. Pembrolizumab for management of patients with NSCLC and brain metastases: long-term results and biomarker analysis from a non-randomised, open-label, phase 2 trial. *Lancet Oncol* 2020;21:655–63.
- [6] Tomasini P, Barlesi F, Gilles S, et al. Comparative genomic analysis of primary tumors and paired brain metastases in lung cancer patients by whole exome sequencing: a pilot study. *Oncotarget* 2020;11:4648–54.
- [7] Brastianos PK, Carter SL, Santagata S, et al. Genomic characterization of brain metastases reveals branched evolution and potential therapeutic targets. *Cancer Discov* 2015;5:1164–77.
- [8] Fischer GM, Jalali A, Kircher DA, et al. Molecular profiling reveals unique immune and metabolic features of melanoma brain metastases. *Cancer Discov* 2019;9:628–45.
- [9] Jiang T, Yan Y, Zhou K, et al. Characterization of evolution trajectory and immune profiling of brain metastasis in lung adenocarcinoma. *NPJ Precis Oncol* 2021;5:6.
- [10] Morgan AJ, Giannoudis A, Palmieri C. The genomic landscape of breast cancer brain metastases: a systematic review. *Lancet Oncol* 2021;22:e7–17.
- [11] Alexander BM, Brown PD, Ahluwalia MS, et al. Clinical trial design for local therapies for brain metastases: a guideline by the Response Assessment in Neuro-Oncology Brain Metastases working group. *Lancet Oncol* 2018;19:e33–42.
- [12] Tawbi HA, Forsyth PA, Algazi A, et al. Combined nivolumab and ipilimumab in melanoma metastatic to the brain. *N Engl J Med* 2018;379:722–30.
- [13] Amaral T, Kiecker F, Schaefer S, et al. Combined immunotherapy with nivolumab and ipilimumab with and without local therapy in patients with melanoma brain metastasis: a DeCOG* study in 380 patients. *J Immunother Cancer* 2020;8.
- [14] Soffietti R, Abacioglu U, Baumert B, et al. Diagnosis and treatment of brain metastases from solid tumors: guidelines from the European Association of Neuro-Oncology (EANO). *Neuro Oncol* 2017;19:162–74.
- [15] Suh JH, Kotecha R, Chao ST, Ahluwalia MS, Sahgal A, Chang EL. Current approaches to the management of brain metastases. *Nat Rev Clin Oncol* 2020;17:279–99.
- [16] Soffietti R, Ahluwalia M, Lin N, Rudà R. Management of brain metastases according to molecular subtypes. *Nat Rev Neurol* 2020;16:557–74.
- [17] Riveiro-Falkenbach E, Villanueva CA, Garrido MC, et al. Intra- and inter-tumoral homogeneity of BRAF(V600E) mutations in melanoma tumors. *J Invest Dermatol* 2015;135:3078–85.
- [18] Berghoff AS, Bartsch R, Wöhrer A, et al. Predictive molecular markers in metastases to the central nervous system: recent advances and future avenues. *Acta Neuropathol* 2014;128:879–91.
- [19] Long GV, Atkinson V, Lo S, et al. Combination nivolumab and ipilimumab or nivolumab alone in melanoma brain metastases: a multicentre randomised phase 2 study. *Lancet Oncol* 2018;19:672–81.
- [20] Tawbi Hussein A, Forsyth Peter A, Hodi F Stephen, et al. Safety and efficacy of the combination of nivolumab plus ipilimumab in patients with melanoma and asymptomatic or symptomatic brain metastases (CheckMate 204). *Neuro Oncol* 2021:noab094. <https://doi.org/10.1093/neuonc/noab094>.
- [21] Maio M, Blank C, Necchi A, et al. Neoadjuvant immunotherapy is reshaping cancer management across multiple tumour types: the future is now! *Eur J Cancer* 2021;152:155–64.
- [22] Ramalingam SS, Vansteenkiste J, Planchard D, et al. Overall survival with osimertinib in untreated, EGFR-mutated advanced NSCLC. *N Engl J Med* 2020;382:41–50.
- [23] Rangachari D, Yamaguchi N, VanderLaan PA, et al. Brain metastases in patients with EGFR-mutated or ALK-rearranged non-small-cell lung cancers. *Lung Cancer* 2015;88:108–11.
- [24] Watase C, Shiino S, Shimoi T, et al. Breast cancer brain metastasis-overview of disease state, treatment options and future perspectives. *Cancers* 2021;13.
- [25] Duchnowska R, Dziadziuszko R, Trojanowski T, et al. Conversion of epidermal growth factor receptor 2 and hormone receptor expression in breast cancer metastases to the brain. *Breast Cancer Res* 2012;14:R119.
- [26] Pollock BE, Brown PD, Foote RL, Stafford SL, Schomberg PJ. Properly selected patients with multiple brain metastases may benefit from aggressive treatment of their intracranial disease. *J Neuro Oncol* 2003;61:73–80.
- [27] Kocher M, Soffietti R, Abacioglu U, et al. Adjuvant whole-brain radiotherapy versus observation after radiosurgery or surgical resection of one to three cerebral metastases: results of the EORTC 22952-26001 study. *J Clin Oncol* 2011;29:134–41.
- [28] Nieder C, Spanne O, Mehta MP, Grosu AL, Geinitz H. Presentation, patterns of care, and survival in patients with brain metastases: what has changed in the last 20 years? *Cancer* 2011;117:2505–12.
- [29] Kalkanis SN, Kondziolka D, Gaspar LE, et al. The role of surgical resection in the management of newly diagnosed brain metastases: a systematic review and evidence-based clinical practice guideline. *J Neuro Oncol* 2010;96:33–43.
- [30] Ammirati M, Nahed BV, Andrews D, Chen CC, Olson JJ. Congress of neurological surgeons systematic review and evidence-based guidelines on treatment options for adults with multiple metastatic brain tumors. *Neurosurgery* 2019;84:E180–e182.
- [31] Schödel P, Jünger ST, Wittersheim M, et al. Surgical resection of symptomatic brain metastases improves the clinical status and facilitates further treatment. *Cancer Med* 2020;9:7503–10.
- [32] Jünger ST, Schödel P, Ruess D, et al. Timing of development of symptomatic brain metastases from non-small cell lung cancer: impact on symptoms, treatment, and survival in the era of molecular treatments. *Cancers* 2020;12.
- [33] Schödel P, Schebesch KM, Brawanski A, Proescholdt MA. Surgical resection of brain metastases-impact on neurological outcome. *Int J Mol Sci* 2013;14:8708–18.
- [34] Gordon MS, Margolin K, Talpaz M, et al. Phase I safety and pharmacokinetic study of recombinant human anti-vascular

- endothelial growth factor in patients with advanced cancer. *J Clin Oncol* 2001;19:843–50.
- [35] Winter SF, Vaios EJ, Muzikansky A, et al. Defining treatment-related adverse effects in patients with glioma: distinctive features of pseudoprogression and treatment-induced necrosis. *Oncol* 2020;25. e1221-1232.
- [36] Karschnia P, Jordan JT, Forst DA, et al. Clinical presentation, management, and biomarkers of neurotoxicity after adoptive immunotherapy with CAR T cells. *Blood* 2019;133:2212–21.
- [37] Arbour KC, Mezquita L, Long N, et al. Impact of baseline steroids on efficacy of programmed cell death-1 and programmed death-ligand 1 blockade in patients with non-small-cell lung cancer. *J Clin Oncol* 2018;36:2872–8.
- [38] Yang HC, Kano H, Lunsford LD, Niranjan A, Flickinger JC, Kondziolka D. What factors predict the response of larger brain metastases to radiosurgery? *Neurosurgery* 2011;68:682–90. discussion 690.
- [39] Mahajan A, Ahmed S, McAleer MF, et al. Post-operative stereotactic radiosurgery versus observation for completely resected brain metastases: a single-centre, randomised, controlled, phase 3 trial. *Lancet Oncol* 2017;18:1040–8.
- [40] Brown PD, Jaeckle K, Ballman KV, et al. Effect of radiosurgery alone vs radiosurgery with whole brain radiation therapy on cognitive function in patients with 1 to 3 brain metastases: a randomized clinical trial. *Jama* 2016;316:401–9.
- [41] Karschnia P, Parsons MW, Dietrich J. Pharmacologic management of cognitive impairment induced by cancer therapy. *Lancet Oncol* 2019;20. e92-e102.
- [42] Pe M, Dorme L, Coens C, et al. Statistical analysis of patient-reported outcome data in randomised controlled trials of locally advanced and metastatic breast cancer: a systematic review. *Lancet Oncol* 2018;19. e459-e469.
- [43] Lin NU, Wefel JS, Lee EQ, et al. Challenges relating to solid tumour brain metastases in clinical trials, part 2: neurocognitive, neurological, and quality-of-life outcomes. A report from the RANO group. *Lancet Oncol* 2013;14:e407–416.
- [44] Soffietti R, Kocher M, Abacioglu UM, et al. A European Organisation for Research and Treatment of Cancer phase III trial of adjuvant whole-brain radiotherapy versus observation in patients with one to three brain metastases from solid tumors after surgical resection or radiosurgery: quality-of-life results. *J Clin Oncol* 2013;31:65–72.
- [45] Chang EL, Wefel JS, Hess KR, et al. Neurocognition in patients with brain metastases treated with radiosurgery or radiosurgery plus whole-brain irradiation: a randomised controlled trial. *Lancet Oncol* 2009;10:1037–44.
- [46] Berghoff AS, Rajky O, Winkler F, et al. Invasion patterns in brain metastases of solid cancers. *Neuro Oncol* 2013;15:1664–72.
- [47] Kamp MA, Rapp M, Bühner J, et al. Early postoperative magnet resonance tomography after resection of cerebral metastases. *Acta Neurochir* 2015;157:1573–80.
- [48] Kiesel B, Thomé CM, Weiss T, et al. Perioperative imaging in patients treated with resection of brain metastases: a survey by the European Association of Neuro-Oncology (EANO) Youngsters committee. *BMC Cancer* 2020;20:410.
- [49] Patel AJ, Suki D, Hatiboglu MA, et al. Factors influencing the risk of local recurrence after resection of a single brain metastasis. *J Neurosurg* 2010;113:181–9.
- [50] Suki D, Abouassi H, Patel AJ, Sawaya R, Weinberg JS, Groves MD. Comparative risk of leptomeningeal disease after resection or stereotactic radiosurgery for solid tumor metastasis to the posterior fossa. *J Neurosurg* 2008;108:248–57.
- [51] Suki D, Hatiboglu MA, Patel AJ, et al. Comparative risk of leptomeningeal dissemination of cancer after surgery or stereotactic radiosurgery for a single supratentorial solid tumor metastasis. *Neurosurgery* 2009;64:664–74. discussion 674-666.
- [52] Ahn JH, Lee SH, Kim S, et al. Risk for leptomeningeal seeding after resection for brain metastases: implication of tumor location with mode of resection. *J Neurosurg* 2012;116:984–93.
- [53] Patel AJ, Suki D, Hatiboglu MA, Rao VY, Fox BD, Sawaya R. Impact of surgical methodology on the complication rate and functional outcome of patients with a single brain metastasis. *J Neurosurg* 2015;122:1132–43.
- [54] Yoo H, Kim YZ, Nam BH, et al. Reduced local recurrence of a single brain metastasis through microscopic total resection. *J Neurosurg* 2009;110:730–6.
- [55] Jünger ST, Pennig L, Schödel P, et al. The debatable benefit of gross-total resection of brain metastases in a comprehensive treatment setting. *Cancers* 2021;13.
- [56] Sanmillan JL, Fernández-Coello A, Fernández-Conejero I, Plans G, Gabarrós A. Functional approach using intraoperative brain mapping and neurophysiological monitoring for the surgical treatment of brain metastases in the central region. *J Neurosurg* 2017;126:698–707.
- [57] Marbacher S, Klinger E, Schwyzer L, et al. Use of fluorescence to guide resection or biopsy of primary brain tumors and brain metastases. *Neurosurg Focus* 2014;36:E10.
- [58] Hussein A, Rohde V, Wolfert C, et al. Survival after resection of brain metastases with white light microscopy versus fluorescence-guidance: a matched cohort analysis of the Metastasis study data. *Oncotarget* 2020;11:3026–34.
- [59] Kamp MA, Munoz-Bendix C, Mijderwijk HJ, et al. Is 5-ALA fluorescence of cerebral metastases a prognostic factor for local recurrence and overall survival? *J Neuro Oncol* 2019;141: 547–53.
- [60] Marhold F, Mercea PA, Scheichel F, et al. Detailed analysis of 5-aminolevulinic acid induced fluorescence in different brain metastases at two specialized neurosurgical centers: experience in 157 cases. *J Neurosurg* 2019;1–12.
- [61] Karschnia P, Vogelbaum MA, van den Bent M, et al. Evidence-based recommendations on categories for extent of resection in diffuse glioma. *Eur J Cancer* 2021;149:23–33.
- [62] Schipmann S, Akalin E, Doods J, Ewelt C, Stummer W, Suero Molina E. When the infection hits the wound: matched case-control study in a neurosurgical patient collective including systematic literature review and risk factors analysis. *World Neurosurg* 2016;95:178–89.
- [63] Hoogman M, van de Beek D, Weisfelt M, de Gans J, Schmand B. Cognitive outcome in adults after bacterial meningitis. *J Neurol Neurosurg Psychiatry* 2007;78:1092–6.
- [64] Clark AJ, Butowski NA, Chang SM, et al. Impact of bevacizumab chemotherapy on craniotomy wound healing. *J Neurosurg* 2011;114:1609–16.
- [65] Krishnan KG, Müller A, Hong B, et al. Complex wound-healing problems in neurosurgical patients: risk factors, grading and treatment strategy. *Acta Neurochir* 2012;154:541–54.
- [66] Lin NU, Lee EQ, Aoyama H, et al. Response assessment criteria for brain metastases: proposal from the RANO group. *Lancet Oncol* 2015;16. e270-278.
- [67] Le Rhun E, Wolpert F, Fialek M, et al. Response assessment and outcome of combining immunotherapy and radiosurgery for brain metastasis from malignant melanoma. *ESMO Open* 2020; 5.
- [68] Okada H, Weller M, Huang R, et al. Immunotherapy response assessment in neuro-oncology: a report of the RANO working group. *Lancet Oncol* 2015;16:e534–42.
- [69] Galldiks N, Lohmann P, Albert NL, Tonn JC, Langen KJ. Current status of PET imaging in neuro-oncology. *Neurooncol Adv* 2019;1. vdz010.
- [70] Galldiks N, Kocher M, Cecon G, et al. Imaging challenges of immunotherapy and targeted therapy in patients with brain metastases: response, progression, and pseudoprogression. *Neuro Oncol* 2020;22:17–30.

- [71] Galldiks N, Abdulla DSY, Scheffler M, et al. Treatment monitoring of immunotherapy and targeted therapy using (18)F-FET PET in patients with melanoma and lung cancer brain metastases: initial experiences. *J Nucl Med* 2021;62:464–70.
- [72] Rachinger W, Grau S, Holtmannspötter M, Herms J, Tonn JC, Kreth FW. Serial stereotactic biopsy of brainstem lesions in adults improves diagnostic accuracy compared with MRI only. *J Neurol Neurosurg Psychiatry* 2009;80:1134–9.
- [73] Boire A, Brandsma D, Brastianos PK, et al. Liquid biopsy in central nervous system metastases: a RANO review and proposals for clinical applications. *Neuro Oncol* 2019;21:571–84.
- [74] Pinggera D, Kvitsaridze I, Stockhammer G, et al. Serious tumor seeding after brainstem biopsy and its treatment—a case report and review of the literature. *Acta Neurochir* 2017;159:751–4.
- [75] Karlsson B, Ericson K, Kihlström L, Grane P. Tumor seeding following stereotactic biopsy of brain metastases. Report of two cases. *J Neurosurg* 1997;87:327–30.
- [76] Le Rhun E, Weller M, Brandsma D, et al. EANO-ESMO Clinical Practice Guidelines for diagnosis, treatment and follow-up of patients with leptomeningeal metastasis from solid tumours. *Ann Oncol* 2017;28:iv84–99.
- [77] Beauchesne P. Intrathecal chemotherapy for treatment of leptomeningeal dissemination of metastatic tumours. *Lancet Oncol* 2010;11:871–9.
- [78] Le Rhun E, Preusser M, van den Bent M, Andratschke N, Weller M. How we treat patients with leptomeningeal metastases. *ESMO Open* 2019;4:e000507.
- [79] Le Rhun E, Wallet J, Mailliez A, et al. Intrathecal liposomal cytarabine plus systemic therapy versus systemic chemotherapy alone for newly diagnosed leptomeningeal metastasis from breast cancer. *Neuro Oncol* 2020;22:524–38.
- [80] Le Rhun E, Devos P, Weller J, et al. Prognostic validation and clinical implications of the EANO ESMO classification of leptomeningeal metastasis from solid tumors. *Neuro Oncol* 2021 Jul 1;23(7):1100–12. PMID: 33367859.
- [81] Brastianos PK, Lee EQ, Cohen JV, et al. Single-arm, open-label phase 2 trial of pembrolizumab in patients with leptomeningeal carcinomatosis. *Nat Med* 2020;26:1280–4.
- [82] Mizusaki S, Otsubo K, Ninomiya T, Arimura H, Tsuchiya-Kawano Y, Inoue K. Remarkable response to dacomitinib in a patient with leptomeningeal carcinomatosis due to EGFR-mutant non-small cell lung cancer. *Thorac Cancer* 2021;12:114–6.
- [83] Figura NB, Long W, Yu M, et al. Intrathecal trastuzumab in the management of HER2+ breast leptomeningeal disease: a single institution experience. *Breast Cancer Res Treat* 2018;169:391–6.
- [84] Montes de Oca Delgado M, Cacho Diaz B, Santos Zambrano J, et al. The comparative treatment of intraventricular chemotherapy by ommaya reservoir vs. Lumbar puncture in patients with leptomeningeal carcinomatosis. *Front Oncol* 2018;8:509.
- [85] Seoane J, De Mattos-Arruda L, Le Rhun E, Bardelli A, Weller M. Cerebrospinal fluid cell-free tumour DNA as a liquid biopsy for primary brain tumours and central nervous system metastases. *Ann Oncol* 2019;30:211–8.
- [86] Mason WP, Yeh SD, DeAngelis LM. 111Indium-diethylenetriamine pentaacetic acid cerebrospinal fluid flow studies predict distribution of intrathecally administered chemotherapy and outcome in patients with leptomeningeal metastases. *Neurology* 1998;50:438–44.
- [87] Chamberlain MC, Kormanik PA. Prognostic significance of 111indium-DTPA CSF flow studies in leptomeningeal metastases. *Neurology* 1996;46:1674–7.
- [88] Lee SH, Kong DS, Seol HJ, Nam DH, Lee JI. Ventriculoperitoneal shunt for hydrocephalus caused by central nervous system metastasis. *J Neuro Oncol* 2011;104:545–51.
- [89] Nigim F, Critchlow JF, Kasper EM. Role of ventriculoperitoneal shunting in patients with neoplasms of the central nervous system: an analysis of 59 cases. *Mol Clin Oncol* 2015;3:1381–6.
- [90] Omuro AM, Lallana EC, Bilsky MH, DeAngelis LM. Ventriculoperitoneal shunt in patients with leptomeningeal metastasis. *Neurology* 2005;64:1625–7.
- [91] Karschnia P, Barbiero FJ, Schwaiblmair MH, et al. Leptomeningeal dissemination of low-grade neuroepithelial CNS tumors in adults: a 15-year experience. *Neurooncol Pract* 2020;7:118–26.
- [92] Kim HS, Park JB, Gwak HS, Kwon JW, Shin SH, Yoo H. Clinical outcome of cerebrospinal fluid shunts in patients with leptomeningeal carcinomatosis. *World J Surg Oncol* 2019;17:59.
- [93] Thomale UW, Schaumann A, Stockhammer F, et al. GAVCA study: randomized, multicenter trial to evaluate the quality of ventricular catheter placement with a mobile health assisted guidance technique. *Neurosurgery* 2018;83:252–62.
- [94] Whitehead WE, Riva-Cambrin J, Kulkarni AV, et al. Ventricular catheter entry site and not catheter tip location predicts shunt survival: a secondary analysis of 3 large pediatric hydrocephalus studies. *J Neurosurg Pediatr* 2017;19:157–67.
- [95] Lin N, Dunn IF, Glantz M, et al. Benefit of ventriculoperitoneal cerebrospinal fluid shunting and intrathecal chemotherapy in neoplastic meningitis: a retrospective, case-controlled study. *J Neurosurg* 2011;115:730–6.
- [96] Narayan A, Jallo G, Huisman TA. Extracranial, peritoneal seeding of primary malignant brain tumors through ventriculoperitoneal shunts in children: case report and review of the literature. *NeuroRadiol J* 2015;28:536–9.
- [97] Rickert CH. Abdominal metastases of pediatric brain tumors via ventriculoperitoneal shunts. *Childs Nerv Syst* 1998;14:10–4.
- [98] Jamjoom ZA, Jamjoom AB, Sulaiman AH, Naim Ur R, al Rabiaa A. Systemic metastasis of medulloblastoma through ventriculoperitoneal shunt: report of a case and critical analysis of the literature. *Surg Neurol* 1993;40:403–10.
- [99] Gonda DD, Kim TE, Warnke PC, Kasper EM, Carter BS, Chen CC. Ventriculoperitoneal shunting versus endoscopic third ventriculostomy in the treatment of patients with hydrocephalus related to metastasis. *Surg Neurol Int* 2012;3:97.
- [100] Vogelbaum MA, Krivosheya D, Borghesi-Razavi H, et al. Phase 0 and window of opportunity clinical trial design in neuro-oncology: a RANO review. *Neuro Oncol* 2020 Nov 26;22(11):1568–79. PMID: 32598442.
- [101] Patchell RA, Tibbs PA, Regine WF, et al. Postoperative radiotherapy in the treatment of single metastases to the brain: a randomized trial. *Jama* 1998;280:1485–9.
- [102] Huang K, Sneed PK, Kunwar S, et al. Surgical resection and permanent iodine-125 brachytherapy for brain metastases. *J Neuro Oncol* 2009;91:83–93.
- [103] Rogers LR, Rock JP, Sills AK, et al. Results of a phase II trial of the GliaSite radiation therapy system for the treatment of newly diagnosed, resected single brain metastases. *J Neurosurg* 2006;105:375–84.
- [104] Weil RJ, Mavinkurve GG, Chao ST, et al. Intraoperative radiotherapy to treat newly diagnosed solitary brain metastasis: initial experience and long-term outcomes. *J Neurosurg* 2015;122:825–32.
- [105] Nakaji P, Smith K, Youssef E, et al. Resection and surgically targeted radiation therapy for the treatment of larger recurrent or newly diagnosed brain metastasis: results from a prospective trial. *Cureus* 2020;12:e11570.
- [106] Bastos DCA, Fuentes DT, Traylor J, et al. The use of laser interstitial thermal therapy in the treatment of brain metastases: a literature review. *Int J Hyperthermia* 2020;37:53–60.
- [107] Ene CI, Nerva JD, Morton RP, et al. Safety and efficacy of carmustine (BCNU) wafers for metastatic brain tumors. *Surg Neurol Int* 2016;7:S295–9.
- [108] Mu F, Lucas Jr JT, Watts JM, et al. Tumor resection with carmustine wafer placement as salvage therapy after local failure

- of radiosurgery for brain metastasis. *J Clin Neurosci* 2015;22:561–5.
- [109] Pentsova EI, Shah RH, Tang J, et al. Evaluating cancer of the central nervous system through next-generation sequencing of cerebrospinal fluid. *J Clin Oncol* 2016;34:2404–15.
- [110] Huang R, Xu X, Li D, et al. Digital PCR-based detection of EGFR mutations in paired plasma and CSF samples of lung adenocarcinoma patients with central nervous system metastases. *Target Oncol* 2019;14:343–50.
- [111] von Baumgarten L, Kumbrink J, Jung A, et al. Therapeutic management of neuro-oncologic patients - potential relevance of CSF liquid biopsy. *Theranostics* 2020;10:856–66.
- [112] Mattox AK, Yan H, Bettgowda C. The potential of cerebrospinal fluid-based liquid biopsy approaches in CNS tumors. *Neuro Oncol* 2019;21:1509–18.
- [113] De Mattos-Arruda L, Mayor R, Ng CKY, et al. Cerebrospinal fluid-derived circulating tumour DNA better represents the genomic alterations of brain tumours than plasma. *Nat Commun* 2015;6:8839.
- [114] Iuchi T, Shingyoji M, Itakura M, et al. Frequency of brain metastases in non-small-cell lung cancer, and their association with epidermal growth factor receptor mutations. *Int J Clin Oncol* 2015;20:674–9.
- [115] Nicoś M, Jarosz B, Krawczyk P, et al. Screening for ALK abnormalities in central nervous system metastases of non-small-cell lung cancer. *Brain Pathol* 2018;28:77–86.
- [116] Arvold ND, Oh KS, Niemierko A, et al. Brain metastases after breast-conserving therapy and systemic therapy: incidence and characteristics by biologic subtype. *Breast Cancer Res Treat* 2012;136:153–60.
- [117] Carlino MS, Haydu LE, Kakavand H, et al. Correlation of BRAF and NRAS mutation status with outcome, site of distant metastasis and response to chemotherapy in metastatic melanoma. *Br J Cancer* 2014;111:292–9.
- [118] Morikawa A, Peereboom DM, Thorsheim HR, et al. Capecitabine and lapatinib uptake in surgically resected brain metastases from metastatic breast cancer patients: a prospective study. *Neuro Oncol* 2015;17:289–95.
- [119] Tolaney SM, Sahebjam S, Le Rhun E, et al. A phase II study of abemaciclib in patients with brain metastases secondary to hormone receptor-positive breast cancer. *Clin Cancer Res* 2020;26:5310–9.
- [120] Freedman RA, Gelman RS, Agar NYR, et al. Pre- and post-operative neratinib for HER2-positive breast cancer brain metastases: translational breast cancer research consortium 022. *Clin Breast Cancer* 2020;20:145–51. e142.