



HAL
open science

Unicortical Calvarial Autologous Bone Graft Harvest.

Romain Nicot, Matthias Schlund, S. Touzet-Roumazeille, Joel Ferri, Gwénaél Raoul

► **To cite this version:**

Romain Nicot, Matthias Schlund, S. Touzet-Roumazeille, Joel Ferri, Gwénaél Raoul. Unicortical Calvarial Autologous Bone Graft Harvest.. Plastic and Reconstructive Surgery, Global Open, 2020, Plastic and Reconstructive Surgery, Global Open, 8 (11), pp.e3241. 10.1097/GOX.0000000000003241 . hal-04102484

HAL Id: hal-04102484

<https://hal.univ-lille.fr/hal-04102484v1>

Submitted on 22 May 2023

HAL is a multi-disciplinary open access archive for the deposit and dissemination of scientific research documents, whether they are published or not. The documents may come from teaching and research institutions in France or abroad, or from public or private research centers.

L'archive ouverte pluridisciplinaire **HAL**, est destinée au dépôt et à la diffusion de documents scientifiques de niveau recherche, publiés ou non, émanant des établissements d'enseignement et de recherche français ou étrangers, des laboratoires publics ou privés.



Distributed under a Creative Commons Attribution 4.0 International License

Unicortical Calvarial Autologous Bone Graft Harvest

Romain Nicot, MD, MSc; Matthias Schlund, MD, MSc; Sandrine Touzet-Roumazeille, MD, MSc; Joël Ferri, MD, PhD; Gwénaél Raoul, MD, PhD

Facial reconstructive surgery includes many treatment options to replace bone structures. Each of them is dependent on the size and location of the bone defect, the technical contraindications to one of the surgical options, the quality of surrounding tissues, and further associated treatments such as radiation therapy.

There is a clear tendency toward vascularized bone reconstruction when faced with a large bone defect or when radiation therapy is planned. When less bone is required, when soft tissues trophicity allows it, and in the absence of pre/postoperative radiotherapy, autogenous bone grafts are preferred. Alternatives to bone free flaps and autogenous bone grafts exist, and several patient-specific implants have been described, consisting of titanium, poly-ether-ether-ketone, porous polyethylene, or vitroceraamics. Nevertheless, autogenous bone is still considered the gold standard in reconstructive surgery. It is easy to handle, thermostable, radio-transparent, less prone to infections, and easily adaptable. However, due to biological reasons, some of the autogenous bone implants can fail because of infection or resorption. Moreover, it is difficult to create an adequate anatomical shape with free-hand autologous bone grafts, with the clinical results being completely operator-dependent.¹

Therefore, the reconstructive surgeon must master the techniques of autologous bone graft. Multiple non-vascularized bone harvesting sites are possible, and each of them has advantages and disadvantages. Calvarial bone graft harvest can be uni- or bicortical. Unicortical calvarial bone graft presents a very good benefits-to-risks ratio. Firstly, in facial reconstruction, this harvesting site has the advantage of being located in the same operating field, facilitating installation of the patient. Secondly, membranous bone grafts, such as parietal graft, produce a higher bone density and undergo lower resorption than endochondral bone grafts in orofacial reconstruction. This difference could be explained partly by the earlier revascularization observed

in membranous bones.² Finally, unicortical calvarial bone harvesting caused no serious complications; the morbidity of the procedure is virtually absent in experienced hands.^{1,3} The most frequent patient complaint is depression at the donor site, which can be corrected through the use of an alloplastic filling, such as the biomaterial BCP.⁴ There is no significant post-operative pain, as often experienced with the mandibular, iliac crest, or costal grafts.^{1,3}

While many surgeons perform bicortical calvarial bone harvesting, we present herein our surgical protocol involving a unicortical calvarial bone harvesting to reduce the surgical morbidity. Technical aspects of the surgical procedure contribute to the high success rate of bone grafts. (See [Video \[online\]](#), which displays autologous calvarial bone graft harvest.) Calvarial bone harvesting is performed under general anesthesia, with the patient in a supine position, and the patient's head is bent forward and turned to the contralateral side of the donor site. The hair is combed to facilitate the performance of incision. Unicortical calvarial bone is usually harvested from the posterior parietal area. The surgical procedure begins with a scalp incision going directly to the parietal bone. Incision is performed slightly archwise, 2 cm away from the midline, to avoid sagittal venous sinus injury. The periosteum is then elevated to expose the parietal bone. Bleeding arterioles are electrocoagulated at the periosteal level to avoid alopecia.

A small round cutting burr or a piezotome is used to cut the external table down to the diploe. The first bone sample is cut in a small trapezoid form about 1 cm in length. Once harvested, using the periosteal elevator as a lever, the surgeon can confirm that the harvest stays monocortical, and no dura mater injury was performed. The continuation of bone harvesting is performed according to a trapezoid form. Multiple small samples should be preferred to a unitary large sample to avoid sample fracture. A bone chisel is used to cut through the diploic to harvest the samples. Several bone pieces can be obtained.

The donor site is filled in with biphasic calcium phosphate (BCP), a synthetic calcium phosphate ceramic: a measure of BCP is mixed with iliac crest bone marrow harvest. The mixture is placed in the depression created by the bone harvest. The periosteum is then tightly closed to cover the BCP, and the surgical site is hermetically closed on a suction drain removed 1 day after. Osseosconduction and osseointegration characteristics

From the Department of Oral and Maxillofacial Surgery, CHU Lille, University of Lille, Lille, France.

Received for publication August 28, 2020; accepted September 11, 2020.

Copyright © 2020 The Authors. Published by Wolters Kluwer Health, Inc. on behalf of The American Society of Plastic Surgeons. This is an open-access article distributed under the terms of the Creative Commons Attribution-Non Commercial-No Derivatives License 4.0 (CCBY-NC-ND), where it is permissible to download and share the work provided it is properly cited. The work cannot be changed in any way or used commercially without permission from the journal.

Plast Reconstr Surg Glob Open 2020;8:e3241; doi: 10.1097/GOX.0000000000003241; Published online 24 November 2020.

Disclosure: The authors have no financial interest to declare in relation to the content of this article.

Related Digital Media are available in the full-text version of the article on www.PRSGlobalOpen.com.

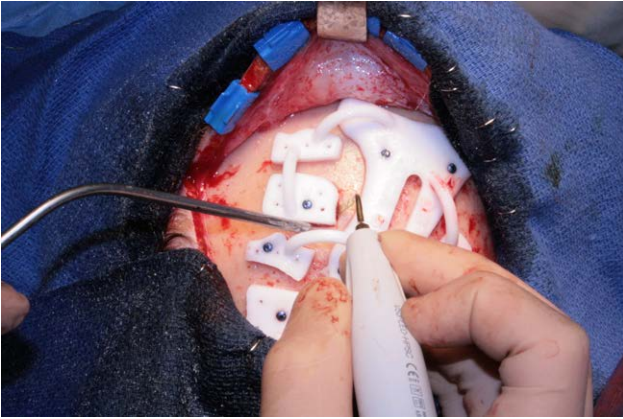


Fig. 1. Monocortical autologous calvarial bone graft harvest using CAD-CAM cutting guide (Materialise, Leuven, Belgium). Harvesting is started using a piezotome through a polyamide cutting guide. Cutting guide included drill holes to get a better stability.

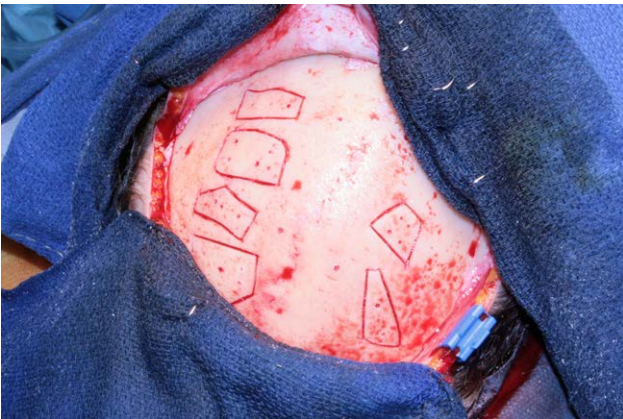

Fig. 2. After drawing the shape of the bone grafts, the cutting guide is removed and the calvarial bone graft harvest can be performed as usual.

of BCP lead to osseous colonization of the donor site,⁴ producing a new outer table and improving the biomechanical characteristics of the dome of the skull within 6 months and 1 year. This osseous colonization helps avoid having a disgraceful scar, with depressed feeling. Restoration of the calvarial donor site decreases the constraints on the donor site.

Concomitantly to bone plates' harvesting, bone chips of diploic cancellous bone are harvested using a bone scraper. They will be used to fill the dead space between the cortical bone plates and the grafted site, preventing fibrous tissue from developing between the bone plate and the grafted site and enhancing the bone graft stability.⁵

The main difficulty in the use of parietal bone graft in facial reconstruction is to shape the graft to obtain a desired three-dimensional (3D) form. There is a general consensus that computer-aided virtual planning allows more predictable results and is therefore becoming indispensable in reconstructive surgery.⁶ Specific cutting guides and a 3D surgical plan of ideal shape and ideal position

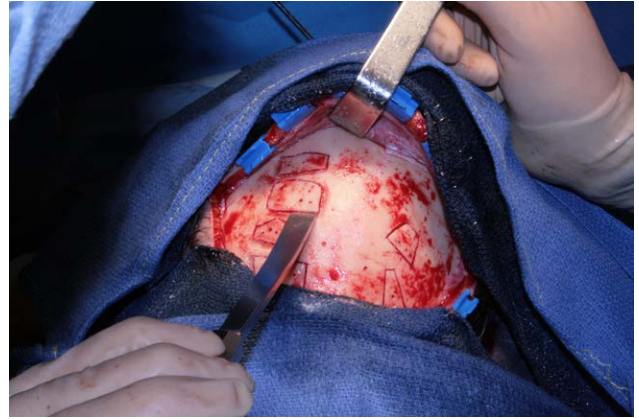


Fig. 3. A bone chisel is used to cut through the diploic to harvest the samples. Several preshaped bone pieces can be obtained.

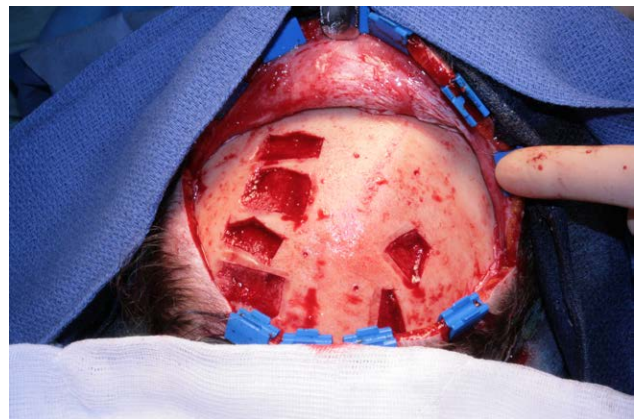

Fig. 4. Calvarial donor-site is filled with BCP. A measure of BCP is mixed with iliac crest bone marrow harvest. The mixture will be placed in the depression created by the bone harvest.

of the calvarial bony plates can be used to optimize the reconstructive results.⁷

Thereby, osteotomies were performed using a piezosurgical device through the polyamide calvarial cutting guide to obtain the previously designed shape (Fig. 1). Once the pre-shaped form has been contoured, the device is removed and the harvest can be performed according to the previous surgical procedure (Figs. 2–4).

The specific difficulty of performing the harvest in a unicortical way is that the size of bone plates is limited: the larger the size of the sample, the greater the risk of fracturing it. That is the reason why many authors harvest in full thickness.

Calvarial bone grafting is an effective therapeutic option in reconstructive surgery. A unicortical bone harvest is a safe procedure for obtaining a large amount of autologous bone. Its results can be optimized by computer-aided design and computer-aided manufacturing.

Romain Nicot, MD, MSc

Service de Chirurgie Maxillo Faciale et Stomatologie Hôpital

Roger Salengro

Bd du Prof Emile Laine

59037 Lille

France

E-mail: romain.nicot@gmail.com

ACKNOWLEDGMENTS

CPP approval is not required for this research. This study was conducted in accordance with Helsinki declaration.

REFERENCES

1. Tessier P, Kawamoto H, Posnick J, et al. Complications of harvesting autogenous bone grafts: A group experience of 20,000 cases. *Plast Reconstr Surg*. 2005;116:72S–73S; discussion 92S–94S.
2. Zins JE, Whitaker LA. Membranous versus endochondral bone: Implications for craniofacial reconstruction. *Plast Reconstr Surg*. 1983;72:778–785.
3. Touzet S, Ferri J, Wojcik T, et al. Complications of calvarial bone harvesting for maxillofacial reconstructions. *J Craniofac Surg*. 2011;22:178–181.
4. Dengehem C, Ferri J, Gosset P, et al. Bicalcium phosphate filling-up after calvarial unicortical harvesting in maxillofacial surgery. *J Craniofac Surg*. 2011;22:2392–2397.
5. Depeyre A, Touzet-Roumazielle S, Lauwers L, et al. Retrospective evaluation of 211 patients with maxillofacial reconstruction using parietal bone graft for implants insertion. *J Craniomaxillofac Surg*. 2016;44:1162–1169.
6. Largo RD, Garvey PB. Updates in head and neck reconstruction. *Plast Reconstr Surg*. 2018;141:271e–285e.
7. Nicot R, Schlund M, Sentucq C, et al. A new orbito-zygomatic complex reconstruction technique using computer-aided design and manufacturing-assisted harvest of autologous calvarial bone in cases of orbito-zygomatic benign tumor. *J Oral Maxillofac Surg*. 2019;77:1082–1091.