



HAL
open science

Development of impression trays for treating infants with trisomy 21 before their deciduous teeth erupt

Joséphine Dobrenel, Caroline Delfosse, Feng Chai, Jerome Vandomme, Corentin Denis, Marion Dehurtevent

► To cite this version:

Joséphine Dobrenel, Caroline Delfosse, Feng Chai, Jerome Vandomme, Corentin Denis, et al.. Development of impression trays for treating infants with trisomy 21 before their deciduous teeth erupt. Journal of Prosthetic Dentistry, 2023, Journal of Prosthetic Dentistry, 10.1016/j.prosdent.2023.04.015 . hal-04190946

HAL Id: hal-04190946

<https://hal.univ-lille.fr/hal-04190946>

Submitted on 23 Apr 2024

HAL is a multi-disciplinary open access archive for the deposit and dissemination of scientific research documents, whether they are published or not. The documents may come from teaching and research institutions in France or abroad, or from public or private research centers.

L'archive ouverte pluridisciplinaire **HAL**, est destinée au dépôt et à la diffusion de documents scientifiques de niveau recherche, publiés ou non, émanant des établissements d'enseignement et de recherche français ou étrangers, des laboratoires publics ou privés.

DENTAL TECHNIQUE

Development of impression trays for treating infants with trisomy 21 before their deciduous teeth erupt

Joséphine Dobrenel, DDS, Caroline Delfosse, DDS, PhD, Feng Chai, DDS, PhD, Jérôme Vandomme, DDS, PhD, Corentin Denis, DDS, Marion Dehurtevent, DDS, PhD

ABSTRACT

The treatment of infants with trisomy 21 (TS21) with a myostimulation plate can improve their development and quality of life. The manufacture of these plates requires an accurate cast of the maxilla, and efficacy relies on their stability and retention. As such, the quality of the impression is a determining factor. The lack of commercially available stock trays for infants with TS21 creates difficulties, including inadequate impression quality and the risk of inhaling impression material. The present technique simplified impression making for infants with TS21 from 3 months of age to when their maxillary deciduous teeth erupt by using computer-aided design and computer-aided manufacturing (CAD-CAM) impression trays. Sixty-five stored gypsum maxillary casts from infants with TS21 that had been used to manufacture myostimulation plates were analyzed to select 4 differently sized representative casts for designing the impression trays. A CAD software program was used to digitally shape 4 sizes of the impression tray from the selected gypsum casts. Practitioners interested in this approach can download and export the standard tessellation language (STL) files using a quick response (QR) code. The impression trays should be manufactured with the stereolithography additive technique using biocompatible resin. This technique allows practitioners to make accurate maxilla impressions for infants with

TS21 by manufacturing their own impression trays using the free-access STL files rather than the cumbersome conventional method.

Trisomy 21 (TS21) is a genetic disease caused by an extra chromosome 21 and occurs in 1/700 live births.¹ Generalized hypotonicity of the tongue is a common orofacial pathology of TS21, resulting in a protruding tongue that rests on the lower lip, leading to sensory-motor dysfunction, malocclusion, and defective language development.² Castillo-Morales therapy with a palatal stimulation plate combined with massage improves the cranioventral orientation of the tongue and the activation of the upper lip muscles³ and must be started as early as possible after birth to be effective.^{4,5}

The process of manufacturing a palatal stimulation plate requires an impression of the maxilla. Conventionally, alginate impressions can be held in the fingers or in a prefabricated stock tray.^{4,5} Irreversible hydrocolloid is not used for impressions for infants with cleft palates as it increases the potential for the impression material to break away from the impression tray and cause airway obstruction.^{6,7} However, infants with TS21 do not have cleft palates, which minimizes this risk. However, commercially available stock trays for young infants, especially for infants with TS21, are not currently available. In 2012, Strobel-Schwarthoff and Hofmann developed special laboratory-manufactured trays for young patients with cleft lips and/or palates. However, the anterior maxilla of healthy infants with cleft palates are much larger and more irregular than those of infants with TS21 and such trays are thus not suitable for impression making for infants with TS21.⁸⁻¹¹ Intraoral scanning techniques have become popular and in many practices have replaced conventional impression techniques.^{12,13} However, intraoral scanners are not yet available to all practitioners. In addition, some limitations of intraoral scanning still need to be overcome, including complications from hypotonic musculature

associated with uncontrolled salivation in patients with TS21 and increased scan duration compared with infants without TS21.⁷ Therefore, conventional impression techniques have not yet been replaced.

Developing a series of laboratory-manufactured trays based on the stored casts of infants with TS21 or theoretical casts has been recommended to provide practitioners with impression trays of different sizes and thus enable them to deal with different clinical situations.¹⁴ However, such individual collections cannot be shared with other practitioners.

Impression trays designed to simplify the impression-making technique for infants with TS21 are required. Computer-aided design and computer-aided manufacturing (CAD-CAM) combined with the additive technique with medically approved sterilizable materials is ideal for such an application. This manufacturing strategy can also reduce material waste. Therefore, 65 stored gypsum maxillary edentulous casts of infants with TS21 (from 3 to 12 months of age) treated at the Department of Pediatric Dentistry of Lille University Hospital were analyzed. All were pretreatment casts that had been used to manufacture myostimulation plates. Four areas of interest were measured on each cast with calipers (6'', accuracy: 0.2 mm; Magnusson): medial sagittal, anterior frontal in the area of the canine prominence, posterior frontal in the area where the maxillary tuberosities were widest, and deepest area of the palate (Fig. 1).

The measurements of each area were ranked from the smallest to the largest to compute the quartiles of the 4 areas (Table 1). Four maxillary casts, which had the measured values of the 4 areas closest to those of 3 computed quartiles and the maximal value, were selected as representative of 4 sizes of infants with TS21 for the CAD of the impression trays (Fig. 2). The 4 selected gypsum casts were scanned with a 3D dental scanner (Dental Wings 7 series; Institut Straumann AG). The undercuts on the cast were filled with wax using a vertical-axis insertion

for straightforward access by the software program. A 0.5-mm spacer wax was positioned 5 mm from the vestibule and velopalatal joint, including the maxillary ridges and palate, to reduce bone relief that might interfere with the design of the impression tray. The tray was designed by using the "grid" tool in "partial design," with the setting thickness set at 1.5 mm, the offset at 0.5 mm, and the diameter of the perforations at 3 mm. A stabilization ridge was designed and positioned close to the ridge line and slightly more palatal to facilitate handling of the tray by the operator and to reinforce the tray. The preexisting broad-based tray handle design, selected from the database, was oriented and centered on the cast without interfering with the margin of the impression tray. A size label (T1, T2, T3, or T4) was engraved on each cast (Fig. 3).

The present technique used CAD-CAM impression trays to simplify impression making for infants with TS21 ranging from 3 months of age to when their maxillary deciduous teeth erupt.

TECHNIQUE

1. Download and export the standard tessellation language (STL) files of the impression trays using a quick response (QR) code (Fig. 4).
2. Manufacture by stereolithography with a 50- μ m layer thickness from an autoclavable biocompatible resin (Dental SG, Formlabs) designed for dental surgical guides or similar applications (Fig. 5). The manufacturing time required for the 4 trays on 1 platform was approximately 1 hour and 45 minutes (Form 2 3D printer, Formlabs).
3. Wash with isopropyl alcohol and then use an ultraviolet (UV) postprocessing treatment according to the instructions for the material used.

4. Remove the supporting pillars with cutting pliers and surface finish with a scalpel followed by an acrylic resin bur (H251ACR, Komet) for polishing and smoothing the tray (Fig. 6).

DISCUSSION

Dentists play a key role in the care of infants with TS21 from the first months of life by using a stimulation palatal plate.^{4,5} The manufacture of the stimulation palatal plate requires an accurate impression to create an accurately fitting palatal prosthesis (Fig. 7). The impression techniques described previously have relied on available materials and the dexterity of the operator, making it more art than science. Simplifying the method of making impressions for infants with TS21 will increase the comfort of both the operator and the patient.

A CAD-CAM infant-specific impression tray may improve the impression-making process for infants with TS21. The only currently available impression trays have been personal collections in the possession of a few practitioners, indicating a crucial lack of impression trays for infants with TS21. The inherent risks for patients and the limited access of all practitioners to individual collections means that this option may not be available. The present technique focused on simplifying the impression-making methodology for palatal prostheses using impression trays specifically designed for the maxilla of infants with TS21. The 4 sizes of impression trays were designed based on an analysis of the anatomic structures of 65 edentulous stored gypsum maxillary cast from infants with TS21. The selection of impression trays benefited from the experience of the providers who generated this large collection of stored casts (Department of Pediatric Dentistry, Lille University Hospital). The use of impression trays made it possible to control the amount of material used and, as such, the pressure applied to the tissues. The

centrally placed handle ensured that uniform pressure was applied to the tissues. These impression trays have no contraindications and can be used in other clinical indications where a maxillary cast for an infant is required.

From a practical point of view, any practitioner who has access to an additive 3D printer and biocompatible material (resin or metal) for printing can take advantage of free access to design data files of impression trays (protected by a Creative Commons License) to manufacture impression trays for their patients (Fig. 4). All practitioners can take advantage of these impression trays to treat more patients with TS21 more efficiently.

SUMMARY

The development and quality of life of infants with TS21 can be improved by early orofacial management with a myostimulation plate. The quality of plate manufacture relies to a large extent on the precision of the impression of the maxilla. A CAD-CAM workflow was developed to manufacture a series of 4 infant-specific impression trays of different sizes to make maxillary impressions for infants with TS21 ranging from 3 months of age to when their deciduous teeth erupt. Any practitioner can use this technique to make accurate impressions of the maxilla for infants with TS21 by manufacturing their own impression trays via free access to .STL files rather than using the cumbersome conventional method.

REFERENCES

1. Linz A, Urschitz MS, Bacher M, Brockmann PE, Buchenau W, Poets CF. Treatment of obstructive sleep apnea in infants with trisomy 21 using oral appliances. *Cleft Palate Craniofac J* 2013;50:648–54
2. Gross AM, Kellum GD, Franbz D, Michas K, Walker M, Foster M, et al. A longitudinal evaluation of the open mouth posture and maxillary arch width in children. *Angle Orthod* 1994;64:419–24.
3. Korbmacher H, Limbrock J, Kahl-Nieke B. Orofacial development in children with Down's syndrome 12 years after early intervention with a stimulating plate. *J Orofac Orthop*, 2004;65:60–73.
4. Korbmacher H, Limbrock J, Kahl-Nieke B. Long-term evaluation of orofacial function in children with Down syndrome after treatment with a stimulating plate according to Castillo Morales. *J Clin Pediatr Dent* 2006;30:325–8.
5. Javed F, Akram Z, Barillas AP, Kellesarian SV, Ahmed HB, Khan J, et al. Outcome of orthodontic palatal plate therapy for orofacial dysfunction in children with Down syndrome: A systematic review. *Orthod Craniofac Res* 2018;21:20–6.
6. Chandwani N, Nandan M, Jadhav G, Mansing Pawar A, Isaqali Karobari M, Marya A. Single visit rehabilitation of 12-day neonate with cleft palate using modified feeding spoon impression technique: A case report. *Clin Case Rep*. 2023;11(2):e7008.
7. Reddy S, Devasya A, Nidawani M. Oral molding plates a boon to cleft lip and cleft palate patients: a series of case reports and review. *I J Pre Clin Dent Res* 2014;1(1):31-358. Strobel-Schwarthoff K, Hofmann E. Individualized Erlanger KS-impression trays for infants with cleft lip and palate. *Cleft Palate Craniofac J* 2012;49:237–9.

9. Klingel D, Hohoff A, Kwiecien R, Wiechmann D, Stamm T. Growth of the hard palate in infants with Down syndrome compared with healthy infants—A retrospective case control study. *PLoS One* 2017;12:e0182728.
10. Kalaskar R, Bhaje P, Balasubramanian S, Kalaskar A. Effectiveness of the novel impression tray "clef tray" for infants with cleft lip and palate: A randomized controlled clinical trial. *J Korean Assoc Oral Maxillofac Surg* 2021;47:82–90.
11. Chate RA. A report on the hazards encountered when taking neonatal cleft palate impressions (1983-1992). *Br J Orthod* 1995;22:299–307.
12. Jacobson BN, RSW. Cleft lip and palate: The orthodontist's youngest patient. *Am J Orthod Dentofac Orthop* 1986;90:63–6.
13. Xepapadeas A, Weise C, Frank K, Spintzyk S, Poets F, Wiechers C, et al. Technical note on introducing a digital workflow for newborns with craniofacial anomalies based on intraoral scans - Part I: 3D printed and milled palatal stimulation plate for trisomy 21, *BMC Oral Health* 2020;20:20–8.
14. Lipp MJ, Lubit EC. An impression procedure for the neonatal patient with cleft palate. *Spec Care Dentist* 1988;8:224–7.

TABLES

Table 1. Quartiles and maximal values of the four measurement areas (mm)

	Zone 1	Zone 2	Zone 3	Zone 4
1st quartile	26.65	20.15	37.57	6.49
2nd quartile	28.13	21.43	38.51	6.99
3rd quartile	29.34	22.45	39.43	7.98
Maximal value	32.55	27.26	43.15	10.31

FIGURES

Figure 1. Four areas of interest. A, Medial sagittal. B, Anterior frontal in area of canine prominence. C, Posterior frontal in area where maxillary tuberosities widest. D, Deepest area of palate.

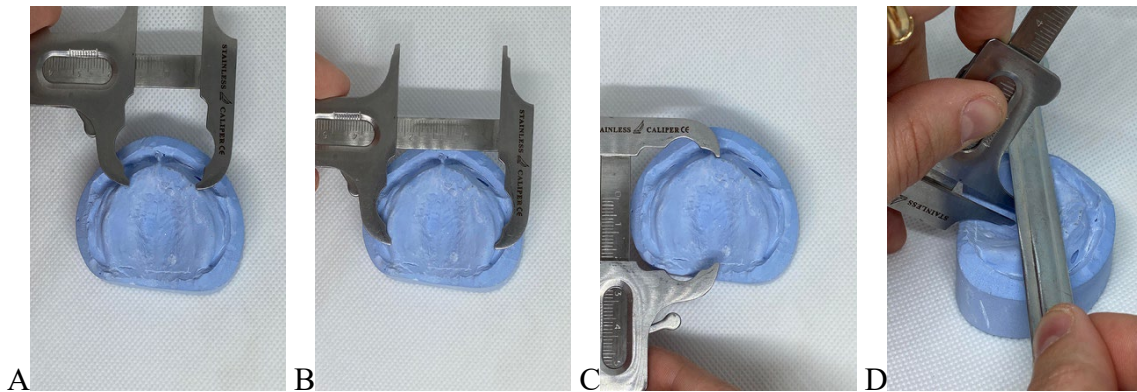


Figure 2. Gypsum casts selected to design TS21 infant-specific impression trays. From left to right, casts increase in size from T1 to T4.



Figure 3. A, B, Scans of gypsum cast before and after trimming with Dental Wings software program (Straumann). C, D, Intaglio and external surfaces of tray.

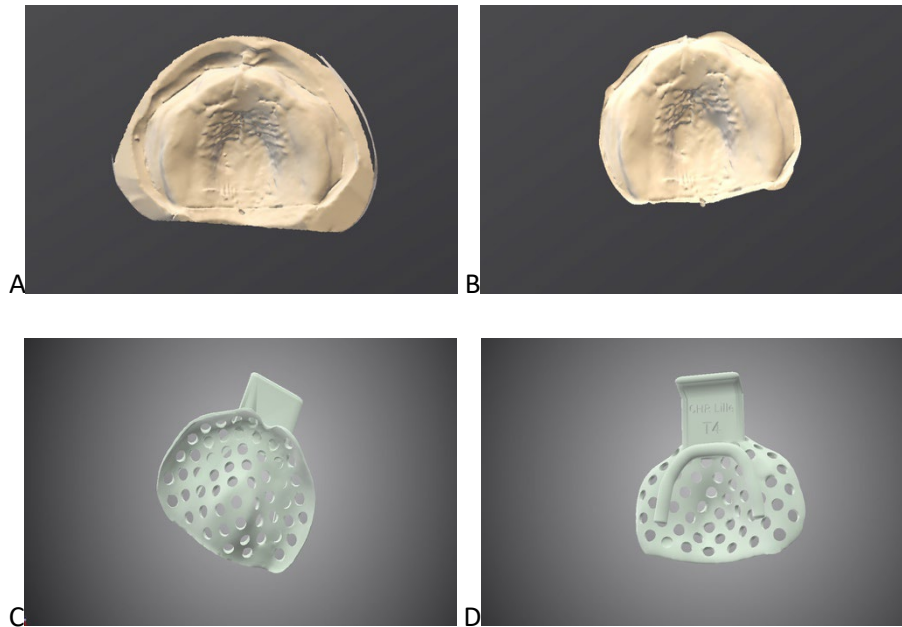


Figure 4. TS21 infant-specific impression trays of varying sizes. A, Size 1. B, Size 2. C, Size 3. D, Size 4.




Figure 5. Preparation for printing TS21 infant-specific impression trays using Preform software program (Formlabs).



Figure 6. Four 3D-printed impression trays fitted to their gypsum casts.



Figure 7. Myostimulation plate manufactured on size 3 cast.

