



HAL
open science

Management of symptomatic postoperative epidural hematoma in spine surgery: Medicolegal implications.

Henri-Arthur Leroy, T. Portella, Thomas Amouyel, R. Bougeard, Richard Assaker, K. L. Mourier

► To cite this version:

Henri-Arthur Leroy, T. Portella, Thomas Amouyel, R. Bougeard, Richard Assaker, et al.. Management of symptomatic postoperative epidural hematoma in spine surgery: Medicolegal implications.. Orthopaedics & Traumatology: Surgery & Research, 2021, Orthopaedics & Traumatology: Surgery & Research, pp.103024. 10.1016/j.otsr.2021.103024 . hal-04410250

HAL Id: hal-04410250

<https://hal.univ-lille.fr/hal-04410250>

Submitted on 22 Jul 2024

HAL is a multi-disciplinary open access archive for the deposit and dissemination of scientific research documents, whether they are published or not. The documents may come from teaching and research institutions in France or abroad, or from public or private research centers.

L'archive ouverte pluridisciplinaire **HAL**, est destinée au dépôt et à la diffusion de documents scientifiques de niveau recherche, publiés ou non, émanant des établissements d'enseignement et de recherche français ou étrangers, des laboratoires publics ou privés.



Distributed under a Creative Commons Attribution - NonCommercial 4.0 International License

Original article

Management of symptomatic postoperative epidural hematoma in spine surgery: medicolegal implications

Henri-Arthur **Leroy** ^{*a}, Thibault **Portella** ^b, Thomas **Amouyel** ^c, Renaud **Bougeard** ^d, Richard **Assaker** ^a, Klaus-Luc **Mourier** ^b

a Univ.Lille, CHU Lille, Département de Neurochirurgie, 1 rue Émile Laine, F-59000 Lille, France

b CHU Dijon, Département de Neurochirurgie, 14 rue Paul Gaffarel, F- 21000 Dijon, France

c Univ.Lille, CHU Lille, Département de Chirurgie orthopédique, 1 rue Émile Laine, F-59000 Lille, France

d Clinique du Val D'Ouest, Département de Neurochirurgie, 39 chemin de la Vernique, F- 69130 Écully, France

***Corresponding author:** Dr Henri-Arthur Leroy, Maître de Conférences des Universités – Praticien Hospitalier,

Université de Lille, CHU Lille, Département de Neurochirurgie, F-59000 Lille, France

Email: henriarthurleroy@gmail.com

Telephone: +33 3 20 44 54 55

Fax: +33 3 20 44 66 23

Abstract:

Introduction:

Spine surgery is one of the specialties with the highest medicolegal risk, with a legal action initiated every 17 months per practitioner. One of the most dreaded complications is an epidural hematoma with postoperative deficit. The treatment of this complication is still being debated. We therefore conducted a retrospective study of the database of a medical liability insurer to assess perioperative factors determining the liability of the surgeon or paramedical team during an expert review in the event of a postoperative symptomatic epidural hematoma.

Hypothesis:

To identify the factors determining the liability of the medical team in the event of a postoperative symptomatic epidural hematoma.

Materials and Methods:

We retrospectively analyzed the largest French register of medicolegal expert reviews between 2011 and 2018. We identified 68 cases by entering the following keywords in this database: “spine surgery,” “complications,” and “epidural hematoma.” After a thorough review of each case, only 14 were deemed to be truly relevant to our study. We collected for each patient the perioperative data, complications (including neurologic deficits) and their clinical course.

Results:

Only one surgeon was accused and found liable for failing to perform a surgical revision within a reasonable timeframe (time to revision of 11 days). In 2 cases, the liability of a nurse working in the surgical department was called into question for failing to contact the surgeon upon the onset of symptoms. In the other cases (11 patients, 79%), the occurrence of a symptomatic epidural hematoma was considered a no-fault medical accident that was not caused by the surgeon. The presence of a drain did not have any medicolegal impact in the cases reviewed.

Conclusion:

The key element in medicolegal decisions is the reaction time of the healthcare teams, in particular the time between the onset of symptoms and surgical revision. According to these expert reviews, the placement of a drain was not taken into consideration during the medicolegal assessment of a postoperative symptomatic epidural hematoma.

Level of Evidence: II; retrospective prognostic study, investigation of patient characteristics and their impact on functional outcome

Keywords: epidural hematoma; spine surgery, neurologic deficit, complications; expert review, medicolegal

1. Introduction

Spine surgery has a high medicolegal risk with, on average, one legal action initiated every 17 months per practitioner [1]. The specialty most at risk is neurosurgery with a 78% claims rate, followed by orthopedic surgeons and traumatologists with 69% [1][2][3]. These figures correspond to the claim frequency per 100 members in the same specialty over one year. For example, the average claims rate for all specialties combined was 1.01% in 2018. One of the most dreaded complications, given its potential medicolegal implications, is a postoperative epidural hematoma with neurologic deficits. Despite a very low incidence rate, ranging from 0.1 to 0.3%, it can result in very disabling functional outcomes for the patient, particularly in terms of motor, sensory, bladder and bowel dysfunctions[3-5].

A healthcare contract has bound patients and surgeons in France since the Mercier decision of 1936. This decision of the French *Cour de Cassation* defined fault-based medical liability when the obligation of means was not fulfilled. This has continued to evolve over the years. The last major reform dates back to 2002, with surgeons now having an obligation to prove that they gave clear, accurate and appropriate information to the patient. The Kouchner Act then specifies that the failure to provide information can lead to a prejudice indexed on the probability of avoiding the act. The number of medicolegal actions has been increasing over the past decades and practitioners are now required to guarantee that the information has been given to patients. Information leaflets have been written by learned societies for every pathology (ex: herniated disk repair, French Society of Spinal Surgery) and medical correspondence has become more and more comprehensive about the risks involved in the surgical procedures [6]. However, the French conciliation and compensation commissions (CCI) are increasingly being called upon to assess medical liability for events related to preoperative, intraoperative or postoperative care, whether or not they involved a complication. Medical liability refers to the obligation put on healthcare professionals to repair any damage caused by the poor fulfillment of a healthcare contract. A medical error is any action taken by the healthcare provider which led to the damage.

These court actions have impacted the practitioners daily practice and career planning [7].

It is in this context of increased medicolegal action, that we wanted to identify the risk factors of the legal involvement of healthcare teams faced with the potentially serious complication of a postoperative symptomatic epidural hematoma.

2. Materials and Methods

2.1 Patients

This was an observational retrospective study. We were able to access the case files of the largest French medicolegal register belonging to a private insurance company. This company provided professional civil liability cover for 487,144 members—natural persons in 2018. The queried register recorded 4,500 reported claims each year, i.e. 36,000 claims over the period under review (Figure 1). This private register is accessible upon request and approval by either the director or the owner of the insurance company. It is completely anonymized (no patient or practitioner identification).

2.2 Methods

After performing a keyword search in this database for “spine surgery,” “complications,” and “postoperative hematoma,” we identified 68 cases between 2011 and 2018 inclusive. After each case file was thoroughly reviewed, only 14 were retained as the others did not correspond exactly to a postoperative symptomatic epidural hematoma (Figure 1). The cervical, thoracic and lumbar regions were included.

2.3 Assessment methods

The following preoperative information was collected from each case file: patient history, age, body mass index, ongoing treatments, indication and type of surgery. We reviewed the operative reports to determine whether a surgical drain was placed or if there was an intraoperative dural tear. Finally, nursing records and postoperative consultation reports were examined for clinical signs of postoperative hematomas, modalities, diagnosis-to-treatment interval, and clinical recovery. The liability of the medical team was assessed with the expert review.

2.4 Statistics

Qualitative data were expressed as percentages and quantitative data as medians with their extreme values. No statistical tests were performed for this observational study.

3. Results

3.1 General demographics

Aggregate demographic data on the study population are reported in Table 1. Thirteen (93%) surgeries were performed for degenerative pathologies. One surgery was indicated for trauma: a thoracic spine fracture without preoperative neurologic deficits.

Six (43%) procedures were complicated by dural tears. These were treated as recommended [8] with the suturing of the dural wound, placement of a fat patch or application of a fibrin sealant, and bed rest for at least 24 hours.

In total, 10 (71%) operated patients had a drain placed at the end of the procedure. All drains were positioned deep beneath the aponeurosis. Four (66%) patients had drains placed for dural tears.

3.2 Postoperative deficits, diagnosis-to-treatment interval and neurologic sequelae

Table 2 describes postoperative neurologic complications and their treatment. The most common complication was the onset of a cauda equina syndrome in 9 (64%) patients. These patients then underwent an imaging study of the spine, CT scan (5 patients) or MRI (5 patients), with a median time to completion of 14 hours. Twelve (86%) patients underwent a revision. The median time to revision after the onset of the symptoms was 19 hours (min: 0 hour, max: 11 days). Of these 12 (86%) revisions: eight (57%) were performed in the operating room within the first 24 hours and 4 (29%) more than 24 hours after the onset. Two (14%) patients did not undergo a revision.

None of the 14 patients presented a complete neurologic recovery on the day of the expert review (on average 18 months after surgery) and 10 (71%) made a partial recovery, with mainly persistent sphincter dysfunctions (Table 2). Finally, 4 (29%) cases reported no recovery.

3.3 Expert decisions

One (7%) surgeon was accused and found liable for failing to provide a timely diagnosis and surgical revision (Appendix 2, patient no. 5). The patient presented sensory and motor deficits on the evening of the procedure. This was medically observed upon the patient's arrival in rehabilitation 10 days after surgery. A CT scan of the spine was then performed on the same day and his surgeon reoperated on D11. The patient presented himself at the expert review with disabling paraparesis resulting from the surgery.

Two (14%) clinical situations resulted in the accusation of a floor nurse for failing to call the surgeon despite the signs of neurologic deficits. The surgeon observed one case of sensory and anal sphincter dysfunction and one case of isolated sensory dysfunction during his morning rounds on the following day. This failure to act led to delayed treatment (Appendix 2, patient no. 7 and no. 10). Both patients underwent an emergency reoperation which enabled them to make a partial recovery with one case of persisting sphincter dysfunctions and one case of persisting sensory dysfunction.

As for the other 11 (79%) cases, the postoperative epidural hematoma was considered a no-fault medical accident and the surgeon was not held liable.

Table 3 presents detailed data for each patient.

4. Discussion

In this series of 14 patients, the conviction rate was 21% (3 patients out of 14). All 3 convictions were related to a delayed diagnosis of this complication and/or its delayed treatment. The

conviction rate for a postoperative symptomatic hematoma in spine surgery is lower than other types of surgical complications [9, 10]. For example, the conviction rate in France for complications following arthroscopic surgery is 68% [10]. The median time to revision in our study was 19 hours but could take up to 11 days. It has been clearly established in the literature that a short time to revision after the onset of an epidural hematoma is associated with a better clinical recovery. Amiri et al reported an optimal recovery if the revision took place within 6 hours with an average neurological improvement of 2 Frankel grades [11]. Yi et al reported a complete recovery of deficits only in patients who were reoperated within 24 hours [12]. None of the 14 patients whose cases underwent an expert review recovered completely from their neurologic deficits and a third did not have any neurological improvement after the surgical revision. There is currently no legal maximum time to treatment for which surgeons can be held liable [13]. Two surgeons in our series did not perform a revision surgery given the spontaneous improvement of the neurologic deficit symptoms: one within the first 3 hours after surgery and one within the first 24 hours. However, these remained partial recoveries (Appendix 2, patients no. 2 and no. 12). The neurologic deficits in these 2 cases mainly involved bladder and bowel dysfunctions, and there was no gait deficit. According to the practitioners, the imaging studies performed (MRI and/or CT scan) did not reveal any major epidural compression warranting a revision. It was therefore concluded that the deficits were caused by the initial acute compression and that a surgical revision would not have changed the patient prognosis. No fault was found and none of the surgeons were held liable. Two expert reviews assessed the liability of the nursing staff who did not call the surgeon despite the onset of an early postoperative neurologic deficit. They concluded that this inaction led to a significant delay in treatment, which resulted in only a partial recovery of the postoperative neurologic deficit. Therefore, the delayed diagnosis and treatment of a complication can become incriminating [14].

According to the descriptive data of our study population, typical patients presenting this complication were overweight men over the age of 60, with 50% of them having no comorbidities and no antiplatelet therapy in nearly 80% of cases. Less than half had previously undergone spine surgery. These patients are very common and do not seem any different from those encountered in our daily surgical practice. Among demographic factors, only an age greater than 60 and the presence of a coagulopathy have been reported to be risk factors for hemorrhagic complications following spine surgery [15][16].

The majority of surgical indications in this series (13 (93%)) involved degenerative conditions. These were elective surgeries. The most commonly litigated surgery in this series was recalibration of the lumbar canal without instrumentation, performed in the majority of cases on 2 levels (ex. L3-L4, L4-L5). The wide exposure of the dural sheath puts these patients at risk of a symptomatic hematoma. It is well-established that multilevel decompression surgery is associated with an increased risk of postoperative hematoma [15].

We reported a high incidence of dural tears (43%) in our series. The presence of a tear has been identified as a risk factor for epidural hematoma [17]. The decreased pressure exerted by the dural sheath on the epidural space promotes bleeding from the epidural venous plexus. When faced with this type of difficult-to-control slow venous leak, some surgeons choose to apply hemostatic gel-

foams. Their application over the dura mater has also been reported as a risk factor for symptomatic epidural hematoma [18].

The majority of the expert reviews (71%) in our study reported that drains had been placed under the aponeurosis at the end of surgery. Although there are no recommendations on the necessity of placing a drain at the end of the procedure, whether it be suction or free drainage, it remains a common practice in spine surgery [19]. However, even if the benefit of using a drain has not been established [20-23], its removal is associated with the onset of symptomatic epidural hematomas [18]. Many colleagues seem to use drains as a means of protecting themselves against medicolegal action. We noted in these expert reviews, that the presence or absence of a drain was not considered a determining factor in the practitioner's liability. This register did not give us any information on whether an active or passive drain was used. Among the 14 cases studied, the combined drainage rate in cases of a tear was abnormally high (4 out of 6, i.e. 67%) compared to the usage reported by spine surgeons in France (17% declared using drains in cases of a tear) [19]. Most surgeons abstain from using a drain in cases of a dural tear to avoid the risk of maintaining a cerebrospinal fluid leak [19].

The most common clinical presentation of postoperative epidural hematoma in our series was a cauda equina syndrome (9 patients, 64%), which was observed immediately upon awakening in 4 (45%) cases. This is why close clinical monitoring, especially during the first hours after surgery, is crucial [11]. The presence of new postoperative bladder and bowel dysfunctions seems to be pathognomonic in this series.

The majority of surgeons (9, 64%) in this series performed an imaging study (CT scan or MRI) as soon as the clinical symptoms appeared to confirm the presence of a postoperative symptomatic epidural hematoma. CT scans should only be performed when an MRI is unavailable because of its lower spatial resolution when studying intracanal content. CT scans can also be useful if there is arthrodesis material. MRI visualization of a postoperative asymptomatic hematoma on D1 is common [15]. The prevalence of asymptomatic hematomas varies greatly between studies, with incidence rates ranging from 100% (Kotilainen et al) to 14.5% (Modi et al) [24][25]. There is therefore no use for systematic postoperative MRIs of the spine. The difficulty in performing additional imaging studies lies in the time it takes to obtain them, which can delay the reoperation. Under these circumstances, it might be preferable to reoperate without these images if the time to appropriate these is too long, since the experts might consider this wait to be a "loss of chance" for the patient. However, there is no legal time limit.

In the case of an expert review of a patient presenting a hematoma-type postoperative complication, the treatment of the complication and especially the time to reoperation are analyzed to assess medical and paramedical liability. The law stipulates that physicians are held to an obligation of means due to the potential risks of these procedures whose successful outcomes cannot be guaranteed. Practitioners cannot be held liable for the onset of a hematoma since it is considered a therapeutic risk. They can therefore only be held liable in the event of a fault [26]. Different liabilities may be involved depending on whether the practitioner works in the private or public sector: civil liability for private practices and administrative liability for public hospitals employing the surgeon.

Postoperative symptomatic epidural hematoma is currently considered a therapeutic risk if no fault is found. Hemostatic failures do not qualify as medical errors [27]. To organize compensation, the French national office for compensation of medical accidents (ONIAM) relies on conclusions issued by the CCI.

This study had several limitations: 1) Although the register studied was comprehensive it still resulted in a selection bias. The insurance company we contacted covered approximately 70 to 80% of surgeons. Therefore, we can estimate that we only omitted a small share of expert reviews of symptomatic epidural hematomas in France during the period under review. Access to ONIAM data would enable us to obtain additional results. 2) The surgical techniques, standard or minimally invasive, and operating times were not reported. However, we estimate that this national panel of experts is indicative of the professional practices during the period under review. 3) Since we did not have access to any images during this study we could not define the characteristics of the hematoma (thickness, degree of nerve root compression, number of levels involved). 4) We did not have access to the compensation amount requested from the surgeon that was found liable or the 2 incriminated nurses. Compensation amounts in general have risen sharply in recent years and this trend has also impacted spine surgery complications [28].

5. Conclusion

Spine surgeons, who are often subject to medicolegal actions, need to be aware of the factors that can engage their liability during a complication such as postoperative spinal epidural hematoma. According to our study, only a delayed surgical revision of a postoperative symptomatic epidural hematoma can incur a surgeon's liability. The use of a surgical drain was not taken into account in the decision of the expert reviews. Medical and paramedical teams need to be alert to early warning signs of an epidural hematoma because the longer the postoperative deficits are left untreated the more likely they will be irreversible. Any intense postoperative lumbar or radicular pain despite the major parenteral analgesics, paresthesia of the limbs, or the need of a urinary catheter for a postoperative bladder distention should elicit a diagnosis of epidural hematoma. We can only recommend careful postoperative neurologic monitoring, especially during the first few hours, by paramedical staff who can quickly identify the signs of clinical deterioration. We suggest the earliest possible surgical revision in cases of strong clinical suspicion of epidural hematoma, even if there are no imaging studies because they are taking too long to obtain.

Acknowledgments:

To the MACSF insurance company for giving us access to their claims files for the period under review (2011-2018).

Conflict of interest: Thibault Portella is an expert at MACSF. The other authors certify that they have no affiliation or involvement with any organization involving financial or nonfinancial interests related to the subject matter treated in the manuscript.

The following authors received financial support from the following companies over the past 36 months:

H.-A. Leroy: Stryker, Johnson and Johnson, Medtronic.

R. Assaker: Medtronic, Depuys

Financing

No funding was received for this study.

Contributions

(1) Study conception and design, data collection, analysis and interpretation: T. Portella, H.-A. Leroy, R. Bougeard.

(2) Drafting of the manuscript, critical revision for important intellectual content: H.-A. Leroy, T. Amouyel.

(3) Final revision of the version to be submitted: R. Assaker, K.-L. Mourier

Each of the coauthors is legally responsible for the content of the manuscript: originality, copyright, plagiarism, etc.

References

- [1] Professionnel ME. Risque médico-légal en neurochirurgie : état des lieux. Macsf-Exerc 2019. <https://www.macsf-exerciceprofessionnel.fr/Reglementation-et-actualite/Prevention-des-risques/risques-neurochirurgie> (accessed January 5, 2019).
- [2] Mouton J, Gauthé R, Ould-Slimane M, Bertiaux S, Putman S, Dujardin F. Litigation in orthopedic surgery: What can we do to prevent it? Systematic analysis of 126 legal actions involving four university hospitals in France. *Orthop Traumatol Surg Res OTSR* 2018;104:5–9. <https://doi.org/10.1016/j.otsr.2017.11.002>.
- [3] Agout C, Rosset P, Druon J, Brilhault J, Favard L. Epidemiology of malpractice claims in the orthopedic and trauma surgery department of a French teaching hospital: A 10-year retrospective study. *Orthop Traumatol Surg Res OTSR* 2018;104:11–5. <https://doi.org/10.1016/j.otsr.2017.11.007>.
- [4] Awad JN, Kebaish KM, Donigan J, Cohen DB, Kostuik JP. Analysis of the risk factors for the development of post-operative spinal epidural haematoma. *J Bone Joint Surg Br* 2005;87:1248–52. <https://doi.org/10.1302/0301-620X.87B9.16518>.
- [5] Amiri AR, Fouyas IP, Cro S, Casey ATH. Postoperative spinal epidural hematoma (SEH): incidence, risk factors, onset, and management. *Spine J Off J North Am Spine Soc* 2013;13:134–40. <https://doi.org/10.1016/j.spinee.2012.10.028>.
- [6] Madkouri R, Grelat M, Vidon-Buthion A, Lleu M, Beaurain J, Mourier K-L. Assessment of the effectiveness of SFCR patient information sheets before scheduled spinal surgery. *Orthop Traumatol Surg Res OTSR* 2016;102:479–83. <https://doi.org/10.1016/j.otsr.2016.02.005>.
- [7] Guillain A, Moncany A-H, Hamel O, Gerson C, Bougeard R, Dran G, et al. Spine neurosurgeons facing the judicialization of their profession: disenchantment and alteration of daily practice—a qualitative study. *Acta Neurochir (Wien)* 2020. <https://doi.org/10.1007/s00701-020-04302-z>.
- [8] A review article on the diagnosis and treatment of cerebrospinal fluid fistulas and dural tears occurring during spinal surgery n.d. <https://www.ncbi.nlm.nih.gov/pmc/articles/PMC3801173/> (accessed March 26, 2020).
- [9] Sarmiento S, Wen C, Cheah MA, Lee S, Rosson GD. Malpractice Litigation in Plastic Surgery: Can We Identify Patterns? *Aesthet Surg J* 2020;40:NP394–401. <https://doi.org/10.1093/asj/sjz258>.
- [10] Pioger C, Jacquet C, Abitan A, Odri G-A, Ollivier M, Sonnery-Cottet B, et al. Litigation in arthroscopic surgery: a 20-year analysis of legal actions in France. *Knee Surg Sports Traumatol Arthrosc Off J ESSKA* 2020. <https://doi.org/10.1007/s00167-020-06182-3>.
- [11] Amiri AR, Fouyas IP, Cro S, Casey ATH. Postoperative spinal epidural hematoma (SEH): incidence, risk factors, onset, and management. *Spine J Off J North Am Spine Soc* 2013;13:134–40. <https://doi.org/10.1016/j.spinee.2012.10.028>.
- [12] Yi S, Yoon DH, Kim KN, Kim SH, Shin HC. Postoperative spinal epidural hematoma: risk factor and clinical outcome. *Yonsei Med J* 2006;47:326–32. <https://doi.org/10.3349/ymj.2006.47.3.326>.
- [13] Pretat P-H. Prise en charge de l'hématome épidural lombaire post-opératoire : délai d'évacuation et potentiel de récupération neurologique, à propos de 44 cas. other. Université de Lorraine, 2017.
- [14] Daniels AH, Ruttiman R, Eltorai AEM, DePasse JM, Brea BA, Palumbo MA. Malpractice litigation following spine surgery. *J Neurosurg Spine* 2017;27:470–5. <https://doi.org/10.3171/2016.11.SPINE16646>.
- [15] Sokolowski MJ, Garvey TA, Perl J, Sokolowski MS, Cho W, Mehbod AA, et al. Prospective Study of Postoperative Lumbar Epidural Hematoma: Incidence and Risk Factors. *Spine* 2008;33:108–13. <https://doi.org/10.1097/BRS.0b013e31815e39af>.
- [16] Kou J, Fischgrund J, Biddinger A, Herkowitz H. Risk Factors for Spinal Epidural Hematoma After Spinal Surgery: *Spine* 2002;27:1670–3. <https://doi.org/10.1097/00007632-200208010-00016>.
- [17] Akins PT, Harris J, Alvarez JL, Chen Y, Paxton EW, Bernbeck J, et al. Risk Factors Associated With 30-day Readmissions After Instrumented Spine Surgery in 14,939 Patients: 30-day readmissions after instrumented spine surgery. *Spine* 2015;40:1022–32. <https://doi.org/10.1097/BRS.0000000000000916>.
- [18] Kao F-C, Tsai T-T, Chen L-H, Lai P-L, Fu T-S, Niu C-C, et al. Symptomatic epidural hematoma after lumbar decompression surgery. *Eur Spine J Off Publ Eur Spine Soc Eur Spinal Deform Soc Eur Sect Cerv Spine Res Soc* 2015;24:348–57. <https://doi.org/10.1007/s00586-014-3297-8>.

- [19] Portella T, Leroy H-A, Amouyel T, Assaker R, Beaurain J. Facteurs influençant le drainage postopératoire de la plaie en chirurgie du rachis dégénératif : sondage national en France. *Rev Chir Orthopédique Traumatol* 2019;105:748–52. <https://doi.org/10.1016/j.rcot.2019.05.002>.
- [20] Ovadia D, Drexler M, Kramer M, Herman A, Lebel D. Closed Wound Sub-Fascial Suction Drainage in Posterior Fusion Surgery for Adolescent Idiopathic Scoliosis: A Prospective Randomize Control study. *Spine* 2018. <https://doi.org/10.1097/BRS.0000000000002892>.
- [21] Herrick DB, Tanenbaum JE, Mankarious M, Vallabh S, Fleischman E, Kurra S, et al. The relationship between surgical site drains and reoperation for wound-related complications following posterior cervical spine surgery: a multicenter retrospective study. *J Neurosurg Spine* 2018;29:628–34. <https://doi.org/10.3171/2018.5.SPINE171313>.
- [22] Payne DH, Fischgrund JS, Herkowitz HN, Barry RL, Kurz LT, Montgomery DM. Efficacy of closed wound suction drainage after single-level lumbar laminectomy. *J Spinal Disord* 1996;9:401–3.
- [23] Kanayama M, Oha F, Togawa D, Shigenobu K, Hashimoto T. Is Closed-suction Drainage Necessary for Single-level Lumbar Decompression?: Review of 560 Cases. *Clin Orthop* 2010;468:2690–4. <https://doi.org/10.1007/s11999-010-1235-6>.
- [24] Kotilainen E, Alanen A, Erkintalo M, Helenius H, Valtonen S. Postoperative hematomas after successful lumbar microdiscectomy or percutaneous nucleotomy: a magnetic resonance imaging study. *Surg Neurol* 1994;41:98–105.
- [25] Modi HN, Lee DY, Lee S-H. Postoperative spinal epidural hematoma after microscopic lumbar decompression: a prospective magnetic resonance imaging study in 89 patients. *J Spinal Disord Tech* 2011;24:146–50. <https://doi.org/10.1097/BSD.0b013e3181e1958e>.
- [26] Code de la santé publique - Article L1142-1. vol. L1142-1. n.d.
- [27] El Banna S, Delahaut O. [Complications of spine surgery and litigations]. *Rev Med Brux* 2009;30:568–76.
- [28] Risque médico-légal en neurochirurgie - MACSF 2020. <https://www.macsf.fr/Responsabilite-professionnelle/Prevention-des-risques/risques-neurochirurgie> (accessed March 11, 2020).

Figure legends

Figure 1: Study flowchart.

Table 1: Demographics

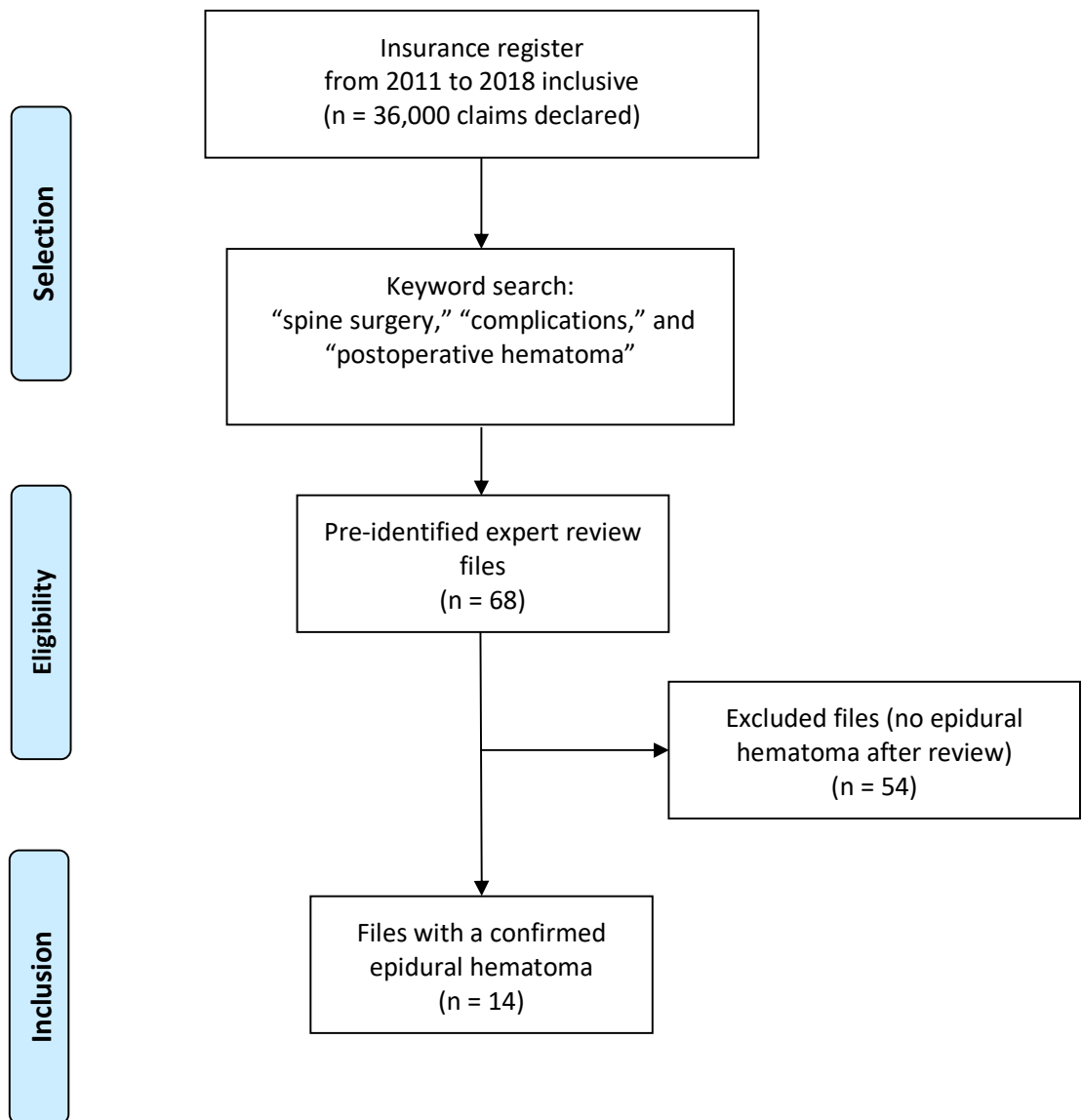
Variables	n (%)
Age (median, range)	61.5 (39-71)
Sex	
Male	9
Female	5
M/F ratio	1.8
Body mass index (median, range)	27.3 (21-35)
History	
Spine surgery	5 (36)
Hemostasis disorder	1 (7)
Osteoporosis	1 (7)
Antiplatelets	3 (21)
Type of procedure	
Herniated disk repair	2 (14)
Recalibration	
1 level	3 (21)
2 levels	5 (36)
≥ 3 levels	0 (0)
Laminarthrectomy and arthrodesis	
1 level	1 (7)
2 levels	1 (7)
≥ 3 levels	2 (14)
Dural tear	6 (43)
Surgical drain	10 (71)
Surgeon specialty	
Neurosurgeon	11 (79)
Orthopedist	3 (21)

Table 2: Neurologic complications related to the onset of an epidural hematoma and its treatment.
 *: One patient underwent both an emergency CT scan and MRI. **: the degree of clinical recovery was defined during the expert review (on average 18 months after the complication).

Variables	n (%)
Type of neurologic deficit	
Cauda equina syndrome	9 (64)
Sensory and motor deficits in the two LEs	3 (21)
Isolated paraparesis	1 (7)
Isolated sensory disturbances	1 (7)
Postoperative imaging	
CT scan	5 (36)*
MRI	5 (36)*
None	5 (36)
Time to imaging (median, range)	14H (1H to 10D)
Surgical revision	12 (86)
Time to revision (median, range)	19H (0H to 11D)
Clinical recovery **	
Complete	0 (0)
Partial	10 (71)
None	4 (29)

Table 3: Comprehensive data for each of the 14 patients

Figure 1:



Patient No.	Age	Sex	BMI	History	Antiaggregants	Surgical indication	Surgical procedure	Dural tear	Drainage	Drainage type	Neurological signs warranting the revision	Imaging performed	Time to surgical revision	Clinical progression at the expert review	Healthcare team implicated	Team member targeted	Reasons sited
1	71	F	27.3	Osteoporosis	/	T12 fracture caused by kyphosis	Laminectomy / osteotomy / arthrodesis	No	No	/	Lower extremity deficit	CT scan	< 6H	Sensory recovery only	No		
2	39	M	28.9	/	/	L5/S1 left HID	HID repair	Yes	No	/	Incomplete cauda equina syndrome	MRI	No revision	Spontaneous improvement of the deficit 3.5 hrs after onset	No		
3	64	H	28.1	Operated lumbar HID	/	L3/L5 stenosis	Laminectomy / arthrodesis / lumbar arthrodesis	No	Yes	Suction	Paraparesis 2 hrs after surgery	None	Immediately	Partial recovery	No		
4	60	M	28	Operated LSS	Plavix	L3/L4 LSS	L3/L5 laminectomy	Yes	Yes	Suction	Cauda equina syndrome	None	19H	Sensory recovery only	No		
5	65	F	27.3	Idiopathic thrombocytopenia	/	L4/L5 stenosis	T12/S1 laminectomy / arthrodesis	No	Yes	Suction	Sensory and motor deficits at night	CT scan D10	D11	Paraparesis of the lower extremities	Yes	Surgeon	Delayed treatment given neurological signs
6	60	M	24	/	/	L2/L4 stenosis	L2/L4 laminectomy	Yes	Yes	Siphon	Sensory and motor deficits the next day at 8 a.m.	MRI	16H	Progressive partial recovery	No		
7	60	M	26.7	5 spine surgeries	/	L5/S1 LSS	L5/S1 recalibration	No	Yes	NA	Worsening of sensory dysfunctions for 2 days	None	D3	Partial recovery	Yes	Floor nurse	Delayed treatment, did not call surgeon
8	62	F	25.2	/	Kardegic	L3/L4 left stenosis	L3/L4 left unilateral recalibration	Yes	Yes	Siphon	Incomplete cauda equina syndrome	MRI	21H	No recovery	No		
9	67	M	28.4	Operated HID L4/L5	/	L3/L4 HID	Recalibration with hernia repair	Yes	No	/	Cauda equina syndrome	None	< 6H then again < 6H	No recovery	No		
10	68	M	28	/	Kardegic	L3/L5 LSS	L3/L5 recalibration	No	Yes	NA	Progressive motor and sphincter dysfunctions	None	13H	Progressive partial recovery	Yes	Floor nurse	Delayed treatment, did not call surgeon
11	47	M	27.2	Operated lumbar HID	/	L3/L5 LSS	L3/L5 bilateral recalibration	Yes	Yes	Siphon	Incomplete cauda equina syndrome	CT scan	Revision (time interval unknown)	No recovery	No		
12	63	F	35	/	/	L4/L5 stenosis	L4/S1 recalibration	No	Yes	Suction	Sphincter dysfunctions	CT scan D1 and MRI D4	No revision	Partial recovery	No		
13	57	M	24.4	/	/	L4/L5 HID	HID repair	No	No	/	Sphincter dysfunctions	MRI	D7	No motor or sphincter recovery L5	No		
14	61	M	26.8	/	/	L4/L5 stenosis	Laminectomy / arthrodesis / arthrodesis	No	Yes	Siphon	Incomplete cauda equina syndrome D1	CT scan	D2	Progressive partial recovery	No		

Table 3