



**HAL**  
open science

## Diagnosis of reoperated cervical non-union: Multicenter retrospective study about 45 patients.

M. Huneidi, Y. Ntilikina, I. Obeid, B. Bouyer, Fahed Zairi, Paulo Marinho, Y. P. Charles, J. M. Vital, O. Gille, L. Boissière

### ► To cite this version:

M. Huneidi, Y. Ntilikina, I. Obeid, B. Bouyer, Fahed Zairi, et al.. Diagnosis of reoperated cervical non-union: Multicenter retrospective study about 45 patients.. Orthopaedics & Traumatology: Surgery & Research, 2021, Orthopaedics & Traumatology: Surgery & Research, pp.102924. 10.1016/j.otsr.2021.102924 . hal-04418966

**HAL Id: hal-04418966**

**<https://hal.univ-lille.fr/hal-04418966>**

Submitted on 22 Jul 2024

**HAL** is a multi-disciplinary open access archive for the deposit and dissemination of scientific research documents, whether they are published or not. The documents may come from teaching and research institutions in France or abroad, or from public or private research centers.

L'archive ouverte pluridisciplinaire **HAL**, est destinée au dépôt et à la diffusion de documents scientifiques de niveau recherche, publiés ou non, émanant des établissements d'enseignement et de recherche français ou étrangers, des laboratoires publics ou privés.



Distributed under a Creative Commons Attribution - NonCommercial 4.0 International License

## Original article

### Diagnosis of reoperated cervical non-union: Multicenter retrospective study about 45 patients

Maxime **Huneidi** (1), Yves **Ntilikina** (2), Ibrahim **Obeid** (1), Benjamin **Bouyer** (1),  
Fahed **Zairi** (3), Paulo **Marinho** (4), Yann-Philippe **Charles** (2), Jean-Marc **Vital** (1),  
Olivier **Gille** (1), Louis **Boissière** (1)

(1) Centre Hospitalier Universitaire de Bordeaux, Unité de Chirurgie Rachidienne, CHU  
Tripode Pellegrin, Place Amélie Raba Léon, 33076 Bordeaux, France

(2) Service de Chirurgie du Rachis, Hôpitaux Universitaires de Strasbourg, 1 Place de  
l'Hôpital, BP 426, 67091 Strasbourg Cedex, France

(3) CHRU de Lille, Hôpital Roger-Salengro, Service de Neurochirurgie, Rue Emile-  
Laine, 59037 Lille Cedex, France

(4) Centre du Rachis de la Sauvegarde, 29b Avenue des Sources, 69009 Lyon, France

**Corresponding author:** Maxime Huneidi,

Centre hospitalier universitaire de Bordeaux, unité de chirurgie rachidienne, CHU Tripode  
Pellegrin, Place Amélie Raba Léon, 33076 Bordeaux, France

maximehuneidi@gmail.com

## Abstract

Introduction:

Non-union is one of the main complications of single- or multi-level cervical spine fusion, considerably impairing functional results. The aim of this study was to evaluate the respective contributions of imaging examinations in the diagnostic process, the challenge being to avoid inappropriate surgery and unnecessary complementary examinations.

## Material and method

A retrospective multicenter study included all patients managed for cervical spine non-union between 2008 and 2018. We evaluated the imaging examinations performed on each patient and determined signs of non-union in each image.

## Results

The study included 45 patients in 4 centers: 55% female; mean age, of  $48 \pm 8.0$  years; 57% smokers. Systematic static radiography showed signs of non-union in 55% of cases. Dynamic X-ray was performed in 34% of patients, and showed hypermobility of the level in 80% of cases. CT supported diagnosis of non-union in 97% of cases, and MRI in 48%. SPECT-CT was positive in all cases of non-union.

## Discussion

Dynamic X-ray is rarely prescribed, but frequently provided an objective measure of hypermobility of the level in non-union, justifying first-line use. Millimetric-slice CT was reliable for diagnosis. MRI is relevant only once diagnosis has been made, as part of preoperative work-up. Nuclear imaging can be useful in order to solve doubtful cases.

## Conclusion

In suspected cervical spine non-union, we recommend dynamic X-rays (flexion/extension) and CT-scan as first-line diagnosis examinations.

**Level of evidence:** IV

**Keywords:** non-union, spine, fusion

## **INTRODUCTION**

Cervical spine fusion via an anterior approach is frequently performed for cervicobrachial neuralgia or myelopathy in cervical osteoarthritis.

Despite progress in technique and instrumentation, non-union remains a prime cause of failure in this surgery [1], with incidence of 2.6-15.2% [2]. It is usually defined as absence of interbody bone fusion at 1 year or non-progression of the bone callus [2–6].

It is asymptomatic in 50% of cases [1], but can result in recurrence of cervicalgia or radiculalgia or myelopathy after an immediate phase of postoperative improvement.

The major issue in case of such poor progression is precise diagnosis of non-fusion underlying pain. Pain may in fact be multifactorial, without involving consolidation defect, notably in case of adjacent syndrome, which affects up to 21% of patients undergoing fusion surgery in the long term [7]

Various diagnostic imaging examinations are available, with a gold-standard of surgical exploration revealing non-integration of material and abnormal mobility in the operated segment [3].

In the absence of consensus on imaging [2], we examined the diagnostic approaches leading to surgical revision of non-union, in a retrospective study.

## **Material and method**

A multicenter study included all patients undergoing surgical revision of non-union in 1- or 2-level anterior cervical fusion between August 1, 2008 and August 1, 2018. Exclusion criteria comprised  $\geq 3$ -level fusion, corpectomy and fusion in traumatic, infectious or tumoral contexts.

Study data comprised:

- Epidemiologic and clinical data: age at primary surgery, gender, body-mass index (BMI), smoking status, time to symptom onset, interval between surgeries, self-reported satisfaction after revision (symptom resolution, improvement with residual pain, no improvement).

- Surgical data: operated levels and number, type of cage, type of graft, plate (or not).
- Postoperative data: immobilization (yes/no) and duration.
- Radiologic data showing non-union and result:
  - Standard X-ray (non-consolidation: yes/no/neutral): signs comprised radiolucency between interbody cage and adjacent vertebral endplate, hyperlucency around screws (if used), hardware slippage on successive views at several months' interval, hardware breakage.
  - Dynamic X-ray (hypermobility: yes/no): >2mm change in interspinal distance between flexion and extension views [1–3,5,8,9].
  - CT (fusion: yes/no/doubtful): hypodensity around implants, subsidence of adjacent endplates, osteolysis [1,3,5–9].
  - MRI (Modic classification): Modic-1 signal of adjacent plates (= non-union).
  - Bone-scan (fixation: yes/no)
  - SPECT-CT (bone-scan coupled to CT) (fixation adjacent to cage: yes/no).

Images were interpreted by 2 surgeons as positive, negative or neutral for non-union, based on the above criteria.

Descriptive statistics used mean values, percentages, and standard deviations on Excel ® software.

## **Results**

45 patients undergoing revision surgery for cervical spine non-union were included.

### **Population characteristics, surgical and postoperative data** (Table 1)

There was 55.6% female predominance. Mean age was 48.0 years. Most patients were smokers. Symptom onset was mainly within 1 year of primary surgery. Presenting symptoms were mainly disabling neck pain after a pain-free interval of several weeks, or, more rarely, cervicobrachial neuralgia.

## **Diagnostic examinations**

### Static X-ray

Static AP and lateral views were taken systematically.

55% of follow-up radiographs showed signs of non-union; 45% were neutral or showed good consolidation.

### Dynamic X-ray (Figure 1)

Dynamic X-ray was performed in just 34% of cases. In case of non-union, 80% showed abnormal mobility between flexion and extension in the fused segment.

### CT

CT was performed in 78% of cases. 97% of scans showed signs of non-union; 3% suggested consolidation.

### MRI

MRI was performed in 53% of cases. 48% of scans showed signs of non-union: Modic-1 hypersignal in the operated level.

### Nuclear imaging (Figure 2)

SPECT-CT was performed in 38% of cases. It was systematically positive, with hyperfixation in the non-union level. Isolated bone scan was not performed: its use seems to have been abandoned.

## **Revision surgery (Table 2)**

All patients underwent surgical revision via an anterior approach, except for 1 case with combined approach due to endplate subsidence with local kyphosis and severe osteoporosis; complementary fixation was therefore performed in order to secure bone fixation.

Revision was at a mean  $33.1 \pm 27.5$  months after primary surgery (range, 8-123 months).

Mean interval between non-union symptom onset and revision was  $18.8 \pm 26$  months (median, 10 months).

In 84% of cases, the new interbody implant was autologous iliac crest graft with anterior plate; in 16%, a cage was replaced by a cervical prosthesis.

## **Follow-up**

Clinical results were good, with symptom improvement and resolution of pain in 80% of cases, moderate in 11.1%, and poor in 8.9%.

In good or moderate clinical progression, radiographic follow-up comprised simple static X-ray.

93.3% of patients showed consolidation.

## **DISCUSSION**

Anterior cervical fusion is a common procedure with good results, but some long-term complications (adjacent syndrome, non-union) can jeopardize functional outcome[7]. Non-union is rare: in 10 years, we found only 45 revision surgeries in what, to our knowledge, is the largest reported series.

The present series showed a 57% rate of smoking, compared to 35% in a “normal” population according to a 2018 study [10], while BMI was comparable. In a 2014 study, Lau showed smoking to be an independent risk factor for non-union after cervical corpectomy, in agreement with the present findings [11]. In a 2016 literature review, Jackson likewise reported higher rates of non-union and infection in smokers after spinal and lumbar surgery[12]

The present population comprised 55% females and 45% males. Gender seemed not to be a factor, this sex ratio being comparable to those in other studies of primary spinal surgery. In the absence of a control group not undergoing revision over the same period, we referred to a 2018 series of 52,395 cervical spine fusions, which had a mean age of 53 years, with 48.6% males and 51.4% females [13].

Results for each examination were dichotomized as definite fusion versus definite non-union or doubtful fusion, considering further imaging unnecessary in the former but not in the latter.

In 71.1% of cases, non-union was treated by stand-alone cage, and by anterior plate in 28.9%. To draw any conclusion, however, would require comparison with all fusion procedures performed in the study centers in the study period.

In the present series, dynamic X-ray was associated to static X-ray in only 34% of cases, but was pathological in 80% of these cases. It is an inexpensive examination, and seems useful and sufficient if suspicion of non-union is weak or the patient shows only mild symptoms. A literature review by Oshina et al. [10] confirmed that the best way to establish fusion is to detect no mobility exceeding 2mm on dynamic X-ray; this threshold is the optimal diagnostic compromise, with 91% sensitivity and 89% sepecificity[14].

One limitation in interpretation is image scale, calibration and deformation depending on how dynamic X-ray is performed, with risk of imprecise measurement.



Millimetric-slice CT is our gold-standard, and is widely used in the literature in this indication, showing 78.6-85.7% correlation with intraoperative assessment of fusion[15].

MRI is widely used in diagnosing the primary pathology, but showed only 48% sensitivity. T2 hypersignal was difficult to discern and interpret, because of implant-related artifacts. These findings are in agreement with the literature.

In a 2014 study, Gruskay et al. [5] advocated MRI only for revision planning, to rule out recurrent or residual foraminal stenosis. Buchowski et al. [15] reported a correlation coefficient of no more than 0.48 between MRI and intraoperative diagnosis.

However, although diagnostic performance for cervical non-union is poor, MRI is indispensable in planning revision, to determine relations with nerve tissue. Diagnostic applications, on the other hand, seem less indicated.

Bone scan is little used in our practice. With the development of nuclear medicine and the very high sensitivity of SPECT-CT, this is likely to be prescribed more often than it was during the present inclusion period. It is widely reported in diagnosis of lumbar non-union [16]. Interpretation needs to be cautious, as its high sensitivity is at the expense of specificity, with consequent risk of overdiagnosis. In case of strong clinical suspicion, on the other hand, with doubtful CT and absence of mobility on dynamic X-ray, SPECT-CT is certainly contributive. It can also identify differential diagnoses such as posterior arthropathy[17]. PET-CT has never been used for diagnosis of non-union; it is relevant more to diagnosis of chronic sepsis[18].

In more than 50% of cases, revision was performed more than 10 months after symptom recurrence, for a median 1 year 10 months after primary fusion. This may be due to the difficulty of diagnosis and reluctance to acknowledge failure and reintervene. Even so, the present revision surgeries showed positive results, with resolution or at least improvement of symptoms in 91% of cases.

We believe that revision for non-union often comes too late, with negative consequences for the patient both socially and occupationally, although this was not assessed in the present study.

On the other hand, Lee et al. [4], in a series of 29 patients with cervical spine non-union, found that 71% without fusion at 1 year had achieved fusion by 2 years, and suggested waiting 2 years before diagnosing non-union. This, however, jeopardizes social life and return to work in case of genuine non-union, and may be inadvisable.

Most of the present series had cages with bone substitute. Despite the low rate of non-union, primary prevention using iliac autograft should be considered[19].

In the vast majority of the present cases, the revision approach was anterior. In 2016, Elder reported excellent fusion rates with both anterior and posterior approaches[20].

In a 2009 literature review, Kaiser disclosed a trend for more reliable fusion after posterior fixation, with better clinical results, although the methodological limitations of the studies precluded any firm conclusion[21].

Choice of approach is thus to be made on a case-by-case basis, according to bone stock in the level concerned.

The present study had certain limitations. It was retrospective, including only patients with surgical revision. Not all patients had the same complementary examinations, decreasing the power of the study by introducing a “center” effect. There was no control population, but only patients with surgical revision. Many asymptomatic patients with non-union were not assessed, as was also the case for symptomatic patients declining revision surgery. And lastly, the absence of standardized clinical follow-up scores hindered analysis of clinical results, although the study objective was primarily to detail diagnostic approaches, with a view to establishing consensus.

Despite all this, this was to our knowledge the largest series reported for cervical non-union with anterior revision.

The present findings suggest certain recommendations for complementary imaging to diagnose cervical non-union.

Standard follow-up: Cervical spine X-ray, and dynamic views in hyperflexion/hyperextension to measure change in interspinal distance.

In case of suspect images and symptomatic patient: Work-up completed by millimetric-slice CT.

In case of strong suspicion despite CT not suggesting non-union: Subsequent SPECT-CT check.

## **Conclusion**

In case of recurrence of cervicalgia after cervical spine fusion, symptom intensity may suggest non-union.

Although infrequent, this is one of the main causes of failure. Diagnosis is founded on 3 examinations: static X-ray, dynamic X-ray in hyperflexion and hyperextension, and millimetric-slice CT.

The combination of the 3 bears out diagnosis of non-union, rarely definitely confirmed by just 1 modality. SPECT-CT may sometimes decide the most complex cases. Screening on dynamic X-ray for interspinal distance differing by >2mm between flexion and extension is an inexpensive examination that is under-used, yet sensitive and specific.

Surgical revision is indicated only on clinical criteria but with radiologic concordance, and gives favorable results in more than 80% of cases.

### **Disclosure of interest**

The authors have no conflicts of interest to disclose or any funding in relation to the present study

**Funding:** Study part of the 2018 SoFCOT symposium; no funding

**Author contributions:**

Maxime Huneidi: design, data analysis and statistics, article writing, re-editing, data collection

Yves Ntilikina: data collection

Ibrahim Obeid: supervision, analysis

Benjamin Bouyer: supervision

Fahed Zairi: data collection

Marinho Paulo: data collection

Yann-Philippe Charles: supervision, analysis

Jean-Marc Vital: supervision, analysis

Olivier Gille: supervision, analysis

Louis Boissiere: design, methodology, supervision, analysis, article writing and re-editing

## References

1. Leven, D. & Cho, S. K. Pseudarthrosis of the Cervical Spine: Risk Factors, Diagnosis and Management. *Asian Spine Journal* **10**, 776 (2016).
2. Choi, S. H. *et al.* Preoperative Radiographic Parameters to Predict a Higher Pseudarthrosis Rate After Anterior Cervical Discectomy and Fusion: *SPINE* **42**, 1772–1778 (2017).
3. Kani, K. K. & Chew, F. S. Anterior cervical discectomy and fusion: review and update for radiologists. *Skeletal Radiology* **47**, 7–17 (2018).
4. Lee, D.-H. *et al.* What Is the Fate of Pseudarthrosis Detected 1 Year After Anterior Cervical Discectomy and Fusion?: *SPINE* **43**, E23–E28 (2018).
5. Gruskay, J. A., Webb, M. L. & Grauer, J. N. Methods of evaluating lumbar and cervical fusion. *The Spine Journal* **14**, 531–539 (2014).
6. Bishop, R. C., Moore, K. A. & Hadley, M. N. Anterior cervical interbody fusion using autogeneic and allogeneic bone graft substrate: a prospective comparative analysis. *Journal of Neurosurgery* **85**, 206–210 (1996).
7. Buttermann, G. R. Anterior Cervical Discectomy and Fusion Outcomes over 10 Years: A Prospective Study. *SPINE* **43**, 207–214 (2018).
8. Spinelli, J., Neal, C. J. & Rosner, M. K. Performance of Cervical Arthroplasty at a Pseudarthrosed Level of a MultiLevel Anterior Cervical Discectomy and Fusion: Case Report. *Military Medicine* **181**, e621–e624 (2016).
9. Ghiselli, G., Wharton, N., Hipp, J. A., Wong, D. A. & Jatana, S. Prospective Analysis of Imaging Prediction of Pseudarthrosis After Anterior Cervical Discectomy and Fusion: Computed Tomography Versus Flexion-Extension Motion Analysis With Intraoperative Correlation. *Spine* **36**, 463–468 (2011).
10. Jossieran, L. Le tabagisme en France : quelle est la situation ? *Revue de Pneumologie Clinique* **74**, 124–132 (2018).
11. Lau, D., Chou, D., Ziewacz, J. E. & Mummaneni, P. V. The effects of smoking on perioperative outcomes and pseudarthrosis following anterior cervical corpectomy. *Journal of Neurosurgery: Spine* **21**, 547–558 (2014).

12. Jackson, K. L. & Devine, J. G. The Effects of Smoking and Smoking Cessation on Spine Surgery: A Systematic Review of the Literature. *Global Spine Journal* **6**, 695–701 (2016).
13. Kelly, M. P., Eliasberg, C. D., Riley, M. S., Ajiboye, R. M. & SooHoo, N. F. Reoperation and complications after anterior cervical discectomy and fusion and cervical disc arthroplasty: a study of 52,395 cases. *European Spine Journal* **27**, 1432–1439 (2018).
14. Kaiser, M. G. *et al.* Radiographic assessment of cervical subaxial fusion. *Journal of Neurosurgery: Spine* **11**, 221–227 (2009).
15. Williams, L. Surgical Exploration Versus Radiographic Evaluation. 7.
16. Slizofski, W. J. *et al.* Painful pseudarthrosis following lumbar spinal fusion: detection by combined SPECT and planar bone scintigraphy. *Skeletal Radiology* **16**, 136–141 (1987).
17. Trout, A. T., Sharp, S. E., Anton, C. G., Gelfand, M. J. & Mehlman, C. T. Spondylolysis and Beyond: Value of SPECT/CT in Evaluation of Low Back Pain in Children and Young Adults. *RadioGraphics* **35**, 819–834 (2015).
18. Dauchy, F.-A. *et al.* Interest of [ 18 F]fluorodeoxyglucose positron emission tomography/computed tomography for the diagnosis of relapse in patients with spinal infection: a prospective study. *Clinical Microbiology and Infection* **22**, 438–443 (2016).
19. Krause, K. L., Obayashi, J. T., Bridges, K. J., Raslan, A. M. & Than, K. D. Fivefold higher rate of pseudarthrosis with polyetheretherketone interbody device than with structural allograft used for 1-level anterior cervical discectomy and fusion: Presented at the 2018 AANS/CNS Joint Section on Disorders of the Spine and Peripheral Nerves. *Journal of Neurosurgery: Spine* **30**, 46–51 (2019).
20. Elder, B. D. *et al.* Successful anterior fusion following posterior cervical fusion for revision of anterior cervical discectomy and fusion pseudarthrosis. *Journal of Clinical Neuroscience* **24**, 57–62 (2016).
21. Kaiser, M. G. *et al.* Management of anterior cervical pseudarthrosis. *Journal of Neurosurgery: Spine* **11**, 228–237 (2009).

Table 1 - Epidemiological data for primary surgery

<b>Mean age (years)</b>	48.0 (± 8.0)
<b>Mean BMI (kg.m<sup>-2</sup>)</b>	24.8 (± 4.3)
<b>Smoking n (%)</b>	25 (55.6%)
<b>Center</b>	Bordeaux: 26 (57.8%) Strasbourg: 10 (22.2%) Lyon: 5 (11.1%) Lille: 4 (8.9%)
<b>1 level n (%)</b>	27 (60%)
- C4-C5 n (%)	- 5 (18.5%)
- C5-C6 n (%)	- 14 (51.9%)
- C6-C7 n (%)	- 6 (22.2%)
- C7-T1 n (%)	- 2 (7.4%)
<b>2 levels n (%)</b>	18 (40%)
- C4-C5 + C5-C6	- 8 (44.4%)
- C5-C6 + C6-C7	- 10 (55.6%)
<b>Anterior plate n (%)</b>	13 (28.9%)

---

**Interbody material**

- |                                |            |
|--------------------------------|------------|
| - Cage with bone substitute    | 41 (91.1%) |
| - Autologous iliac crest graft | 4 (8.9%)   |

---

**Cervical immobilization**

- |                                      |            |
|--------------------------------------|------------|
| - 4-6 weeks flexible cervical collar | 18 (40%)   |
| - None                               | 27 (60.0%) |

---

**Onset of pain (months)**

- |          |             |
|----------|-------------|
| - Mean   | 15.9 ± 21.3 |
| - Median | 6.5 (0-96)  |
-



Table 2 – Revision surgery data

---

<b>Confirmation of diagnosis of non-union</b>	- <b>Yes: 45 (100%)</b>
	- <b>No: 0 (0%)</b>

---

<b>Clinical follow-up</b>	- Globally good: 36 (80%)
	- Globally moderate: 5 (11.1%)
	- Globally poor: 4 (8.9%)

---

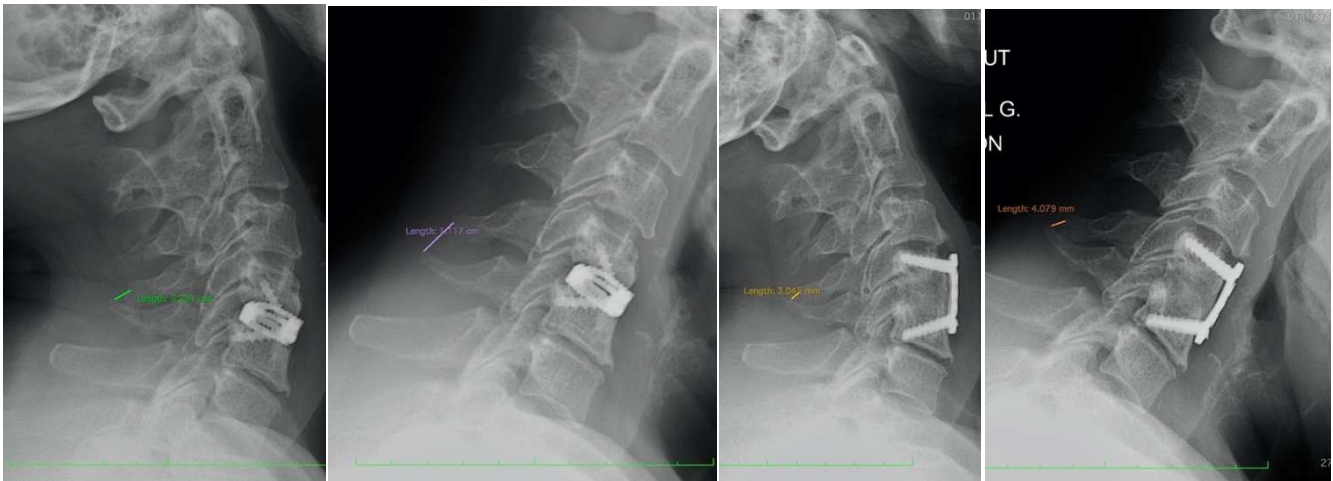

FIGURE 1 – 43 year-old female with C4-C5 fusion. At 11 months: dynamic X-ray showing 6mm mobility between views. Anterior revision by iliac graft: good radiological and clinical progression at 4 months (1 mm between hyperflexion and hyperextension: i.e., less than the 2 mm threshold)

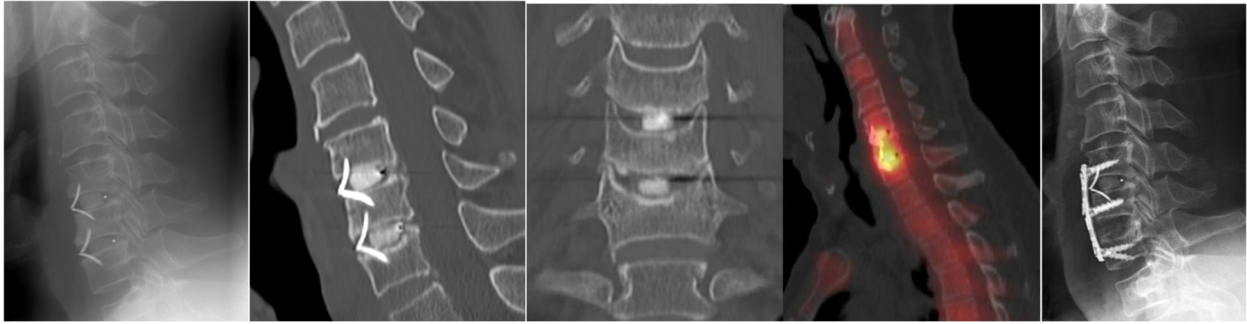


FIGURE 2

58 year-old male with previous C5-C6 and C6-C7 anterior fusion. Recurrence of symptoms after 21 months and poor progression. X-ray and CT-scan suspected non-union of the C6-C7 cage. SPECT-CT was obtained in order to evaluate the need for surgical revision and revealed a hyperfixation only on the C6-C7 level. Revision surgery was performed via an anterior approach with a C6-C7 iliac crest graft and a C5-C7 anterior plate. Satisfactory results were obtained 6 months after revision procedure.