



HAL
open science

Minimally invasive surgery for intradural spinal meningioma: a new standard? A comparative study between minimally invasive and open approaches.

C. Dauleac, Henri-Arthur Leroy, Melodie-Anne Karnoub, L. Obled, P. Mertens, Richard Assaker

► To cite this version:

C. Dauleac, Henri-Arthur Leroy, Melodie-Anne Karnoub, L. Obled, P. Mertens, et al.. Minimally invasive surgery for intradural spinal meningioma: a new standard? A comparative study between minimally invasive and open approaches.. Neurochirurgie, 2022, Neurochirurgie, 10.1016/j.neuchi.2022.01.006 . hal-04419509

HAL Id: hal-04419509

<https://hal.univ-lille.fr/hal-04419509v1>

Submitted on 22 Jul 2024

HAL is a multi-disciplinary open access archive for the deposit and dissemination of scientific research documents, whether they are published or not. The documents may come from teaching and research institutions in France or abroad, or from public or private research centers.

L'archive ouverte pluridisciplinaire **HAL**, est destinée au dépôt et à la diffusion de documents scientifiques de niveau recherche, publiés ou non, émanant des établissements d'enseignement et de recherche français ou étrangers, des laboratoires publics ou privés.



Distributed under a Creative Commons Attribution - NonCommercial 4.0 International License

Minimally invasive surgery for intradural spinal meningioma: a new standard? A comparative study between minimally invasive and open approaches

Corentin Dauleac M.D. M.Sc.^{1,2}, Henri-Arthur Leroy M.D. M.Sc.^{3,4,5}, Mélodie-Anne Karnoub M.D. M.Sc.^{3,4}, Louis Obled M.D.^{3,4}, Patrick Mertens M.D. Ph.D.^{1,2}, Richard Assaker M.D. Ph.D.^{3,4}

1. Service de Neurochirurgie, Hospices Civils de Lyon, Hôpital Neurologique Pierre Wertheimer, Lyon, France
2. Université de Lyon I, Université de Lyon, Lyon, France
3. Service de Neurochirurgie, Hôpital Roger Salengro, CHU de Lille, Lille, France
4. Université de Lille, Lille, France
5. INSERM, CHU-Lille, U1189-ONCOTHAI-Assisted Laser Therapy and Immunotherapy for Oncology, Univ-Lille, F-59000 Lille, France.

Conflict of Interest: None

Disclosure of Funding: None

Keywords: meningioma; spinal cord; minimally invasive surgery

Corresponding author:

Dr Corentin DAULEAC

Hospices Civils de Lyon

Hôpital Neurologique Pierre Wertheimer, Boulevard Pinel, Lyon, France

Phone: +33 (0)4 72 11 89 01

E-mail: corentin.dauleac@chu-lyon.fr

1 **Minimally invasive surgery for intradural spinal meningioma: a new standard? A**
2 **comparative study between minimally invasive and open approaches**

3
4 **Abstract :**

5
6 **Background:** Some authors used minimally invasive surgery (MIS) in the treatment of spinal
7 cord tumor, but these studies had a small sample sizes and mixed extra- and intra-medullary
8 tumors, resulting in confounding biases. The objectives of the present study were to evaluate
9 the effectiveness and safety of MIS for spinal meningioma resection in comparison with open
10 surgery (OS).

11 **Methods:** Consecutive patients with spinal meningioma who received either MIS or OS were
12 included. Data for extent of resection, functional outcome, postoperative morbidity and
13 recurrence were collected.

14 **Results:** A total of 48 patients (with 51 spinal meningiomas) were included. Eighteen
15 underwent MIS and 30 OS. Meningioma volume and location did not differ significantly
16 between groups: tumors were predominantly thoracic (n=39, 76.5%) and voluminous
17 (occupying more than 50% of the spinal canal: n=43, 84.3%). In the MIS group, patients were
18 older (mean age: 66.5 vs. 56.4 years, $p = 0.02$) and more fragile (mean ASA score: 2.0 vs. 1.6,
19 $p = 0.06$). In the MIS group, the surgical procedure was shorter (mean duration: 2.07 vs. 2.56
20 h, $p = 0.04$), blood loss lower (mean: 252 vs. 456 mL, $p = 0.02$), and hospital stay shorter
21 (mean: 6.6 vs. 8.1 days). Surgery improved the modified McCormick scale ($p < 0.0001$)
22 irrespective of the surgical technique. MIS led to no significant differences in extent of
23 resection or postoperative morbidity. Mean follow-up was 46.6 months. At last follow-up,
24 91.7% (n = 44) of patients were free of progression; all cases of tumor progression (n = 4)
25 occurred in the OS group.

26 **Conclusions:** MIS outperformed OS in the management of intradural spinal meningioma,
27 irrespective of location and volume. MIS appears to be particularly suitable for elderly and
28 fragile patients.

29
30 **Abbreviations:**

31 ASA: American Society of Anesthesiologists, CSF: cerebrospinal fluid, GTR: gross total
32 resection, HR: hazard ratio, MIS: minimally invasive surgery, MRI: magnetic resonance
33 imaging, SD: standard deviation, STR: sub-total resection, WHO: World Health Organization.

1
2
3
4
5
6
7
8
9
10
11
12
13
14
15
16
17
18
19
20
21
22
23
24
25

Introduction

Meningiomas represent one of the most frequent histological type of intradural extramedullary tumors in adults,[1] and microsurgical resection is the gold standard for symptomatic meningioma.[2–4] Although the primary objective of these surgeries is the gross-total resection (GTR) to release nervous system compression and avoid recurrence, the secondary objective is to ensure optimal neurological recovery with minimal permanent deficit.

Previous studies on spinal meningiomas reported surgical outcomes using the open approach.[2–9] With the improvement of neurosurgical techniques,[10] recent studies have proposed resection of spinal tumor, including intradural location, using a minimally invasive approach.[11–14] As already demonstrated for degenerative spinal pathologies, minimally invasive surgery (MIS) reduces soft tissue destruction, peri-operative blood loss, postoperative pain, and length of hospital stay.[15,16] Authors have reported the feasibility and use of MIS in the treatment of spinal cord tumors,[11–14,17–20] but these studies had a small sample size,[12–14,18,20] and/or mixed extra and intramedullary tumors in the same cohort.[12,14,17,19,20] However, from a surgical point of view, the management of extramedullary tumors is very different from intramedullary ones, with fewer complications and better outcomes.[21] Moreover, from a methodological point of view, this leads to major confounding bias, potentially explaining why published studies that compared MIS to open techniques failed to find significant differences between these for spinal meningiomas.[22,23]

In the present study, we aimed at determining the safety and effectiveness of MIS for spinal meningiomas resection, comparing the extent of resection, functional outcomes, postoperative morbidity, and recurrence with the open approach.

1
2
3
4
5
6
7
8
9
10
11
12
13
14
15
16
17
18
19
20
21
22
23
24
25

Methods

All procedures were carried out in accordance with the applicable guidelines, in compliance with the 1964 Helsinki declaration, and with the ethical standards of the institutional research committee (IRB: 00011687-2020/44). The present study included consecutive adult patients operated on, from January 2015 to December 2019 in our university hospital, for a de novo intradural extramedullary tumor strictly located in the spinal canal (cervical, thoracic, or lumbar) and with a histological diagnosis of meningioma according to the WHO criteria.[24] A retrospective chart review of prospective data was performed, and meningiomas with paravertebral extension were not included.

The preoperative neurological status were reported according to the McCormick scale.[25] Each patient had a preoperative spinal MRI, including gadolinium injection (**Figure 1a, b**).

The tumor volumes were graded in accordance with the Bayoumi classification whereby the grade of the meningioma is proportional to its volume within the spinal canal; grade I: < 25% of the spinal canal, grade II: between 25% and 50% of the spinal canal, grade III: between 50% and 75% of the spinal canal, and grade IV: > 75% of the spinal canal.[26] Bayoumi classification also give information about the insertion of the meningioma on the dura by its appendix letter: “a” means that meningioma is ventral, “b” is dorsal, and “c” is lateral.

MIS or the classic open approach was used according to the neurosurgeon’s habitual practice (the allocation of surgery – MIS vs open surgery – was done randomly during the first preoperative consultation, according to the senior neurosurgeon). Neurosurgeons who practiced MIS were all at the top of the MIS learning curve (more than 5 years of experience in intradural tumor resection using MIS). MIS was performed when the meningioma did not exceed 2 vertebral levels in height. For the MIS (**Supplementary material and**

1 **Supplementary Figure 1**), the skin incision was paramedian, an expandable tubular retractor
2 (Quadrant retractor Medtronic Sofamor Danek, Memphis, TN, USA) or nonexpandable
3 retractor (METRx system, Medtronic Sofamor Danek) was used according to the height of the
4 meningioma (**Figure 2a, b, c**), and laminas were drilled (**Figure 2d**) over the entire length of
5 the meningioma (**Figure 2e**).[27] The open approach considered all approach without the use
6 of tubular retractor (bilateral exposure with laminectomy, bilateral exposure with laminotomy,
7 unilateral laminectomy, and unilateral laminotomy). For both approaches, the dura mater was
8 opened on the midline and then suspended. The peri-spinal cisterns were drained,[28] and the
9 meningioma was removed under a surgical microscope. The amount of blood loss was
10 recorded, the duration of the surgery and hospitalization were collected. The tumor resection
11 was categorized as follows: 1) GTR, when resection was macroscopically complete and no
12 tumor remnant was detectable on the postoperative MRI; 2) sub-total resection (STR), when a
13 near-complete resection was achieved with remnant detectable on the postoperative MRI. The
14 Simpson grading was also used to define the quality of the resection.[29]

15 Patient follow-up consisted of clinical examination and spinal MRI conducted at 3 months
16 and 1 year postoperatively (**Figure 1c, d**). After this period, the follow-up was performed
17 annually for at least 5 years, associated with a spinal cord MRI. After this period, the follow-
18 up was performed every 2 years for 5 years. After 10 years follow-up, for patients with a
19 gross-total resection, considering that it is very slowly growing tumor, the follow-up is then
20 stopped. For the present study, the last clinical examination and spinal cord MRI were
21 considered for analysis.

22

23 *Statistical analysis*

24 Categorical variables were expressed as number (n) and percentage. Quantitative variables
25 were expressed as means \pm standard deviation (SD). Categorical variables were compared

1 using the Chi squared test or Fisher's exact test (when the conditions of application of Chi
2 squared test were not met), and continuous variables were compared using the Student t-test
3 or Wilcoxon test (when the distribution was not normal) for continuous variables. The
4 hypothesis of normal distribution of continuous variables was tested using the Shapiro and
5 graphically confirmed with a histogram. The progression free survival (PFS) was defined by
6 the interval between date of diagnosis and that of first progression (or recurrence) or last
7 known status. Description of PFS was estimated by the Kaplan-Meier product limit method,
8 and the effect of different parameters was assessed using the log-rank test. Statistical analyses
9 were performed using the web-based statistical tool (<https://biostatv.sentiweb.fr>),
10 significance was set at $p < 0.05$.

11

12

13 **Results**

14 *Preoperative clinical and radiological findings*

15 During the study period, 51 spinal meningiomas, in 48 patients required surgical
16 management. Three patients harbored two meningiomas at different spine levels. The mean
17 \pm SD age of the population was 60.2 ± 14.9 years at the time of surgery. There were 39 female
18 patients (81.2%). Preoperatively, 5 patients (10.4%) were grade I according to the
19 McCormick scale, 14 (29.2%) grade II, 16 (33.3%) grade III, 12 (25.0%) grade IV, and 1 was
20 grade V (**Table 1**).

21 There were 11 (21.6%) meningiomas located at the cervical level (4 were between C0-
22 C2, and 7 between C3-C7), 39 (75.0%) at the thoracic level (23 were between T1-T6, and 16
23 between T7-T12), and 1 (1.9%) was at the lumbar spine level. According to the volume
24 classification proposed by Bayoumi et al.,[26] 3 (5.9%) meningioma was grade I, 5 (9.7%)
25 was grade II, 13 (25.5%) were grade III, 30 (58.9%) were grade IV (Table 1). There was a

1 significant correlation between the volume of the meningioma and the severity of the
2 neurological examination (Pearson test, ρ : 0.34, CI95% [0.0715; 0.5631] $p=0.01$). Edema was
3 found in 37 patients, and syringomyelia in 2 patients. Edema and syringomyelia were not
4 significantly associated with the severity of the neurological examination ($p>0.5$).

5

6 *Surgical management: MIS versus open surgery*

7 Eighteen (37.5%) patients underwent MIS, and 30 (62.5%) open surgery. MIS was performed
8 for 17 (89.4%) thoracic, 1 (5.3%) cervical, and 1 (5.3%) lumbar meningiomas, while open
9 surgery was performed for 22 (68.8%) thoracic and 10 (31.2%) cervical meningiomas.
10 Concerning the latero-lateral meningioma extension, 17 (94.4%) patients who underwent
11 MIS, and 25 (83.3%) patients who had open surgery, presented with a meningioma filling
12 more than 50% of the spinal canal (\geq grade III according to the Bayoumi scale, $p>0.5$).
13 Concerning the cranio-caudal meningioma extension, there was also no difference between
14 groups (1.1 ± 0.3 vertebral level in the MIS group *versus* 1.2 ± 0.2 in the open group, $p>0.5$).
15 Patients operated with MIS were older (66.5 ± 14.1 years) than those operated with the open
16 technique (56.4 ± 14.3 years, $p=0.02$). There is a trend towards a higher ASA scale in patients
17 who had a MIS (2 [1 – 3]) than in patients who had open surgery (2 [1 – 2], $p=0.06$). MIS was
18 significantly shorter (2.07 ± 0.66 hours) than open surgery (2.56 ± 1.08 hours, $p=0.04$). Blood
19 loss was significantly lower with a MIS (252.7 ± 215.2 mL) than with an open approach
20 (456.7 ± 396.25 mL, $p=0.02$; **Table 2**). No significant difference regarding the extent of
21 resection was reported according to the type of surgical approach. One patient had a STR
22 (Simpson 4) in the MIS group, while 3 patients had a STR (Simpson 4) in the open surgery
23 group ($p>0.5$). With the exception of meningiomas that were partially resected, all other
24 meningiomas were classified Simpson 2 (GTR of the tumor with coagulation of dural
25 attachments).

1 The histopathological analysis found meningioma grade 1 according to the WHO
2 classification[24] in all cases.

3

4 *Postoperative morbidity*

5 Postoperative morbidities are reported in Table 2. There no significant difference in
6 complications between groups: there were no patients with infectious meningitis in the MIS
7 group, while there was 1 (3.3%) in the open surgery group ($p>0.5$); 1 (5.5%) patient had CSF
8 leakage in the MIS group, while there were none in the open surgery group ($p>0.5$); and 2
9 (11.1%) patients had an immediate neurological worsening in the MIS group, while there
10 were 4 (13.3%) in the open surgery group ($p>0.5$). During the postoperative course, no
11 patients experienced venous thromboembolic complication.

12

13 *Functional outcomes*

14 The mean (\pm SD) follow-up was 46.6 (\pm 14.2) months. At last follow-up, 34 patients
15 (70.8%) were grade I according to the McCormick scale, 12 (25.0%) were grade II, 1 (2.1%)
16 was grade IV, and 1 (2.1%) were grade IV. Irrespective of the surgical technic, surgery
17 significantly improved the results of neurological examination with spinal cord meningioma:
18 there were significantly more patients with McCormick grade I in the postoperative course
19 ($n=34$, 70.8%) than in preoperative ($n=5$, 10.4% $p<0.0001$). Postoperatively, patients
20 significantly improved their McCormick scale by a median of +1 [1 – 3] grade ($p<0.0001$): 5
21 (10.4%) patients improved their McCormick scale by 3 grades, 18 (37.5%) by 2 grades, 16
22 (33.3%) by 1 grade, and 9 (18.8%) did not improve (but 5 of these were already grade I
23 according to the McCormick scale). The neurological recovery did not differ between MIS
24 and open surgery ($p>0.5$). In the present study, there was no significant association between

1 neurological recovery and preoperative McCormick scale ($p>0.5$), or the volume of the
2 meningioma according to the Bayoumi scale ($p>0.5$).

3 There was a trend towards shorter hospital stay in the MIS group (mean \pm SD: 6.6 ± 4.0
4 days) than in the open surgery group (8.1 ± 5.6 days; $p=0.3$).

5

6 *Progression-free survival*

7 At last follow-up, 44 (91.7%) patients were free of progression; 4 (8.3%) patients
8 experienced a recurrence. The mean (SD) time to recurrence was 63.6 (± 20.4) months, and
9 they all underwent open surgery. One patient (25.0%) had a GTR, and 3 (75.0%) a STR.
10 There were significantly more patients with progression when the resection was incomplete
11 than when a GTR was performed (75.0% versus 2.3%, HR = 83.06, 95%CI [3.9; 6397.8],
12 $p<0.0001$, **Figure 3**). However, no significant association was reported between the
13 recurrence and the location of the meningioma ($p=0.2$), or the volume of the meningioma
14 ($p>0.5$). Of the 4 patients with a recurrence, 3 underwent a new surgical procedure (1 resulted
15 in a GTR, and 2 in a new STR, due to a foraminal tumor remnant), and 1 had a strict follow-
16 up (due to the small volume of tumor remnant).

17

18

19 **Discussion**

20 In the present study, we found that MIS allows GTR of large meningioma without
21 spinal cord impairment or postoperative deficit. MIS enables significantly lower blood loss
22 and reduces surgery time, and hospital stay. MIS appears to be suitable for elderly and fragile
23 patients. Postoperative morbidities were not significantly different between MIS and open
24 surgery, making MIS a safe and effective procedure.

25

1 The present study demonstrates the effectiveness of MIS for spinal meningioma
2 resection. Notably, more than three-quarters of patients who received MIS presented initially
3 with a meningioma filling more than 75% of the spinal canal, and, although MIS provides a
4 limited corridor, GTR was attained in all-but-one patient. GTR is a recognized as a prognostic
5 factor to avoid recurrence, as reported for a variety of spinal tumors,[2,30] but spinal
6 meningioma recurrence is known to be uncommon (using the open approach).[8,31] To
7 qualify the quality of meningioma resection, the Simpson scale is usually used.[29] However,
8 this classification was initially created for cranial meningiomas;[29] in spinal meningiomas,
9 the Simpson 1 resection (complete resection including dura and bone) is often unattainable.
10 Due to the vast majority of lateral and anterior insertion of spinal meningiomas on the dura
11 mater, resection Simpson 2 (GTR of the tumor with coagulation of dural attachment) is
12 usually performed. In the present study, patients with Simpson 2 resection did not experience
13 any recurrence. Although some authors have reported grade> Simpson 1 as a prognostic
14 factor for recurrence,[32,33] our results are more nuanced and confirmed the importance of
15 the tumor GTR.[34,35]

16

17 The results of the present study demonstrate that MIS is a safe procedure. Although
18 these large tumors crushing the spinal cord were gross-total resected using MIS, we did not
19 report a greater rate of neurological impairment than with an open approach. In the total
20 population all-but-four patients (all four had open surgery) experienced an improvement of
21 their neurological status after surgery, suggesting that even patients suffering from severe
22 preoperative neurological deficits could recover normal motor function and ability to walk
23 after surgery – as reported previously.[36] There were, however, certain differences: for
24 example the patients who received MIS were older and had a greater ASA score, they also
25 had a lower blood loss and surgical time. This is of interest, as, in a study that reported on the

1 open approach, the factors leading to neurological deterioration revealed that in particular
2 elderly patients were affected.[31] Other studies focused on elderly patients concluded that
3 spinal meningioma surgery should always be attempted in elderly patients with a low or
4 moderate anesthesiological risk, since no mortality or significant morbidity occurred.[37,38]
5 Nevertheless, scientific community recognizes that elderly subjects are fragile patients, for
6 whom postoperative complications can be more morbid.[39] Therefore, MIS could be an
7 interesting choice for the fragile and elderly.

8 We also demonstrated that postoperative morbidities in patients who underwent MIS
9 were not more frequent than in those patients who had the open approach. This further
10 supports the safe character of this type of procedure, that has been adopted for intradural
11 surgeries to reduce immediate postoperative morbidity (CSF leakage, infections, symptomatic
12 epidural hematoma etc.).[22,23,40] Some authors explain this by principle of tubular
13 surgery:[11,40] the tubular surgical corridor allows the scar tissue to close after tube removal,
14 avoiding dead space in which CSF or blood could accumulate.[40] Also, the limited skin
15 incision prevents introduction of skin flora that might impair wound healing or even produce
16 a wound infection, either of which might perpetuate a CSF leak.[11] MIS procedures offer the
17 advantage of decreased damage to adjacent soft tissue, resulting in decreased postoperative
18 pain and discomfort. This advantage is shown by multiple studies, including that by Fan et
19 al.,[41] in which multifidus atrophy in magnetic resonance images was relatively reduced in
20 MIS compared with open procedures. Moreover, several studies[42,43] performed a
21 biomechanical comparison between open surgery and MIS and demonstrated that the open
22 surgery produced greater changes in flexion, extension, and axial rotation when compared
23 with the minimally invasive technique. However, it is also of note that there is a learning
24 curve for MIS. MIS can be initially challenging for neurosurgeons (without MIS experience)
25 due to the potential limited angular visualization during the surgical procedure, and the

1 narrow surgical corridor. Nevertheless, a recent study had demonstrated that a 50% learning
2 curve is achieved by approximately 12 cases and 90% by 25-40 cases.[44] Surgical aptitude,
3 manual dexterity of the trainee, and structured training are important factors in reducing the
4 learning curve, and therefore to ensure the safety of spinal meningioma resection with MIS.

5 Another point to consider is that the safety of the procedure allows greater efficiency.
6 For instance, the lower blood loss and a shorter surgical time, MIS results in simpler
7 postoperative monitoring, and, therefore, in a reduction of the hospital stay.[22,23,40] This is
8 illustrated in a recent U.S. study: the total cost of care for patients with intradural
9 extramedullary tumors was reduced by 25% by performing MIS.[40] Even though MIS
10 required dedicated instruments and surgical microscope, its cost-efficiency make it suitable
11 for many care-givers in the long-term.[40]

12
13 The present study has several strengths. For instance, only adult patients with spinal
14 meningiomas were included avoiding bias related to age and other histological intramedullary
15 tumors, as proposed in several studies.[12,14,17,19,20,23,45] To the best of our knowledge,
16 the present study represented the largest dedicated comparison between open approach and
17 MIS for spinal meningiomas. Although meningioma characteristics (size, volume, etc.) were
18 not different between MIS and open surgery, the present study is however limited by its
19 nonrandomized design. Moreover, the retrospective design of the study can lead to a bias in
20 estimating recurrence. Nevertheless, meningioma being a slowly growing tumor and often
21 completely resected, with a low rate of recurrence, the ranking bias is probably not
22 underestimated, even if the follow-up time is different between patients.

23

24 **Conclusion**

1 In the present study, MIS was found to be a safe and effective procedure for the
2 resection of voluminous spinal meningiomas, irrespective of their spinal location. The results
3 highlight the advantages of MIS for spinal meningiomas, and could contribute through future
4 clinical trials to elevate MIS to the gold standard for intradural extramedullary tumors.

5 6 7 **References**

- 8 [1] Duong LM, McCarthy BJ, McLendon RE, Dolecek TA, Kruchko C, Douglas LL, et al.
9 Descriptive epidemiology of malignant and nonmalignant primary spinal cord, spinal
10 meninges, and cauda equina tumors, United States, 2004-2007. *Cancer* 2012;118:4220-
11 7. <https://doi.org/10.1002/cncr.27390>.
- 12 [2] Klekamp J, Samii M. Surgical results for spinal meningiomas. *Surg Neurol*
13 1999;52:552-62.
- 14 [3] Bret P, Lecuire J, Lapras C, Deruty R, Dechaume JP, Assaad A. [Intraspinal
15 meningiomas. A series of 60 cases]. *Neuro-Chirurgie* 1976;22:5-22.
- 16 [4] Solero CL, Fornari M, Giombini S, Lasio G, Oliveri G, Cimino C, et al. Spinal
17 meningiomas: review of 174 operated cases. *Neurosurgery* 1989;25:153-60.
- 18 [5] Levy WJ, Bay J, Dohn D. Spinal cord meningioma. *Journal of Neurosurgery*
19 1982;57:804-12. <https://doi.org/10.3171/jns.1982.57.6.0804>.
- 20 [6] Roux FX, Nataf F, Pinaudeau M, Borne G, Devaux B, Meder JF. Intraspinial
21 meningiomas: review of 54 cases with discussion of poor prognosis factors and modern
22 therapeutic management. *Surgical Neurology* 1996;46:458-63; discussion 463-464.
23 [https://doi.org/10.1016/s0090-3019\(96\)00199-1](https://doi.org/10.1016/s0090-3019(96)00199-1).
- 24 [7] King AT, Sharr MM, Gullan RW, Bartlett JR. Spinal meningiomas: a 20-year review.
25 *British Journal of Neurosurgery* 1998;12:521-6.
26 <https://doi.org/10.1080/02688699844367>.
- 27 [8] Schaller B. Spinal meningioma: relationship between histological subtypes and surgical
28 outcome? *Journal of Neuro-Oncology* 2005;75:157-61. <https://doi.org/10.1007/s11060-005-1469-4>.
- 30 [9] Bayoumi AB, Laviv Y, Karaali CN, Ertlav K, Kepoglu U, Toktas ZO, et al. Spinal
31 meningiomas: 61 cases with predictors of early postoperative surgical outcomes. *J*
32 *Neurosurg Sci* 2020;64:446-51. <https://doi.org/10.23736/S0390-5616.17.04102-9>.
- 33 [10] Sciubba DM, Liang D, Kothbauer KF, Noggle JC, Jallo GI. The evolution of
34 intramedullary spinal cord tumor surgery. *Neurosurgery* 2009;65:84-91; discussion 91-
35 92. <https://doi.org/10.1227/01.NEU.0000345628.39796.40>.
- 36 [11] Tredway TL, Santiago P, Hrubes MR, Song JK, Christie SD, Fessler RG. Minimally
37 invasive resection of intradural-extramedullary spinal neoplasms. *Neurosurgery*
38 2006;58:ONS52-58; discussion ONS52-58.
39 <https://doi.org/10.1227/01.neu.0000192661.08192.1c>.
- 40 [12] Haji FA, Cenic A, Crevier L, Murty N, Reddy K. Minimally invasive approach for the
41 resection of spinal neoplasm. *Spine* 2011;36:E1018-1026.
42 <https://doi.org/10.1097/BRS.0b013e31820019f9>.
- 43 [13] Mannion RJ, Nowitzke AM, Efendy J, Wood MJ. Safety and efficacy of intradural
44 extramedullary spinal tumor removal using a minimally invasive approach.

- 1 Neurosurgery 2011;68:208–16; discussion 216.
2 <https://doi.org/10.1227/NEU.0b013e318207b3c7>.
- 3 [14] Nzokou A, Weil AG, Shedid D. Minimally invasive removal of thoracic and lumbar
4 spinal tumors using a nonexpandable tubular retractor. *J Neurosurg Spine* 2013;19:708–
5 15. <https://doi.org/10.3171/2013.9.SPINE121061>.
- 6 [15] Arts MP, Brand R, van den Akker ME, Koes BW, Bartels RH, Tan W, et al. Tubular
7 Discectomy vs Conventional Microdiscectomy for the Treatment of Lumbar Disk
8 Herniation: 2-Year Results of a Double-Blind Randomized Controlled Trial.
9 *Neurosurgery* 2011;69:135–44. <https://doi.org/10.1227/NEU.0b013e318214a98c>.
- 10 [16] Rasouli MR, Rahimi-Movaghar V, Shokraneh F, Moradi-Lakeh M, Chou R. Minimally
11 invasive discectomy versus microdiscectomy/open discectomy for symptomatic lumbar
12 disc herniation. *Cochrane Database of Systematic Reviews* 2014.
13 <https://doi.org/10.1002/14651858.CD010328.pub2>.
- 14 [17] Dahlberg D, Halvorsen CM, Lied B, Helseth E. Minimally invasive microsurgical
15 resection of primary, intradural spinal tumours using a tubular retraction system. *British*
16 *Journal of Neurosurgery* 2012;26:472–5.
17 <https://doi.org/10.3109/02688697.2011.644823>.
- 18 [18] Iacoangeli M, Gladi M, Di Rienzo, Dobran M, Alvaro L, Nocchi N, et al. Minimally
19 invasive surgery for benign intradural extramedullary spinal meningiomas: experience of
20 a single institution in a cohort of elderly patients and review of the literature. *CIA*
21 2012;557. <https://doi.org/10.2147/CIA.S38923>.
- 22 [19] Gandhi RH, German JW. Minimally invasive approach for the treatment of intradural
23 spinal pathology. *FOC* 2013;35:E5. <https://doi.org/10.3171/2013.5.FOCUS13163>.
- 24 [20] Afathi M, Peltier E, Adetchessi T, Graillon T, Dufour H, Fuentes S. Minimally invasive
25 transmuscular approach for the treatment of benign intradural extramedullary spinal cord
26 tumours: Technical note and results. *Neurochirurgie* 2015;61:333–8.
27 <https://doi.org/10.1016/j.neuchi.2015.05.001>.
- 28 [21] Dauleac C, Vasiljevic A, Berhouma M. How to differentiate spinal cord
29 hemangiopericytoma from common spinal cord tumor? *Neurochirurgie* 2020;66:53–5.
30 <https://doi.org/10.1016/j.neuchi.2019.10.012>.
- 31 [22] Raygor KP, Than KD, Chou D, Mummaneni PV. Comparison of minimally invasive
32 transspinous and open approaches for thoracolumbar intradural-extramedullary spinal
33 tumors. *Neurosurg Focus* 2015;39:E12. <https://doi.org/10.3171/2015.5.FOCUS15187>.
- 34 [23] Lu DC, Chou D, Mummaneni PV. A comparison of mini-open and open approaches for
35 resection of thoracolumbar intradural spinal tumors. *Journal of Neurosurgery Spine*
36 2011;14:758–64. <https://doi.org/10.3171/2011.1.SPINE09860>.
- 37 [24] Louis DN, Perry A, Reifenberger G, von Deimling A, Figarella-Branger D, Cavenee
38 WK, et al. The 2016 World Health Organization Classification of Tumors of the Central
39 Nervous System: a summary. *Acta Neuropathol* 2016;131:803–20.
40 <https://doi.org/10.1007/s00401-016-1545-1>.
- 41 [25] McCormick PC, Torres R, Post KD, Stein BM. Intramedullary ependymoma of the
42 spinal cord. *J Neurosurg* 1990;72:523–32. <https://doi.org/10.3171/jns.1990.72.4.0523>.
- 43 [26] Bayoumi AB, Laviv Y, Yokus B, Efe IE, Toktas ZO, Kilic T, et al. Proposal of a new
44 radiological classification system for spinal meningiomas as a descriptive tool and
45 surgical guide. *Clin Neurol Neurosurg* 2017;162:118–26.
46 <https://doi.org/10.1016/j.clineuro.2017.10.001>.
- 47 [27] Dauleac C, Leroy H-A, Assaker R. Minimally Invasive Approach for Dorsal Arachnoid
48 Web: 2-Dimensional Operative Video. *Oper Neurosurg (Hagerstown)* 2021;21:E549–50.
49 <https://doi.org/10.1093/ons/opab297>.

- 1 [28] Dauleac C, Jacquesson T, Mertens P. Anatomy of the human spinal cord arachnoid
2 cisterns: applications for spinal cord surgery. *J Neurosurg Spine* 2019;1–8.
3 <https://doi.org/10.3171/2019.4.SPINE19404>.
- 4 [29] Simpson D. The recurrence of intracranial meningiomas after surgical treatment. *J*
5 *Neurol Neurosurg Psychiatry* 1957;20:22–39. <https://doi.org/10.1136/jnnp.20.1.22>.
- 6 [30] Klekamp J. Spinal ependymomas. Part 2: Ependymomas of the filum terminale.
7 *Neurosurg Focus* 2015;39:E7. <https://doi.org/10.3171/2015.5.FOCUS15151>.
- 8 [31] Sandalcioglu IE, Hunold A, Müller O, Bassiouni H, Stolke D, Akgari S. Spinal
9 meningiomas: critical review of 131 surgically treated patients. *European Spine Journal:*
10 *Official Publication of the European Spine Society, the European Spinal Deformity*
11 *Society, and the European Section of the Cervical Spine Research Society*
12 2008;17:1035–41. <https://doi.org/10.1007/s00586-008-0685-y>.
- 13 [32] Raco A, Pesce A, Toccaceli G, Domenicucci M, Miscusi M, Delfini R. Factors Leading
14 to a Poor Functional Outcome in Spinal Meningioma Surgery: Remarks on 173 Cases.
15 *Neurosurgery* 2017;80:602–9. <https://doi.org/10.1093/neuros/nyw092>.
- 16 [33] Nakamura M, Tsuji O, Fujiyoshi K, Hosogane N, Watanabe K, Tsuji T, et al. Long-term
17 surgical outcomes of spinal meningiomas. *Spine* 2012;37:E617–623.
18 <https://doi.org/10.1097/BRS.0b013e31824167f1>.
- 19 [34] Riad H, Knafo S, Segnarbieux F, Lonjon N. Spinal meningiomas: surgical outcome and
20 literature review. *Neuro-Chirurgie* 2013;59:30–4.
21 <https://doi.org/10.1016/j.neuchi.2012.10.137>.
- 22 [35] Setzer M, Vatter H, Marquardt G, Seifert V, Vrionis FD. Management of spinal
23 meningiomas: surgical results and a review of the literature. *Neurosurgical Focus*
24 2007;23:E14. <https://doi.org/10.3171/FOC-07/10/E14>.
- 25 [36] Haegelen C, Morandi X, Riffaud L, Amlashi SFA, Leray E, Brassier G. Results of spinal
26 meningioma surgery in patients with severe preoperative neurological deficits. *European*
27 *Spine Journal: Official Publication of the European Spine Society, the European Spinal*
28 *Deformity Society, and the European Section of the Cervical Spine Research Society*
29 2005;14:440–4. <https://doi.org/10.1007/s00586-004-0809-y>.
- 30 [37] Morandi X, Haegelen C, Riffaud L, Amlashi S, Adn M, Brassier G. Results in the
31 operative treatment of elderly patients with spinal meningiomas. *Spine* 2004;29:2191–4.
32 <https://doi.org/10.1097/01.brs.0000141173.79572.40>.
- 33 [38] Sacko O, Haegelen C, Mendes V, Brenner A, Sesay M, Brauge D, et al. Spinal
34 meningioma surgery in elderly patients with paraplegia or severe paraparesis: a
35 multicenter study. *Neurosurgery* 2009;64:503–9; discussion 509–510.
36 <https://doi.org/10.1227/01.NEU.0000338427.44471.1D>.
- 37 [39] Kim S, Han H-S, Jung H, Kim K, Hwang DW, Kang S-B, et al. Multidimensional frailty
38 score for the prediction of postoperative mortality risk. *JAMA Surg* 2014;149:633–40.
39 <https://doi.org/10.1001/jamasurg.2014.241>.
- 40 [40] Fontes RBV, Wewel JT, O’Toole JE. Perioperative Cost Analysis of Minimally Invasive
41 vs Open Resection of Intradural Extramedullary Spinal Cord Tumors. *Neurosurgery*
42 2016;78:531–9. <https://doi.org/10.1227/NEU.0000000000001079>.
- 43 [41] Fan S, Hu Z, Zhao F, Zhao X, Huang Y, Fang X. Multifidus muscle changes and clinical
44 effects of one-level posterior lumbar interbody fusion: minimally invasive procedure
45 versus conventional open approach. *Eur Spine J* 2010;19:316–24.
46 <https://doi.org/10.1007/s00586-009-1191-6>.
- 47 [42] Ogden AT, Bresnahan L, Smith JS, Natarajan R, Fessler RG. Biomechanical comparison
48 of traditional and minimally invasive intradural tumor exposures using finite element
49 analysis. *Clin Biomech (Bristol, Avon)* 2009;24:143–7.
50 <https://doi.org/10.1016/j.clinbiomech.2008.11.005>.

- 1 [43] Xie T, Qian J, Lu Y, Chen B, Jiang Y, Luo C. Biomechanical comparison of
2 laminectomy, hemilaminectomy and a new minimally invasive approach in the surgical
3 treatment of multilevel cervical intradural tumour: a finite element analysis. *Eur Spine J*
4 2013;22:2719–30. <https://doi.org/10.1007/s00586-013-2992-1>.
- 5 [44] Sharif S, Afsar A. Learning Curve and Minimally Invasive Spine Surgery. *World*
6 *Neurosurg* 2018;119:472–8. <https://doi.org/10.1016/j.wneu.2018.06.094>.
- 7 [45] Formo M, Halvorsen CM, Dahlberg D, Brommeland T, Fredø H, Hald J, et al.
8 Minimally Invasive Microsurgical Resection of Primary, Intradural Spinal Tumors is
9 Feasible and Safe: A Consecutive Series of 83 Patients. *Neurosurgery* 2018;82:365–71.
10 <https://doi.org/10.1093/neuros/nyx253>.

11
12
13 **Table 1:** Patient characteristics

14 **Table 2:** Comparison of population, surgical outcomes and perioperative morbidities between
15 open and minimally invasive approaches.

16 **Figure 1:** a and b: Preoperative MRI showing a spinal cord meningioma Bayoumi grade IV,
17 respectively on sagittal T2-weighted image and axial T1 with gadolinium enhancement. c and
18 d: Postoperative MRI after gross-total resection of spinal cord meningioma using minimally
19 invasive approach, respectively on sagittal and axial T2-weighted images.

20 **Figure 2:** a, b and c: MIS installation with tubular retractor and expendable tubular retractor.
21 d: Drilling of laminae over the entire length of the meningioma. e: Dura mater is exposed
22 bilaterally.

23 **Figure 3:** Progression-free survival (PFS) in patients with spinal cord meningioma
24 determined using the Kaplan-Meier method. PFS according to the quality of the resection
25 (gross-total resection (GTR, n = 44) *versus* incomplete resection, n = 4).

Preoperative

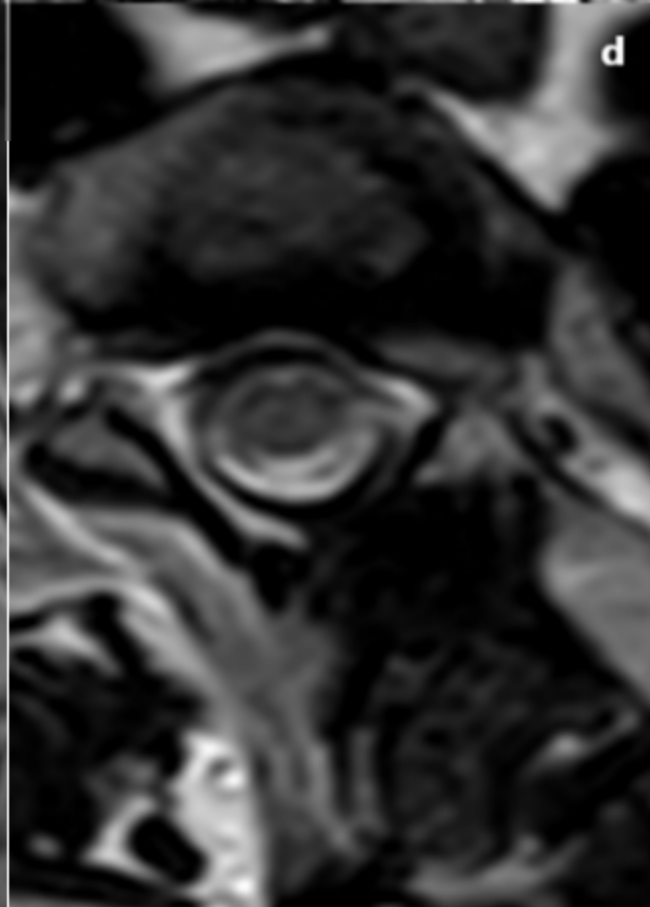
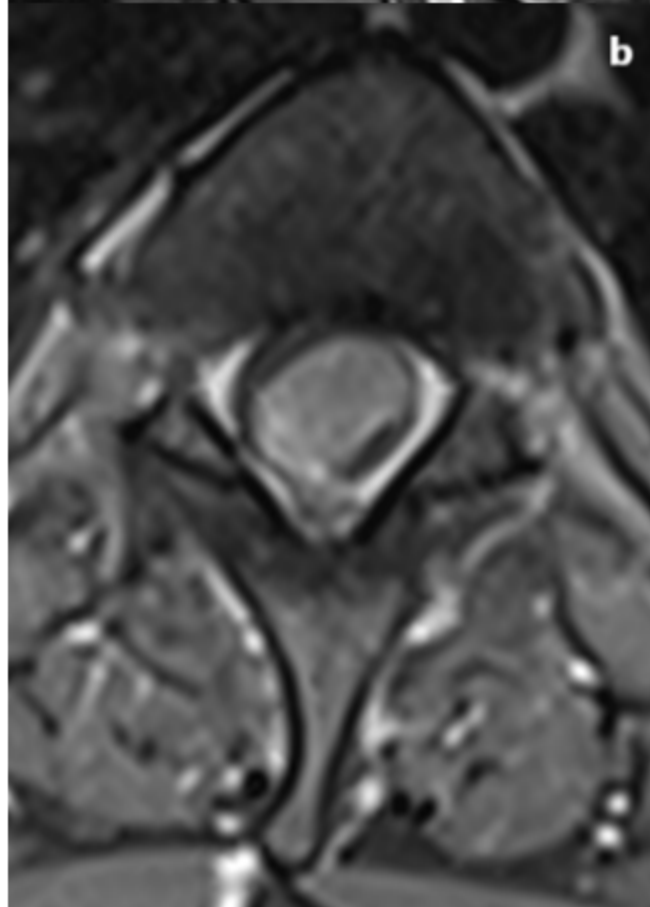
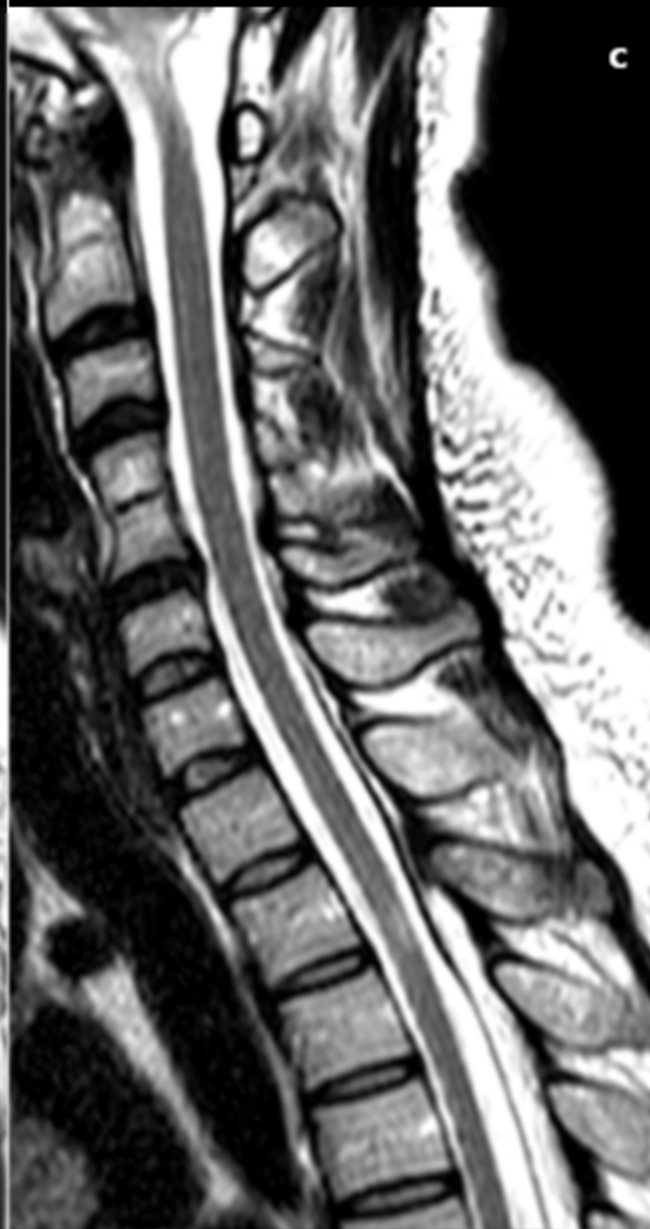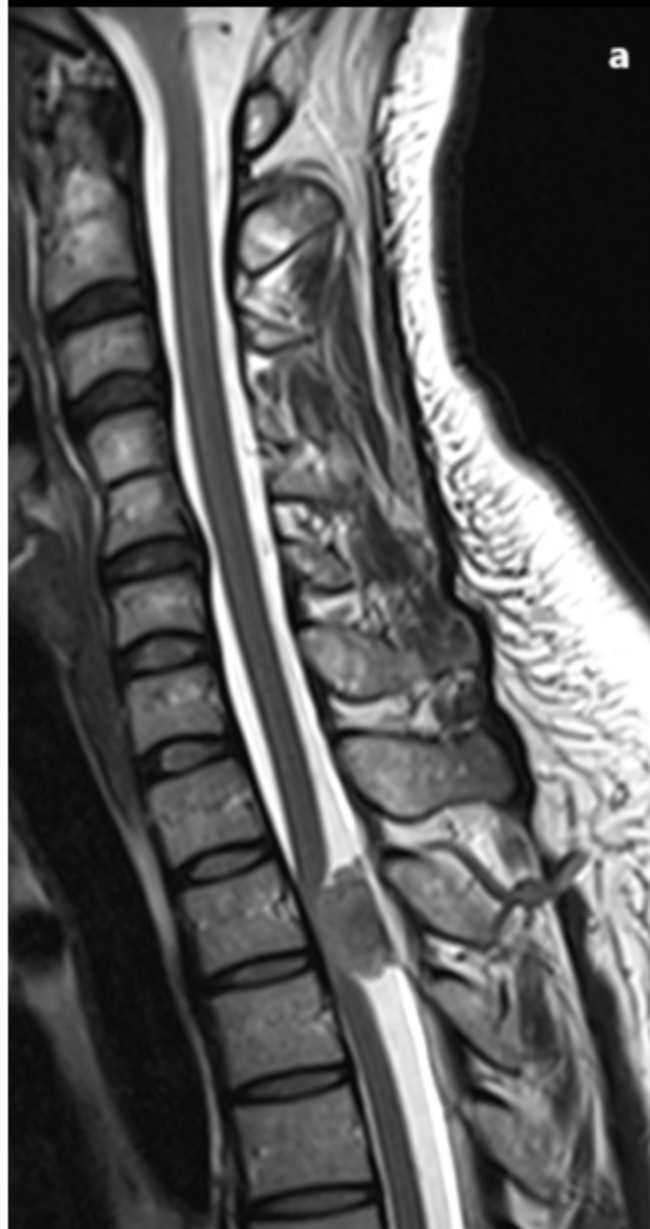
Postoperative

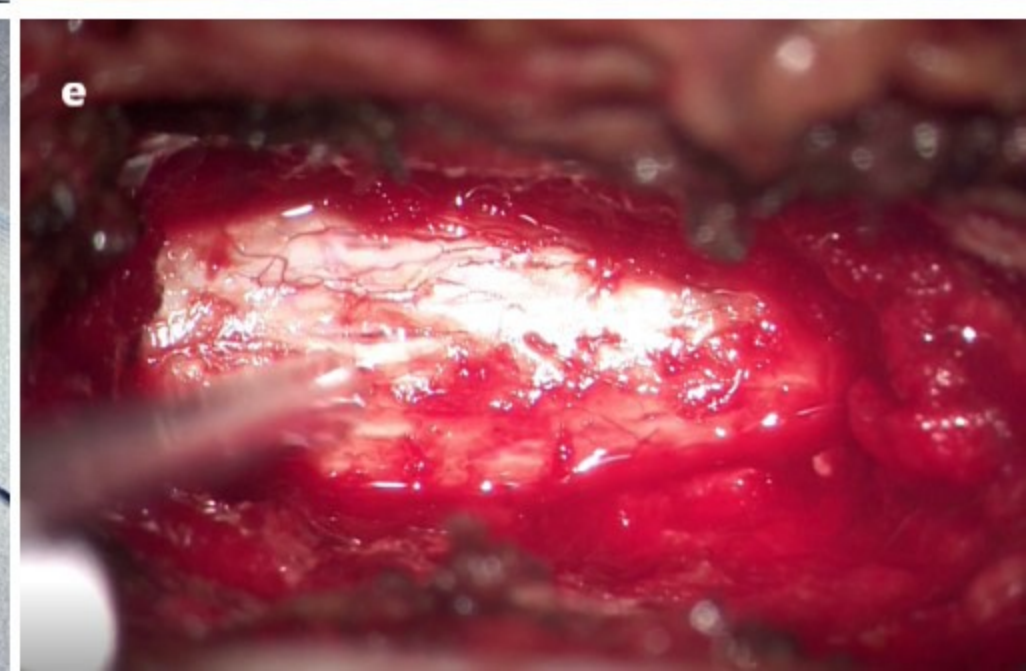
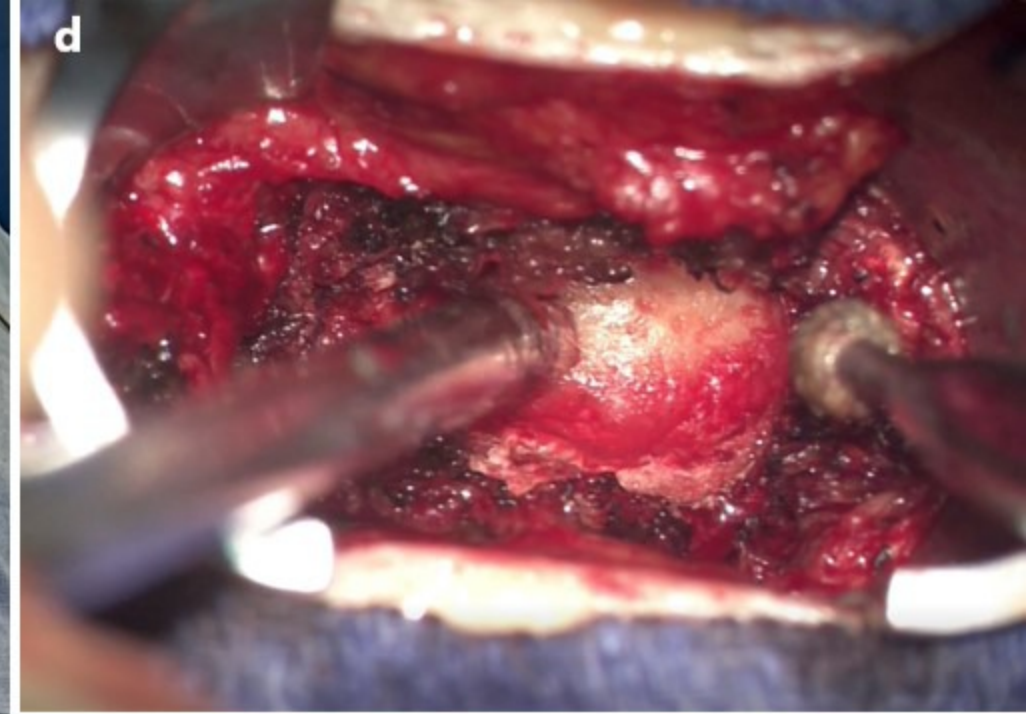
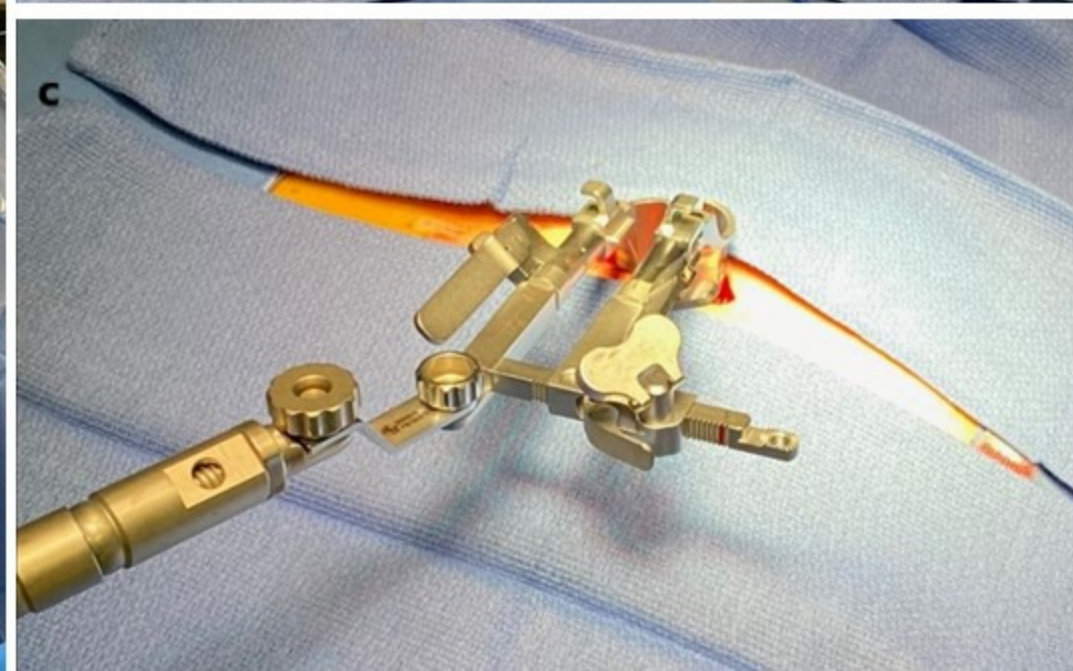
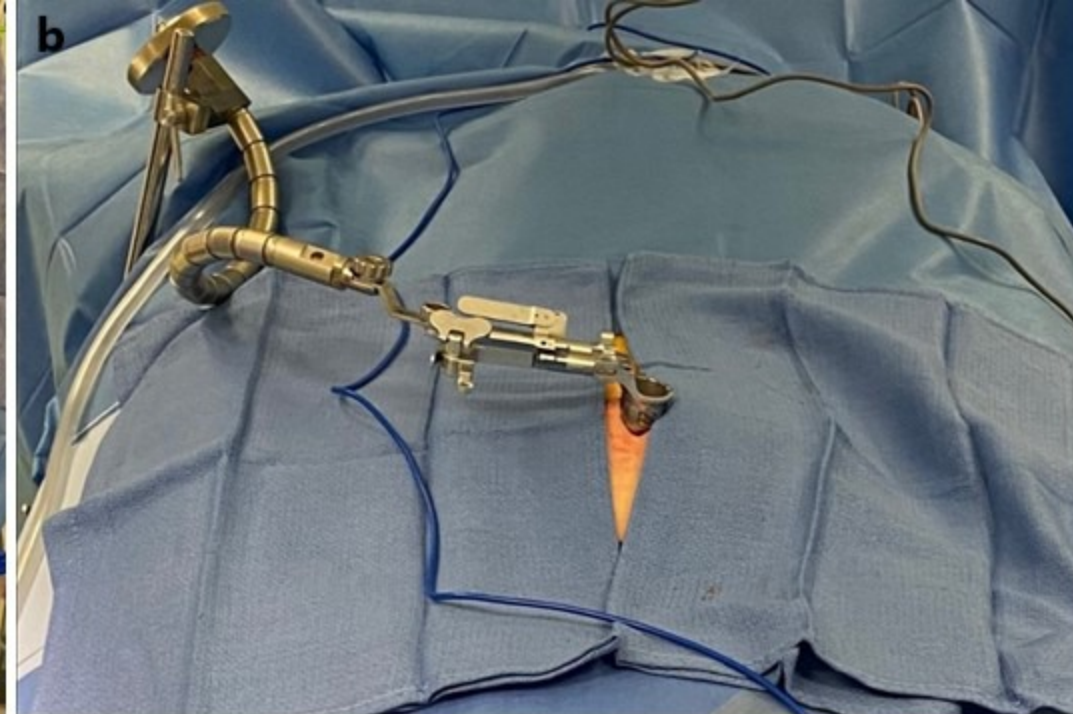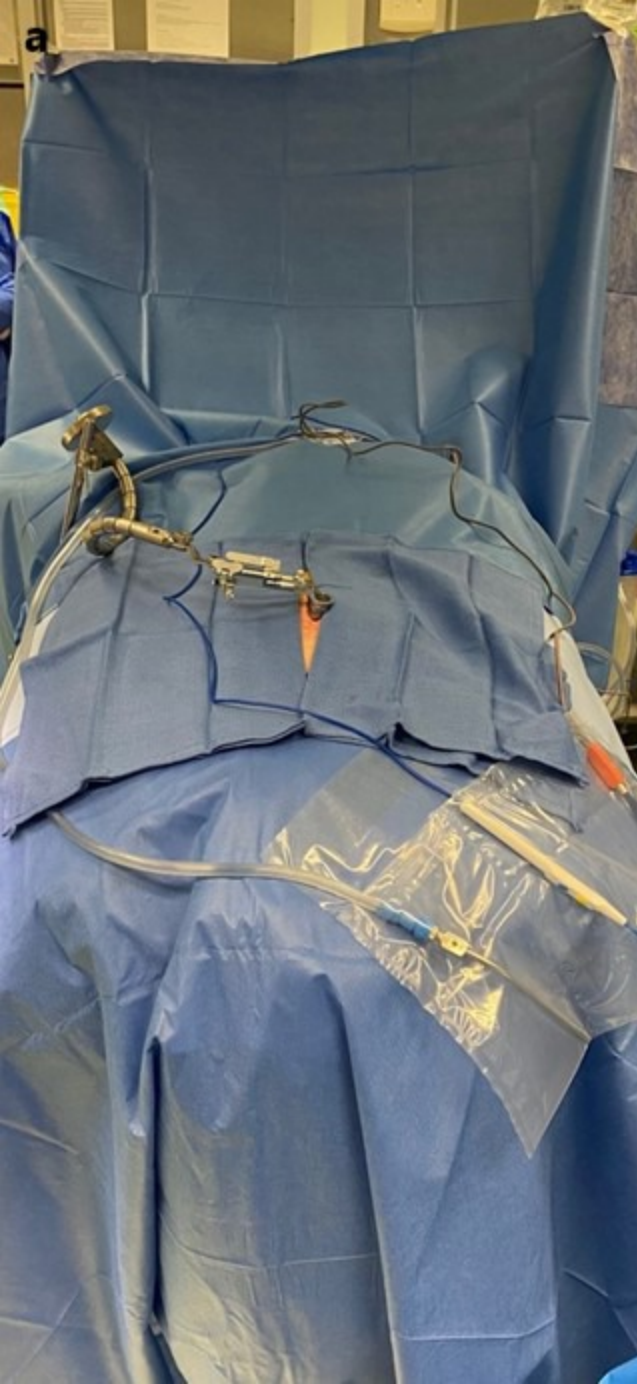a

c

b

d





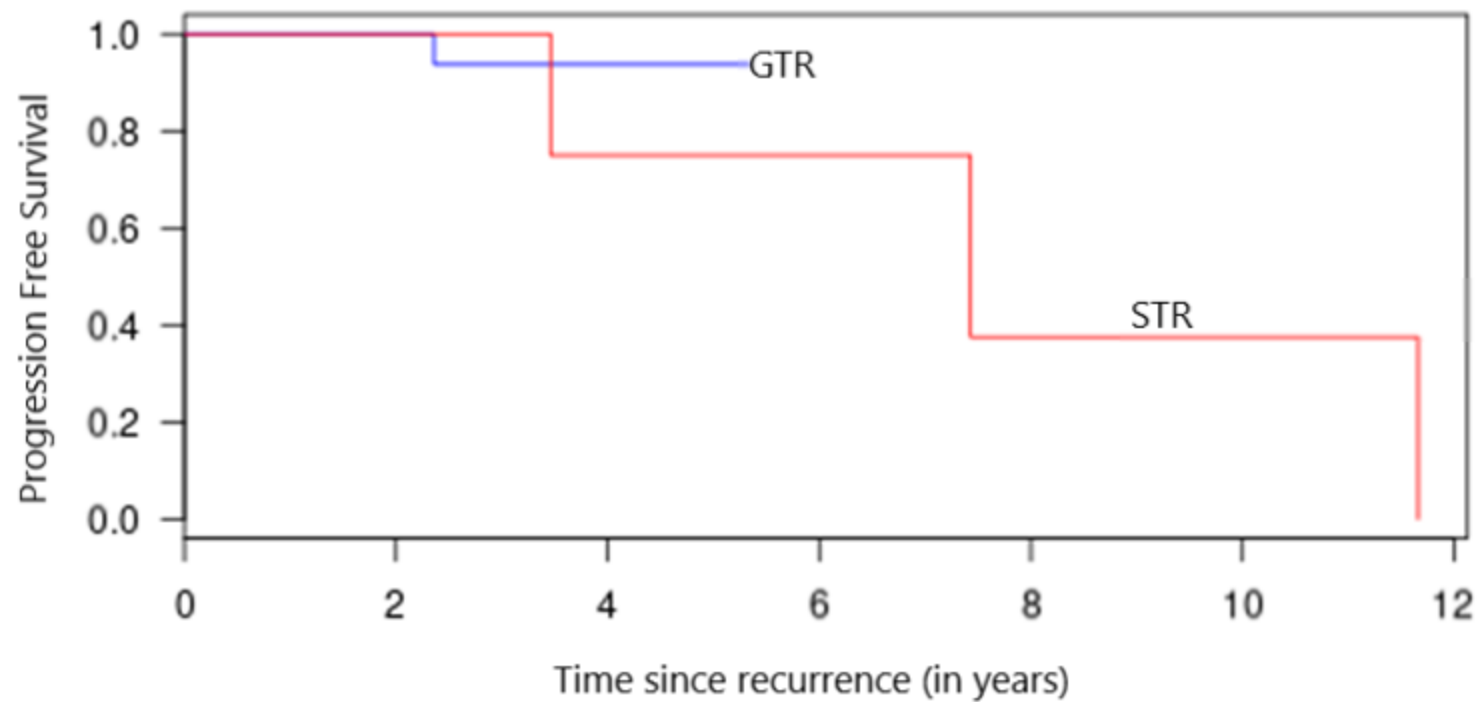


Table 1: Patient characteristics

	Total population, Patients: n = 48 Meningiomas: n = 51
Age: mean \pm SD, years	60.24 \pm 14.9
Sex: Female, n (%)	39 (81.3)
Pre-operative McCormick scale: n (%)	
I	5 (10.4)
II	14 (29.2)
III	16 (33.3)
IV	12 (25.0)
V	1 (2.1)
Pre-operative ASA scale: median [Q1 – Q3]	2 [1 – 3]
Tumor location: n (%)	
Cervical canal	11 (21.6)
Thoracic canal	39 (75.0)
Lumbar canal	1 (1.9)
Tumor size according to the Bayoumi et al. scale: n (%)	
Grade I (< 25% spinal canal)	3 (5.9)
Grade II (25 – 50% spinal canal)	5 (9.7)
Grade III (50 – 75% spinal canal)	13 (25.5)
Grade IV (> 75% spinal canal)	30 (58.9)
Quality of resection: n (%)	
GTR	47 (92.1)
STR	4 (7.9)
Histology: n (%)	
WHO grade I	51 (100)
Post-operative McCormick scale: n (%)	
I	34 (70.8)
II	12 (25.0)
IV	1 (2.1)
V	1 (2.1)
Recurrence: n (%)	4 (8.3)
Follow-up: mean \pm SD, months	46.6 \pm 14.2

ASA: American Society of Anesthesiologists, GTR: gross total resection, SD: standard deviation, STR: sub-total resection, WHO: World health organization.

Table 2: Comparison of population, surgical outcomes, and perioperative morbidities between open and minimally invasive approaches.

	MIS n = 18	Open surgery n = 30	p-value
Follow-up: mean \pm SD, years	3.2 \pm 0.9	4.0 \pm 1.5	0.1
Age: mean \pm SD, years	66.5 \pm 14.1	56.4 \pm 14.3	0.02
ASA scale: median [Q1 – Q3]	2 [1 - 3]	2 [1 - 2]	0.06
Localization, n (%)			
Cervical canal	1 (5.55)	10 (31.2)	0.1
Thoracic canal	16 (88.9)	22 (68.8)	
Lumbar canal	1 (5.55)		
Volume of meningioma (Bayoumi scale), n (%)			
Grade I	0	1 (3.3)	0.3
Grade II	1 (5.5)	4 (13.3)	
Grade III	3 (16.7)	9 (30.0)	
Grade IV	14 (77.8)	16 (53.4)	
Quality of resection, n (%)			
GTR	17 (94.6)	27 (90.0)	> 0.5
STR	1 (5.5)	3 (10.0)	
Blood loss: mean \pm SD, mL	252.7 \pm 215.2	456.7 \pm 396.25	0.02
Time of surgery: mean \pm SD, hours	2.07 \pm 0.66	2.56 \pm 1.08	0.04
Hospitalization time: mean \pm SD, days	6.6 \pm 4.0	8.1 \pm 5.6	0.3
Morbidities			
CSF Leakage, n (%)	1 (5.5)	0	> 0.5
Meningitidis, n (%)	0	1 (3.3)	> 0.5
Neurological worsening, n (%)	2 (11.1)	4 (13.3)	> 0.5
Postoperative compressive hematoma, n (%)	0	0	> 0.5

ASA: American Society of Anesthesiologists, CI: confidence interval, GTR: gross total resection, MIS: minimally invasive surgery, SD: standard deviation, STR: sub-total resection.