



HAL
open science

Management of type ia endoleak after evar by explantation or custom made fenestrated endovascular aortic aneurysm repair

Benoit Doumenc, Thomas Mesnard, Benjamin Oliver Patterson, Richard Azzaoui, Agathe de Preville, Stephan Haulon, Jonathan Sobocinski

► To cite this version:

Benoit Doumenc, Thomas Mesnard, Benjamin Oliver Patterson, Richard Azzaoui, Agathe de Preville, et al.. Management of type ia endoleak after evar by explantation or custom made fenestrated endovascular aortic aneurysm repair. *European Journal of Vascular and Endovascular Surgery*, 2021, *European Journal of Vascular and Endovascular Surgery*, 61, pp.571-578. 10.1016/j.ejvs.2020.10.033 . hal-04465228

HAL Id: hal-04465228

<https://hal.univ-lille.fr/hal-04465228v1>

Submitted on 22 Jul 2024

HAL is a multi-disciplinary open access archive for the deposit and dissemination of scientific research documents, whether they are published or not. The documents may come from teaching and research institutions in France or abroad, or from public or private research centers.

L'archive ouverte pluridisciplinaire **HAL**, est destinée au dépôt et à la diffusion de documents scientifiques de niveau recherche, publiés ou non, émanant des établissements d'enseignement et de recherche français ou étrangers, des laboratoires publics ou privés.



Distributed under a Creative Commons Attribution - NonCommercial 4.0 International License

Management of Type IA Endoleak After EVAR with Explantation or Custom-Made Fenestrated Endovascular Aortic Aneurysm Repair

Benoit Doumenc^a, Thomas Mesnard^{a,b}, Benjamin O Patterson^c, Richard Azzaoui^a, Agathe De Préville^a, Stephan Haulon^d, Jonathan Sobocinski^{a,b,*}

^a Service de chirurgie vasculaire, Centre de l'Aorte, CHU Lille, France

^b University of Lille, U1008 - Controlled Drug Delivery Systems and Biomaterials, Lille, France

^c Department of Vascular Surgery, University Hospital Southampton, UK

^d Service de chirurgie vasculaire, Centre de l'Aorte, Hôpital Marie-Lannelongue, Le Plessis Robinson, France

*Corresponding author. Lille University Hospital, Vascular Surgery, Institut Coeur Poumon, Bd Prof J Leclercq, Lille CEDEX, 59037, France.

E-mail address: jonathan.sobocinski@univ-lille.fr

Short title: Management of Type IA endoleak after EVAR

WHAT THIS PAPER ADDS

Proximal type 1 endoleak after endovascular abdominal aortic aneurysmal repair (EVAR) remains challenging to solve with no existing consensus, while their incidence is increasing as EVAR is now the most common strategy to treat infrarenal aortic aneurysms. This is a report of single-centre outcomes of two surgical techniques: endograft explantation and fenestrated cuff extension achieved to correct the proximal endoleak. Management of this complex complication is also discussed according to study centre experience and literature review.

Objective: Proximal type 1 endoleak after endovascular abdominal aortic aneurysmal repair (EVAR) remains challenging to solve with no existing consensus. This work aims to compare two different surgical strategies to remedy type IA endoleak: endograft explantation (EXP) and aortic reconstruction or relining with custom-made fenestrated EVAR (F-EVAR).

Method: A retrospective single centre analysis between 2009 and 2018 was conducted including patients treated for type IA endoleak after EVAR with either EXP or F-EVAR. The choice of surgical technique was based on morphological factors (F-EVAR eligibility),

growth rate of the sac, emergent character and/or symptoms presented by the patient. Technical success, morbidity, secondary interventions, 30 day mortality, and long term survival according to Kaplan–Meier were determined for each group and compared.

Results: Fifty-nine patients (91% male, mean age 79 years) underwent either EXP ($n = 26$) or F-EVAR ($n = 33$) during the study period. The two groups were equivalent in terms of comorbidity and age at time of procedure. The median time from initial EVAR was 60.4 months (34 – 85 months), with no difference between groups. The maximal aneurysmal diameter was superior in the EXP group compared to the F-EVAR group, 86 mm (65 – 100) and 70 mm (60 – 80), respectively ($p = .008$). Thirty day secondary intervention (EXP: 11.5% vs. F-EVAR: 9.1%) and mortality (EXP: 3.8% vs. F-EVAR: 3.3%) rates did not differ between groups, while major adverse events at 30 days, as defined following the current SVS guidelines, were lower in the F-EVAR group (2.4% vs. 13.6%; $p = .016$). One year survival rates were similar between the groups (EXP: 84.0% vs. F-EVAR: 86.6%).

Conclusion: Open explantation and endovascular management with a fenestrated device for type IA endoleak after EVAR can be achieved in high-volume centres with satisfactory results. F-EVAR is associated with decreased early morbidity. Open explantation is a relevant option because of the limited applicability of F-EVAR with acceptable outcomes.

Keywords: Endoleak, Fenestrated endograft: F-EVAR, Open conversion

INTRODUCTION

EVAR is the most common treatment modality for infrarenal abdominal aortic aneurysms, with a lower early mortality rate compared to open surgery. The initial benefit of this minimally invasive technique is not sustained when considering long term follow up of randomised control trials.^{1,2}

Long term outcomes are closely related to initial anatomical suitability for EVAR,^{3,4} and proximal endoleaks (type IA) represent the main cause of late rupture after EVAR. The risk of proximal endoleaks is higher when the index infrarenal bifurcated endograft has been implanted without following the instructions for use (IFU) from the manufacturers.^{3,5} Different approaches might be discussed when proximal type IA endoleaks are identified, including additional stenting,⁶ infrarenal cuff extension, or type IA endoleak embolisation. Nevertheless, such alternatives require meticulous selection and conditions as mid/long term success remains uncertain.^{7,8} In other cases two broad approaches are considered to definitively correct type 1A endoleaks: i) the relining of the previous infrarenal endograft

with the implantation of a custom-made fenestrated endograft (F-EVAR) or ii) performing a surgical explantation of the endograft (EXP).

There is no universally accepted recommendation for management of these patients, and the strategy selection is based on a meticulous anatomical study of the aorta to evaluate the feasibility of the endovascular repair, and on pre-operative physiological assessment to determine the eligibility for an open surgical option. This retrospective study aims at evaluating and comparing outcomes of both strategies in a high-volume aortic centre.

MATERIALS AND METHODS

Fifty-nine consecutive patients referred to a single tertiary centre who underwent surgical correction of type IA endoleak by either F-EVAR or EXP between November 2009 and December 2018 were included in the present study (Fig. S1). All of these patients presented significant aneurysmal expansion ≥ 5 mm compared to the post-operative diameter reported on the computer tomography angiography (CTA) after the index EVAR, whatever the time frames. Patients were all initially treated for an abdominal aortic aneurysm (AAA) with infrarenal bifurcated aortic endografts from different manufacturers in different centres throughout the region. The diagnosis of proximal type IA endoleak was made with contrast-enhanced CTA pre-operatively. Maximal pre-operative outer wall aneurysm diameter was measured with curvilinear reconstruction (CPR) using dedicated software (Terarecon). Other endoleaks (type Ib and type II) were also recorded from the pre-operative CTA. In case of endovascular management of type IA endoleak, all type IB endoleaks were treated simultaneously. However, type II endoleaks were not treated at the same time.

Population characteristics, initial clinical presentation, peri-operative management, and follow up including rates of complications, secondary interventions, and mortality/survival were described. Major adverse events were defined as moderate or severe complications according to the SVS reporting standards.⁹ Pre-operative cerebrospinal fluid (CSF) drainage was deemed necessary in case of previous thoracic endograft or open replacement of the descending thoracic aorta, and/or in case of proximal aortic coverage above the sixth thoracic vertebra.

The choice of type of procedure (F-EVAR or EXP) was based on the maximal aortic aneurysm diameter, initial presentation (symptomatic or not), and F-EVAR feasibility. The final decision was made by the surgeon after evaluating the pros and cons of both techniques for each specific patient.

Technical success regarding F-EVAR patients was defined according to the reporting standards,⁹ including 24-hour survival, successful endograft introduction and deployment

without surgical conversion, absence of type I or type III endoleaks on the final angiogram, and endograft/bridging stent patency. Cone beam computed tomography (CBCT) was systematically performed at the end of the procedure in the F-EVAR group. A contrast-enhanced ultrasound (CEUS) was then completed before discharge in this group. A post-operative CTA was usually done at six months and then yearly in the F-EVAR group. Patients in the EXP group were follow up with doppler ultrasound at six months, then yearly.

This study was approved by the Institutional Review Board of Lille University Hospital.

Statistical analysis

Data were analysed using SPSS Statistics 22 (IBM, Armonk, NY, USA). Quantitative values are presented as median (interquartile range [IQR]) unless otherwise stated. Mann–Whitney *U* test, Fisher’s exact test, and Khi2 test were used where appropriate. A *p* value < .05 was assumed to be significant. Survival curves were calculated according to the Kaplan–Meier method.

RESULTS

Study sample

From November 2009 to December 2018, 59 consecutive patients required a secondary intervention for EVAR rescue related to a type IA endoleak: 26 patients (44%) were managed with surgical open explantation whereas 33 patients (56%) underwent F-EVAR (Fig. 1).

Demographics

The majority of patients were male ($n = 54$ [91%]), with a mean age at the time of the procedure of 79 years (70 – 82). There was no statistical difference between both groups regarding demographic characteristics (Table 1). The maximal aneurysmal diameter (median) was superior in the EXP group compared to the F-EVAR group, 86 mm (65 – 100) and 70 mm (60 – 80), respectively ($p = .008$).

Previous endograft data

All patients were initially treated for asymptomatic aneurysms. Thirty-four patients (58%) were initially treated at the study institution, with the remaining patients treated at different centres. The distribution of the brand of the index infrarenal endograft implanted was similar in the two groups (Table 2); three were aorto-uni-iliac grafts (two in the F-EVAR group and one in the EXP group) and 56 were bifurcated grafts.

Secondary intervention after EVAR and before F-EVAR or EXP

Twenty-two additional interventions were performed after the index EVAR in 17 patients, with similar rates between groups (nine [27%] in the F-EVAR group and eight [31%] in the

EXP group, Table 3). The majority of these interventions consisted of type II endoleak transarterial embolisations ($n = 5$) or implantation of a distal leg extension to treat type IB endoleaks ($n = 8$).

The median time interval from index EVAR to F-EVAR or EXP was 60.4 months (34 – 85 months); 62.6 months (39.4 – 86.2) for F-EVAR patients and 52.1 months (28.15 – 79.19) for EXP patients, with no difference between groups ($p = .25$).

Pre-procedural data

Type Ib endoleak was associated with type Ia endoleak in 20% of cases and type II endoleak was present in 17%.

Procedural details: EXP group

All 26 patients were treated through a midline laparotomy using a transperitoneal approach (Table 4). Supra-coeliac aortic cross-clamping was necessary in 14 cases (54%). Fifty per cent ($n = 13$) of patients required an aorto-bi-iliac bypass. All grafts used were made of polyester (PET). In a majority of patients ($n = 16$, 62%), a complete explantation of the endograft was performed; in the other cases, the proximal uncovered stent or iliac limbs were left in place in two (8%) and eight (31%) cases, respectively. No patient required visceral or renal artery revascularisation. No CSF drainage was performed.

Procedural details: F-EVAR group

Most cases ($n = 22$, 67%) required an endograft with four fenestrations to achieve an appropriate proximal seal; otherwise, one case (3%) required five fenestrations; six (18%) cases required three, and four cases (12%) required two. The median length of aortic coverage by the endograft above the coeliac trunk was 41 mm (32 – 57). Complete relining of the endograft was done in 10 patients, while an additional iliac branch was included in three cases.

Surgical cutdowns were performed for femoral access in most patients ($n = 21$, 64%), with percutaneous access for the other patients ($n = 12$, 26%). In one case, an ilio-femoral conduit was performed to allow device insertion. Seven patients (21%) had one or two accessory renal arteries excluded during the F-EVAR procedure because the diameter was < 4 mm or because their origin was too close to the main renal trunk or the superior mesenteric artery. Pre-operative CSF drainage was performed in three cases (9%).

All procedures were performed under general anaesthesia.

The mean radiation dose was 82.1 Gy.cm² (50.5 – 112.6) and mean iodine contrast volume injected was 85 mL (64.3 – 103.8).

Surgical time (skin to skin) was similar in the EXP and F-EVAR groups (210.9 ± 76.1 minutes vs. 193.1 ± 60.2 minutes, respectively). Patients in the EXP group required significantly more blood transfusions than patients in the F-EVAR group (2.3 ± 2 vs. < 1 blood transfusion, respectively; $p < .001$).

Technical success was similar between EXP and F-EVAR at 94% and 96%, respectively ($p > .05$). Two technical failures occurred in the F-EVAR group related to one intra-operative death caused by aneurysm rupture and the other caused by a failure of the coeliac trunk catheterisation. In the EXP group, the one technical failure seen was a post-operative acute lower limb ischaemia related to acute limb thrombosis successfully treated with prompt embolectomy (Table 5).

Outcomes

The length of intensive care unit (ICU) stay was significantly lower in the F-EVAR group (F-EVAR = 1 day (1 – 2) vs. EXP = 3.5 days (2 – 6); $p < .001$), as was the median time to discharge (F-EVAR = 9 days (8 – 9) and EXP = 14 days (11 – 20); $p < .001$).

Only two patients (3.4%) in the F-EVAR group presented 30 day major adverse events, which was significantly lower than in the EXP group ($n = 8$, 13.6%; $p < .001$) (Table 5).

In total, three patients developed acute renal failure (one in the F-EVAR group and two in the EXP group), but none of them required temporary or permanent dialysis (Table 5).

Among the cardiac complications reported ($n = 4$), two patients (one in each group) required pacemaker implantation for high-degree atrioventricular block, while the two remaining cardiac complications occurred in the EXP group: one acute coronary syndrome (conservative treatment) and one successful cardiac resuscitation.

In the EXP group, a patient experienced colonic ischaemia with left colectomy. There was no post-operative spinal cord ischaemia (SCI) in any group.

Three patients experienced vascular complications in the F-EVAR group: one acute renal stent thrombosis, one lower limb ischaemia related to iliac limb thrombosis, and one femoral pseudo-aneurysm (Table 5).

The median time of follow up was similar in each group (F-EVAR = 13.0 months [3.7 – 32.1] vs. EXP = 12.9 months [6.5 – 26.2]).

At six months, in the F-EVAR group, the median maximum aneurysm diameter was stable compared with the pre-operative measurements (70 mm [60 – 80] vs. 67.00 [58.8 – 83.5]; $p = .92$).

Late secondary interventions

During follow up, five (four in the F-EVAR group) patients required late secondary interventions (Table 6). In the F-EVAR group, a patient required open surgical (partial) endograft explantation after continuous aneurysm expansion secondary to a type II endoleak. One late secondary intervention was performed in the EXP group for a chronic groin lymphocele.

Mortality

The 30 day mortality rate was similar in both groups (F-EVAR 3.3% vs. EXP 3.8%).

One early death occurred in each group: in the F-EVAR group following an intra-operative aneurysm rupture; in the EXP group following a massive post-operative myocardial infarction.

All-cause survival rates were similar in each group at six months (EXP 84% vs. F-EVAR 90%; $p = .27$) and one year (EXP 84% vs. F-EVAR 87%; $p = .83$).

DISCUSSION

Over the last decade, EVAR has become the most common method of treating infrarenal aortic aneurysms.¹⁰ But, despite the undoubted successes that have been observed, the occurrence of late graft failure is well documented.¹¹ The main cause of aortic rupture after EVAR has been attributed to untreated or undetected type 1A endoleaks.^{9,12,13} The need for planning grafts according to the anatomical criteria outlined in graft manufacturers' instructions for use (IFU) has therefore become more apparent as the practice of EVAR has matured, but even patients treated within these are not immune from late device failure.³ Few retrospective series have reported results of the management of type IA endoleak after EVAR with F-EVAR or surgical explantation,¹⁴⁻¹⁹ and only one study comparative results of these two techniques.²⁰

The present study compared the outcome of custom-made fenestrated endovascular repair and open endograft surgical explantation to correct type IA endoleaks during a nineyear period in a high-volume aortic centre. Comparatively low 30 day mortality rates for surgery are reported in an elderly population with a median age of 79 years. The median time interval from primary EVAR to secondary surgery was around five years, which is similar to intervals reported in previous studies.^{14-16,20}

In the present study cohort, the 30 day mortality was similar in both groups of patients, which were noted to have comparable pre-operative comorbidities (F-EVAR 3.3% vs. EXP 3.8%), comparing favourably to recent studies such as the EUROSTAR registry,¹¹ or that of Dias *et al.*,²⁰ who reported a 30 day mortality of 4.7% after F-EVAR vs. 10.5% after EXP ($p =$

.019). It should be emphasised that these patients were treated electively and those with infected grafts and frank rupture were excluded.²¹

The choice of surgical technique employed was guided by morphological factors that influenced F-EVAR eligibility, the growth rate of the sac, and symptomatic status. Patients in the present EXP group had, on average, a greater maximal aneurysm diameter than patients in the F-EVAR group, and this potentially reflected the fact that perception of rupture risk was higher. The manufacturing time for a custom-made fenestrated device is now three to four weeks, but this may be not acceptable for symptomatic or otherwise high-risk patients. In the absence of a technically appropriate endovascular solution, open surgical explantation was also the only treatment option remaining in individuals assessed to be fit enough for this. Surgical explantation is a more aggressive approach but may be more durable. In the present study cohort, the aneurysm sac remained stable after F-EVAR, but long term data are unknown, and in one patient surgical explantation was subsequently employed. Patient selection criteria for either technique are presented in Fig. 2.

The feasibility of the endovascular treatment is dependent on the configuration of the aortic branches and the ability to gain a seal within, or distal to, the visceral aorta as it is in primary surgery. Proximal sealing is generally achieved by extension by one full stent (~ 25 mm) above the top of the proximal bare stent of the previous EVAR. This added coverage of watershed vascular supply to the spinal cord by the endograft may theoretically expose the patient to a higher risk of paraplegia. In the present cohort, the median aortic coverage above the coeliac trunk was 41 mm (32 – 57), but SCI was not seen to be an issue. Most previously published series reported the same findings regarding the SCI rate following F-EVAR.^{14,15,17,19} In one reported case of paraplegia following F-EVAR for EVAR-rescue in a series of 12 patients, the patient required concomitant TEVAR for a penetrating aortic ulcer,¹⁶ and Dias *et al.* reported a SCI rate of 2/85.²⁰ These studies did not report the median length of aortic coverage.

A fenestrated cuff can potentially be employed as the preferred option if the previous EVAR has a long main body (a minimum of two stents overlap required), has not migrated, and there is no distal type I or type III (or even IV) endoleak. More recent experience has suggested that many patients will require complete relining of the previous endograft to ensure durability, however. To achieve this, the design of the distal bifurcated body must take into account the length between the lowest renal artery and the top of the highest limb extension and/or the level of the flow diverter of the previous EVAR; if it is > 35 mm, a custom-made bifurcated inverted limb will be required. The shortest available main body

inverted limb so far is 28 mm; when this working space is not available, the only option is a branched endograft but this would require extensive proximal aortic coverage.

When explantation is planned to correct a proximal type I endoleak, removing the entire endograft including the proximal bare stent is not always mandatory as it may cause injury to the aortic wall, and to the renal or visceral arteries. In the present authors' experience, when the primary endograft includes a proximal supra-renal bare stent, supra-coeliac aortic cross-clamping is required to secure haemostasis. No data regarding the time of cross-clamping were available in the patient files unfortunately, but previous work has confirmed that higher mortality and morbidity rates are observed in late aortic conversion necessitating prolonged supra-coeliac cross-clamp time.²² Similarly, when the juxta-renal aortic segment is heavily diseased with circumferential thrombus or calcification, it is usually prudent not to attempt to disengage the proximal covered segment from the aorta. In this setting, the proximal suture line incorporates the endograft, the aortic wall and the graft. Partial endograft explantation does not seem to be associated with higher complication rates resulting from the remaining endograft component.²³ This has to be adapted to the extent of the aortic disease.

Less invasive therapeutic alternatives have been described to perform EVAR-rescue related to a loss of proximal sealing, which avoid extensive surgery, but the results of these techniques have been variable. Usually some degree of infra-renal neck must be preserved in such cases. The use of a balloon-expandable uncovered stent within the proximal sealing stent of the initial endograft does not show long term efficacy.^{6,24} In the present study cohort, three patients underwent proximal aortic stenting with Palmaz stent (Cordis, Fremont, CA, USA) before F-EVAR or explantation. This approach was preferred in frail patients when the infrarenal neck was longer than 10 mm or slightly conical. Endoanchors or parallel stent techniques were not employed because of concern regarding suboptimal long term outcomes.^{25,26} The embolisation of type IA endoleak has also been described as an alternative treatment in patients not eligible for other treatments.^{7,8,27,28} Although encouraging initial results have been described, long term outcomes are not widely published.

Limitations of this study include that it is retrospective and from a single centre with a relatively short duration of follow up. Although all consecutive cases treated on a semi-elective or urgent basis over the study period were included, infected or ruptured cases were excluded. A degree of selection bias is unavoidable in terms of patient selection and the modality employed to treat them in such a study, and this may reduce the ability to generalise the results to other settings. Because of the duration of the study, which was 10 years, it is

possible that experience with these techniques has improved over time, but this was not possible to delineate given the relatively small numbers of patients. Some data were missing, including cross-clamp time, which could have been collected in a prospective registry and may have provided some added insight. A longer duration of follow up and the addition of further post-operative events would add significantly to appreciation of the mid and long term outcomes. Prospective, multicentre registry data would seem the best way to gain understanding of this problem, but retrospective pooled data would also be valuable.

Conclusion

Open surgical conversion and endovascular management with a fenestrated device of type IA endoleak after EVAR can be achieved in high-volume centres with satisfactory results. F-EVAR is associated with decreased early morbidity. Open explantation would still be considered as a relevant option because of the limited applicability of F-EVAR in this setting with acceptable outcomes.

CONFLICT OF INTEREST

S Haulon and J Sobocinski are consultants for Cook Medical.

FUNDING

None.

REFERENCES

1. EVAR trial participants. Endovascular aneurysm repair versus open repair in patients with abdominal aortic aneurysm (EVAR trial 1): randomised controlled trial. *Lancet Lond Engl.* 2005;365:2179-86.
2. Brown LC, Powell JT, Thompson SG, Epstein DM, Sculpher MJ, Greenhalgh RM. The UK EndoVascular Aneurysm Repair (EVAR) Trials: randomised trials of EVAR versus standard therapy. In: NIHR Health Technology Assessment programme: Executive Summaries. NIHR Journals Library; 2012.
3. Schanzer A, Greenberg RK, Hevelone N, Robinson WP, Eslami MH, Goldberg RJ, et al. Predictors of abdominal aortic aneurysm sac enlargement after endovascular repair. *Circulation.* 2011;123:2848–2855.
4. De Martino RR, Brooke BS, Robinson W, Schanzer A, Indes JE, Wallaert JB, et al. Designation as « unfit for open repair » is associated with poor outcomes after endovascular aortic aneurysm repair. *Circ Cardiovasc Qual Outcomes.* 2013;6:575-81.
5. Dillavou ED, Muluk SC, Rhee RY, Tzeng E, Woody JD, Gupta N, et al. Does hostile neck anatomy preclude successful endovascular aortic aneurysm repair? *J Vasc Surg.* 2003;38:657–663.

6. Arthurs ZM, Lyden SP, Rajani RR, Eagleton MJ, Clair DG. Long-Term Outcomes of Palmaz Stent Placement for Intraoperative Type Ia Endoleak During Endovascular Aneurysm Repair. *Ann Vasc Surg.* 2011;25:120-6.
7. Chun J-Y, Morgan R. Transcatheter embolisation of type 1 endoleaks after endovascular aortic aneurysm repair with Onyx: when no other treatment option is feasible. *Eur J Vasc Endovasc Surg Off J Eur Soc Vasc Surg.* 2013;45:141-4.
8. Henrikson O, Roos H, Falkenberg M. Ethylene vinyl alcohol copolymer (Onyx) to seal type 1 endoleak. A new technique. *Vascular.* 2011;19:77-81.
9. Chaikof EL, Dalman RL, Eskandari MK, Jackson BM, Lee WA, Mansour MA, et al. The Society for Vascular Surgery practice guidelines on the care of patients with an abdominal aortic aneurysm. *J Vasc Surg.* 2018;67:2–77.
10. Dua A, Kuy S, Lee CJ, Upchurch GR, Desai SS. Epidemiology of aortic aneurysm repair in the United States from 2000 to 2010. *J Vasc Surg.* 2014;59:1512-7.
11. Harris PL, Vallabhaneni SR, Desgranges P, Becquemin J-P, van Marrewijk C, Laheij RJ. Incidence and risk factors of late rupture, conversion, and death after endovascular repair of infrarenal aortic aneurysms: the EUROSTAR experience. *J Vasc Surg.* 2000;32:739–749.
12. Antoniou GA, Georgiadis GS, Antoniou SA, Neequaye S, Brennan JA, Torella F, et al. Late rupture of abdominal aortic aneurysm after previous endovascular repair: a systematic review and meta-analysis. *J Endovasc Ther.* 2015;22:734–744.
13. Bernhard VM, Mitchell RS, Matsumura JS, Brewster DC, Decker M, Lamparello P, et al. Ruptured abdominal aortic aneurysm after endovascular repair. *J Vasc Surg.* 2002;35:1155–1162.
14. Katsargyris A, Yazar O, Oikonomou K, Bekkema F, Tielliu I, Verhoeven ELG. Fenestrated stent-grafts for salvage of prior endovascular abdominal aortic aneurysm repair. *Eur J Vasc Endovasc Surg.* 2013;46:49–56.
15. Martin Z, Greenberg RK, Mastracci TM, Eagleton MJ, O’Callaghan A, Bena J. Late rescue of proximal endograft failure using fenestrated and branched devices. *J Vasc Surg.* 2014;59:1479–1487.
16. Falkensammer J, Taher F, Uhlmann M, Hirsch K, Strassegger J, Assadian A. Rescue of failed endovascular aortic aneurysm repair using the fenestrated Anaconda device. *J Vasc Surg.* 2017;66:1334–1339.
17. Verhoeven ELG, Muhs BE, Zeebregts C, Tielliu IFJ, Prins TR, Bos W, et al. Fenestrated and branched stent-grafting after previous surgery provides a good alternative to open redo surgery. *Eur J Vasc Endovasc Surg.* 2007;33:84–90.

18. Duvnjak S. Endovascular management of type I endoleak with fenestrated aortic “cuff” and afterwards treatment of endoleak type III. *Int J Angiol.* 2016;25:e111–e114.
19. Wang SK, Drucker NA, Sawchuk AP, Lemmon GW, Dalsing MC, Motaganahalli RL, et al. Use of the Zenith Fenestrated platform to rescue failing endovascular and open aortic reconstructions is safe and technically feasible. *J Vasc Surg.* 2018;68:1017–1022.
20. Dias AP, Farivar BS, Steenberge SP, Brier C, Kuramochi Y, Lyden SP, et al. Management of failed endovascular aortic aneurysm repair with explantation or fenestrated-branched endovascular aortic aneurysm repair. *J Vasc Surg.* 2018;68:1676–1687.
21. Argyriou C, Georgiadis GS, Lazarides MK, Georgakarakos E, Antoniou GA. Endograft infection after endovascular abdominal aortic aneurysm repair: a systematic review and meta-analysis. *J Endovasc Ther.* 2017;24:688–697.
22. Brinster CJ, Fairman RM, Woo EY, Wang GJ, Carpenter JP, Jackson BM. Late open conversion and explantation of abdominal aortic stent grafts. *J Vasc Surg.* 2011;54:42–46.
23. Steenberge SP, Lyden SP, Turney EJ, Kelso RL, Srivastava SD, Eagleton MJ, et al. Outcomes after Partial Endograft Explantation. *Ann Vasc Surg.* 2016;31:1-7.
24. Abdulrasak M, Resch T, Sonesson B, Holst J, Kristmundsson T, Dias NV. The Long-term Durability of Intra-operatively Placed Palmaz Stents for the Treatment of Type Ia Endoleaks After EVAR of Abdominal Aortic Aneurysm. *Eur J Vasc Endovasc Surg Off J Eur Soc Vasc Surg.* 2017;53:69-76.
25. Jordan Jr WD, Mehta M, Varnagy D, Moore Jr WM, Arko FR, Joye J, et al. Results of the ANCHOR prospective, multicenter registry of EndoAnchors for type Ia endoleaks and endograft migration in patients with challenging anatomy. *J Vasc Surg.* 2014;60(4):885–892.
26. Avci M, Vos JA, Kolvenbach RR, Verhoeven EL, Perdikides T, Resch TA, et al. The use of endoanchors in repair EVAR cases to improve proximal endograft fixation. *J Cardiovasc Surg (Torino).* 2012;53:419–426.
27. Eberhardt KM, Sadeghi-Azandaryani M, Worlicek S, Koeppel T, Reiser MF, Treitl M. Treatment of type I endoleaks using transcatheter embolization with onyx. *J Endovasc Ther Off J Int Soc Endovasc Spec.* 2014;21:162-71.
28. Ierardi AM, Franchin M, Fontana F, Piffaretti G, Crippa M, Angileri SA, et al. The role of ethylene-vinyl alcohol copolymer in association with other embolic agents for the percutaneous and endovascular treatment of type Ia endoleak. *Radiol Med (Torino).* 2018;123:638-42.

Table 1. Baseline characteristics of 59 patients treated for a type IA endoleak after endovascular aneurysm repair (EVAR) with either fenestrated endograft (F-EVAR) or surgical explantation (EXP).

Characteristics	F-EVAR (<i>n</i> =33; 55.9%)	EXP (<i>n</i> =26; 44.1%)	<i>p</i> *
Age – y	82.6 (76.7–85.7)	78.7 (72.0–84.2)	.080
Male	31 (93.9)	23 (88.5)	.64
Coronary disease	18 (54.5)	14 (53.8)	.96
LVEF – %	57 (54–64)	55 (54–65)	.95
High blood pressure	19 (57.6)	16 (61.5)	.76
Respiratory insufficiency	7 (21.2)	11 (42.3)	.080
Tobacco use	12 (36.4)	12 (46.2)	.45
Diabetes mellitus	6 (18.2)	7 (26.9)	.42
Chronic renal insufficiency (GFR <60 mL/min/1.73m ²)	9 (27.3)	7 (27)	.52
Dyslipidaemia	22 (66.7)	15 (57.7)	.48
Previous abdominal surgery	2 (6.7)	6 (23.1)	.12
BMI >30 kg/m ²	10 (30.3)	11 (42.3)	.93
Cardiac arrhythmia	13 (39.4)	8 (30.8)	.49

Data are presented as *n* (%) or median (interquartile range). LVEF = left ventricular ejection fraction; GFR = glomerular filtration rate; BMI = body mass index.

* *p* value of difference between groups.

Table 2. Distribution of manufacturers of the index infrarenal aortic endograft (EVAR) originally implanted in the 59 patients treated later for a type IA endoleak with either fenestrated endograft (F-EVAR) or surgical explantation (EXP).

Brand	F-EVAR (<i>n</i> =33)	EXP (<i>n</i> =26)	Total (<i>n</i> =59)
CookMedical	20 (61)	9 (35)	29 (49)
Gore	0	1 (4)	1 (2)
Medtronic	5 (15)	4 (15)	9 (15)
Endologix	1 (3)	2 (8)	3 (5)
Vascutek	2 (6)	6 (23)	8 (14)
Unknown	5 (15)	4 (15)	9 (15)

Data are presented as *n* (%).

Table 3. Additional procedures between the index endovascular aneurysm repair (EVAR) time, and time of the proximal type I endoleak correction with either fenestrated endograft (F-EVAR) or surgical explantation (EXP).

Indication	<i>n</i>	Type of procedure	<i>n</i>	Adjunctive procedure	<i>n</i>
Type Ia endoleak	5	Stenting or tubular cuff within the proximal sealing zone	5	Type II endoleak embolisation	1

				Distal limb extension for type Ib endoleak	1
				Crossover femoro-femoral bypass for limb occlusion	2
Type Ib endoleak	6	Bilateral distal limb extension	2	Type II endoleak transarterial embolisation	2
		Iliac branched device	1		
		Distal limb extension	3		
Type II endoleak	4	Transarterial embolisation	4		
Type III endoleak	1	Limb extension	1		
Iliac limb thrombosis	1	Crossover femoro-femoral bypass	1		

Table 4. Details of the procedures including level of aortic cross-clamping and type of vascular reconstruction in patients treated with surgical explantation (EXP) for a type IA endoleak after endovascular aneurysm repair (EVAR).

	Procedures (n=26)
<i>Level of aortic cross-clamping</i>	
Infrarenal	6 (23)
Supra coeliac	14 (54)
Inter-renal	1 (4)
Unknown	5 (19)
<i>Vascular reconstruction</i>	
Aorto-bi-femoral bypass	5 (19)
Aorto-bi-iliac bypass	13 (50)
Aorto-aortic bypass	8 (31)

Data are presented as n (%).

Table 5. Early post-operative major adverse events and 30 day secondary interventions of patients treated for a type IA endoleak after endovascular aneurysm repair (EVAR) with fenestrated endograft (F-EVAR) or surgical explantation (EXP).

	F-EVAR (n = 33)	EXP (n = 26)	Total (n = 59)
<i>Major adverse events</i>			
Colonic ischaemia	0	1	1
Renal failure	1	2	3
Cardiac complications	1	3	4
Spinal cord ischaemia	0	0	0
<i>30 day secondary interventions</i>			
Left colectomy	0	1	1
Retroperitoneal haematoma drainage	0	1	1
Acute lower limb ischaemia	1	1	2
Renal stent desocclusion	1	0	1
Femoral pseudo-aneurysm	1	0	1

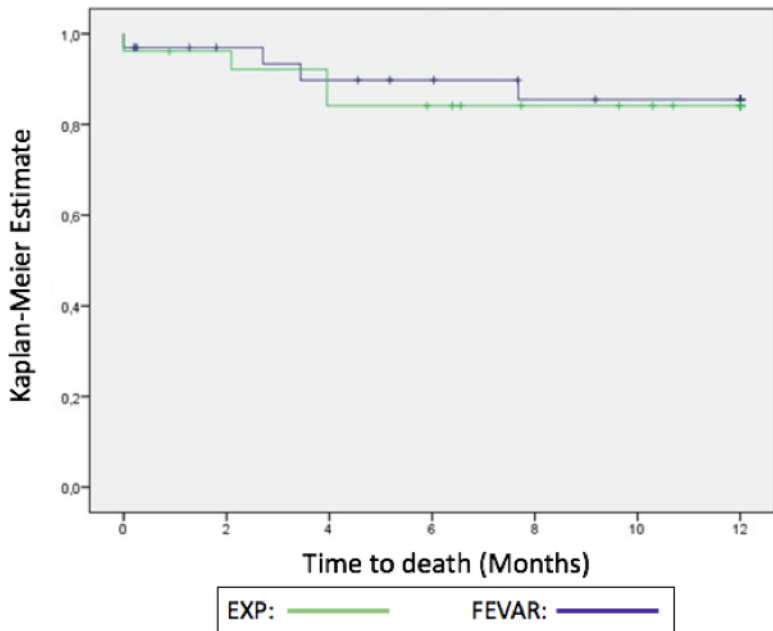
Table 6. Late secondary interventions of patients treated for a type IA endoleak after endovascular aneurysm repair (EVAR) with fenestrated endograft (F-EVAR).

Patient	Indication	Type of procedure	Time from procedure – mo
1	Type Ib endoleak	Hypogastric embolisation and limb extension	53
2	Type II endoleak associated with aneurysmal growth	Surgical explantation of the bifurcated endograft (F-EVAR left in place)	18
3	Type Ic endoleak at the level of a renal stent	Renal stenting extension	28
4	Type Ic endoleak at the level of a renal stent	Renal stenting extension	47

Figure 1. Cumulative Kaplan–Meier estimate of overall survival of patients treated with fenestrated endograft (F-EVAR) or surgical explantation (EXP) for a type IA endoleak (EL) after endovascular aneurysm repair (EVAR).

Figure 2. Decisional algorithm for the management of type IA endoleak after endovascular aneurysm repair (EVAR) including fenestrated endovascular aneurysm repair (F-EVAR) or surgical explantation. OR = open repair.

Freedom from mortality



EVAR with type IA endoleak

non aneurysmal infrarenal neck > 15mm

yes

additional cuff or Palmaz stenting

no

diameter > 80 mm or symptomatic

yes

no

anatomical evaluation

favourable

F-EVAR

unfavourable

no

fit for OR?

no

conservative option

yes

graft explantation