



HAL
open science

Treatment of two infants with PIK3CA-related overgrowth spectrum by alpelisib.

G. Morin, C. Degrugillier-Chopinnet, M. Vincent, A. Fraissenon, H. Aubert, C. Chapelle, C. Huguin, Francois Dubos, Benoit Catteau, Florence Petit, et al.

► To cite this version:

G. Morin, C. Degrugillier-Chopinnet, M. Vincent, A. Fraissenon, H. Aubert, et al.. Treatment of two infants with PIK3CA-related overgrowth spectrum by alpelisib.. *Journal of Experimental Medicine*, 2022, *Journal of Experimental Medicine*, 219, 10.1084/jem.20212148 . hal-04470886

HAL Id: hal-04470886

<https://hal.univ-lille.fr/hal-04470886>

Submitted on 21 Feb 2024

HAL is a multi-disciplinary open access archive for the deposit and dissemination of scientific research documents, whether they are published or not. The documents may come from teaching and research institutions in France or abroad, or from public or private research centers.
























L'archive ouverte pluridisciplinaire **HAL**, est destinée au dépôt et à la diffusion de documents scientifiques de niveau recherche, publiés ou non, émanant des établissements d'enseignement et de recherche français ou étrangers, des laboratoires publics ou privés.



Distributed under a Creative Commons Attribution - NonCommercial - ShareAlike 4.0 International License

BRIEF DEFINITIVE REPORT

Treatment of two infants with PIK3CA-related overgrowth spectrum by alpelisib

Gabriel Morin^{1,2,3*} , Caroline Degrugillier-Chopin^{4*} , Marie Vincent^{5*} , Antoine Fraissenon^{2,6,7,8*} , H  l  ne Aubert⁹ , C  lia Chapelle^{2,3} , Cl  ment Hoguin^{1,2} , Fran  ois Dubos¹⁰ , Benoit Catteau¹¹ , Florence Petit¹² , Aur  lie Mezel¹³ , Olivia Domanski¹⁴ , Guillaume Herbreteau¹⁵ , Marie Alesandrini¹⁶ , Nathalie Boddaert^{1,17} , Nathalie Boutry¹⁸ , Christine Broissand¹⁹ , Tianxiang Kevin Han²⁰ , Fabrice Branle²¹ , Sabine Sarnacki^{1,22} , Thomas Blanc^{1,22} , Laurent Guibaud⁶ , and Guillaume Canaud^{1,2,3} 

PIK3CA-related overgrowth spectrum (PROS) includes rare genetic conditions due to gain-of-function mutations in the PIK3CA gene. There is no approved medical therapy for patients with PROS, and alpelisib, an approved PIK3CA inhibitor in oncology, showed promising results in preclinical models and in patients. Here, we report for the first time the outcome of two infants with PROS having life-threatening conditions treated with alpelisib (25 mg) and monitored with pharmacokinetics. Patient 1 was an 8-mo-old girl with voluminous vascular malformation. Patient 2 was a 9-mo-old boy presenting with asymmetrical body overgrowth and right hemimegalencephaly with West syndrome. After 12 mo of follow-up, alpelisib treatment was associated with improvement in signs and symptoms, morphological lesions and vascular anomalies in the two patients. No adverse events were reported during the study. In this case series, pharmacological inhibition of PIK3CA with low-dose alpelisib was feasible and associated with clinical improvements, including a smaller size of associated complex tissue malformations and good tolerability.

Introduction

PIK3CA-related overgrowth spectrum (PROS) includes rare genetic conditions due to somatic gain-of-function mutations in the PIK3CA gene (Keppler-Noreuil et al., 2015). PIK3CA is a ubiquitously expressed lipid kinase that controls signaling pathways participating in cell proliferation, motility, survival, and metabolism (Vanhaesebroeck et al., 2012). Patients usually have complex tissue malformations, including abnormal vessels, excess adipose tissue, muscle hypertrophy, and bone deformation (Canaud et al., 2021). There are no approved medical therapeutics for patients with PROS. Patients mainly receive supportive care including surgery, sclerotherapy, and psychological and nutritional support (Canaud et al., 2021). Since at the cellular level, PIK3CA recruits the AKT/mechanistic target of

rapamycin pathway (Vanhaesebroeck et al., 2012), some patients are treated with mechanistic target of rapamycin inhibitors. These drugs are associated with some degree of improvement in vascular malformations, but these therapeutics have moderate and inconsistent effects on the volume of the overgrowth (Parker et al., 2019). PROS often results in severe disabilities with deleterious social consequences and premature death (Reis et al., 2018). Gain-of-function variants of PIK3CA are frequently observed in numerous malignant tissues that have targeted drugs (Andr   et al., 2019; Morin and Canaud, 2021).

Recently, alpelisib, a pharmacological inhibitor of PIK3CA approved in oncology for the treatment of advanced breast cancer (Andr   et al., 2019), was demonstrated to be efficient at

¹Universit   de Paris, Paris, France; ²Institut national de la sant   et de la recherche m  dicale U1151, Institut Necker-Enfants Malades, Paris, France; ³Unit   d'Hypercroissance Dysharmonieuse et Anomalies Vasculaires, H  pital Necker-Enfants Malades, Assistance Publique – H  pitaux de Paris, Paris, France; ⁴Service de Physiologie & Explorations Fonctionnelles Cardiovasculaires, Centre Hospitalier Universitaire de Lille, Lille, France; ⁵Service de G  n  tique M  dicale, Centre Hospitalier Universitaire de Nantes, Nantes, France; ⁶Service d'Imagerie P  diatrique, H  pital Femme-M  re-Enfant, Hospices Civils de Lyon, Bron, France; ⁷Service de Radiologie M  re-Enfant, H  pital Nord, Saint Etienne, France; ⁸CREATIS Unit   mixte de recherche 5220, Villeurbanne, France; ⁹Service de Dermatologie, Centre Hospitalier Universitaire de Nantes, Nantes, France; ¹⁰Urgences P  diatriques et Maladies Infectieuses, Centre Hospitalier Universitaire de Lille, Lille, France; ¹¹Clinique de Dermatologie, Centre Hospitalier Universitaire de Lille, Lille, France; ¹²Clinique de G  n  tique, Centre Hospitalier Universitaire de Lille, Lille, France; ¹³Service d'Orthop  die P  diatrique, Centre Hospitalier Universitaire de Lille, Lille, France; ¹⁴Service de Cardiologie P  diatrique et Cong  nitale, Centre Hospitalier Universitaire de Lille, Lille, France; ¹⁵Laboratoire de Biochimie, Centre Hospitalier Universitaire de Nantes, Nantes, France; ¹⁶Service de P  diatrie, Centre Hospitalier Universitaire de Nantes, Nantes, France; ¹⁷Service d'Imagerie P  diatrique, H  pital Necker-Enfants Malades, Paris, France; ¹⁸Service de Radiologie et Imagerie de l'Enfant, Centre Hospitalier Universitaire Jeanne de Flandre, Lille, France; ¹⁹Pharmacie, H  pital Necker-Enfants Malades, Assistance Publique – H  pitaux de Paris, Paris, France; ²⁰Novartis Pharmaceuticals Corporation, East Hanover, NJ; ²¹Novartis Pharma AG, Basel, Switzerland; ²²Service de Chirurgie Visc  rale P  diatrique, H  pital Necker-Enfants Malades, Paris, France.

*G. Morin, C. Degrugillier-Chopin, M. Vincent, and A. Fraissenon contributed equally to this paper; Correspondence to Guillaume Canaud: guillaume.canaud@inserm.fr.

   2022 Morin et al. This article is distributed under the terms of an Attribution–Noncommercial–Share Alike–No Mirror Sites license for the first six months after the publication date (see <http://www.rupress.org/terms/>). After six months it is available under a Creative Commons License (Attribution–Noncommercial–Share Alike 4.0 International license, as described at <https://creativecommons.org/licenses/by-nc-sa/4.0/>).

preventing and improving organ dysfunction in a preclinical mouse model of PROS and showed encouraging preliminary results in adult and pediatric patients with severe forms of PROS (Castel et al., 2016; Garneau et al., 2021; López Gutiérrez et al., 2019; Pagliuzzi et al., 2021; Venot et al., 2018). Alpelisib was also demonstrated to be particularly efficient on the lymphatic compounds of the malformations in a mouse model and in patients including pediatrics (Delestre et al., 2021). Indeed, alpelisib is currently being investigated in clinical trials for this indication (NCT04285723 for EPIK-P1, NCT04589650 for EPIK-P2, and NCT04980833 for EPIK-P3). However, efficacy, safety, and pharmacokinetic (PK) data in very young patients are lacking. Here, we report the efficacy and safety outcomes of oral alpelisib at 25 mg used for the treatment of two infants with PROS who were monitored with PK.

Results and discussion

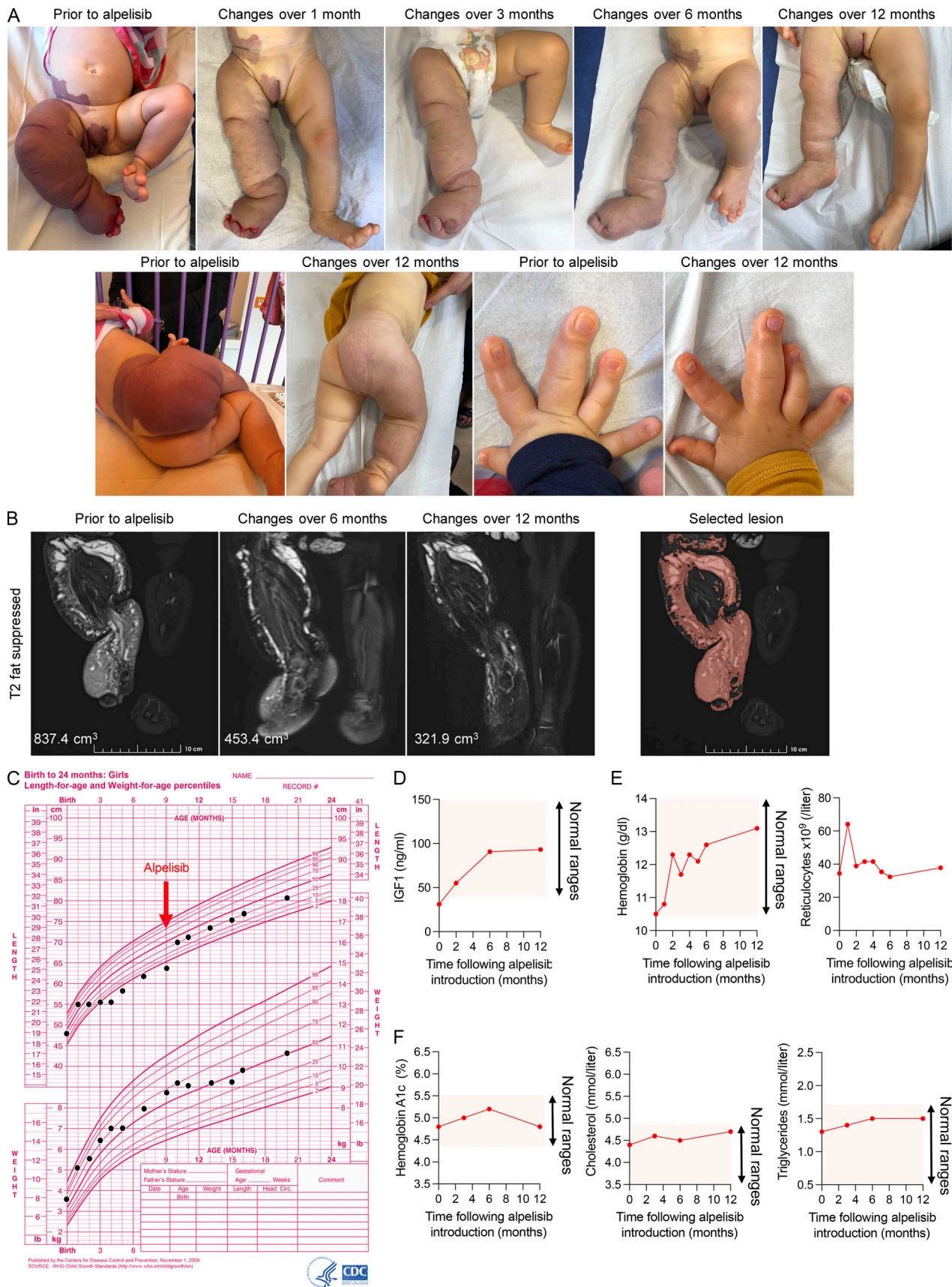
Patient 1 was a 9-mo-old girl born with PROS (previously called congenital lipomatous overgrowth, vascular malformations, epidermal nevis, spinal/skeletal anomalies/scoliosis) with severe clinical presentation associated with mixed, lymphatic, and venous malformations, involving retroperitoneum, pelvis, and right limb (Fig. 1 A). Malformations were associated with asymmetrical overgrowth of the right limb and the foot, bilateral toes macrodactyly, and macrodactyly of the second, third, and fourth fingers of the right hand (Fig. 1 A). Skin biopsy performed on the right limb at day 4 of life and targeted genetic analysis identified a c.1349_1366del, p.His450_Leu455del, *PIK3CA* variant with a frequency of 3%. During the first 6 mo of life, she had four episodes of cellulitis with septic shock and one episode of femoral deep venous thrombosis. At the age of 6 mo, preventive treatment with warfarin and phenoxymethylpenicillin was instituted, but cellulitis recurred. Magnetic resonance imaging (MRI) showed diffuse venous and lymphatic malformations of the right limb with subcutaneous and intramuscular localization and pelvic and retroperitoneal extension (Fig. 1 B). Lesions were not accessible to surgery or interventional procedures. Additionally, because of the malformation, she could not stand up or walk. Biological examination showed moderate nonregenerative anemia due to chronic inflammatory syndrome in the context of recurrent infections and local bleeding (Fig. 1 E). At 9 mo of age, because of the life-threatening condition, we started alpelisib at a dose of 25 mg/d. Alpelisib introduction was associated with rapid clinical improvement, including capillary malformation discoloration, and important volume reduction of the right leg and the mixed vascular malformations (Fig. 1 A). After 12 mo of treatment, the right leg was less infiltrated, and the foot was more flexible. She was able to stand up and to walk with assistance. During the follow-up, no episodes of inflammatory flares or infections were noticed. We could stop the preventive administration of phenoxymethylpenicillin and warfarin 3 mo and 11 mo after alpelisib introduction, respectively. MRI showed a decrease in the volume of lymphatic malformations of the right leg from 837.4 cm³ before alpelisib introduction to 454.3 and 321.9 cm³ over 6 and 12 mo on alpelisib, respectively (change from baseline to 6 mo was -45.7% and to 12 mo was -61.5%; Fig. 1

B and Fig. S1). Following alpelisib introduction, we observed a progressive reduction in the volume of the hand macrodactyly (Fig. 1 A). Before alpelisib introduction, we noticed faltering growth (Fig. 1 C) associated with low circulating IGF1 levels (Fig. 1 D). Following alpelisib, we noticed that growth was restored (Fig. 1 C). This was associated with a correction of the circulating levels of IGF1 (Fig. 1 D). Biologically, we observed a progressive increase in hemoglobin levels (Fig. 1 E) and no changes in HbA1c, cholesterol, or triglyceride levels (Fig. 1 F). During the follow-up, no adverse events were reported by either parents or treating physicians.

Patient 2 was an 8-mo-old boy with PROS (previously called megalencephaly capillary malformation). He presented with right hemimegalencephaly; asymmetrical overgrowth of the right buttock, limb, and foot; diffuse superficial capillary malformations; and discrete hypertrophy of the right cheek (Fig. 2 A). On day 18 of life, a skin biopsy was performed on the capillary malformation of the left leg, and a c.3132T>A, p.Asn1044Lys, *PIK3CA* variant was identified with a frequency of 14.8%. At 2 mo, he developed West syndrome with flexion spasms and left hemiparesis. Brain MRI revealed the presence of right hemimegalencephaly with increased volume of the right hemisphere and thickening of the cortex with morphological anomalies of the sulci suggestive of pachygyria and developmental venous anomalies (Fig. 2 B). Electroencephalogram showed right temporoparietal fast rhythms, and biological examination showed anemia with hypercholesterolemia. Treatment with vigabatrin and steroids was instituted, and spasms disappeared. Because of neurological concerns, delayed acquisition, and global hypotonia, alpelisib was started at a dose of 25 mg/d at the age of 8 mo.

Following alpelisib introduction, clinical spasms did not relapse, and psychomotor development was normal. Electroencephalogram performed at 3 and 6 mo after alpelisib introduction showed globally stable tracing, with persistence of a right temporal interictal epileptic activity. Because of epilepsy improvement, vigabatrin was stopped 8 mo following alpelisib introduction and replaced by sodium valproate. Sodium valproate and steroids are planned to be stopped within the next 6 mo now. Although we noticed progress in behavior and acquisition, it was very hard to distinguish between normal progression or improvement related to alpelisib. Clinically, we observed capillary malformation discoloration and gain in tonicity with walk acquisition (Fig. 2 A). In patient 1, we noticed faltering growth (Fig. 2 C) associated with low circulating IGF1 levels before alpelisib introduction (Fig. 2 D), which were restored after starting the drug (Fig. 2, C and D). Following alpelisib introduction, head circumference seemed to show moderate inflection (Fig. 2 E). Biologically, hemoglobin and cholesterol levels were progressively corrected (Fig. 2 F). We observed transient hypertriglyceridemia at month 3 after alpelisib introduction (Fig. 2 F). HbA1c remained stable during the follow-up (Fig. 2 F). Brain MRI at 3 and 12 mo did not reveal any modification of the right encephala anatomy (Fig. 2 B). No adverse events were reported during the follow-up in patient 2.

To monitor exposure for safety precaution considerations, we performed PK analysis of alpelisib and its first metabolite



Downloaded from http://rupress.org/jem/article-pdf/121/19/3/e20212148/1804036/jem_20212148.pdf by guest on 21 February 2024

Figure 1. **Changes associated with alpelisib in a 9-mo-old patient with a severe form of PROS.** (A) Representative pictures of the vascular malformations of the pelvis and right leg before and then following alpelisib introduction. Lower right: Macrodactyly of the right hand before and then 12 mo after alpelisib

introduction. **(B)** Coronal STIR-weighted MRI of the legs of patient 1 before and following alpelisib introduction (scale bar: 10 cm). **(C)** Growth characteristics before and after alpelisib introduction. **(D)** Circulating IGF1 levels before and following alpelisib introduction. The pink area shows normal values of the laboratory for the age. **(E)** Hemoglobin and reticulocyte levels before and after alpelisib introduction. The pink area shows normal values of the laboratory for the age. **(F)** HbA1c, cholesterol, and triglyceride levels before and following alpelisib introduction. The pink area shows normal values of the laboratory for the age.

(BZG791). Samples were collected in both patients at 3 h after dose on the first day of treatment and at before dose and 3 h after dose on day 84. The results are shown in Table 1. The steady-state C_{max} (maximum serum concentration achieved by a drug) in young infants at the 25-mg dose was similar to the observed steady-state C_{max} in adult cancer patients in the 60–90 mg dose range (475–849 ng/ml), and much lower than that in adult cancer patients at the approved 300-mg dose. In adult cancer patients, accumulation was minimal (1.3–1.5-fold for per-day [QD] dosing). However, the accumulation in these two infants was higher (approximately fourfold for QD dosing) based on C_{max}. The relative abundance of the major metabolite BZG791 compared with alpelisib in adult cancer patients was 20–30%, but it was likely to be lower in these infants.

In this report, two infants with PROS treated with alpelisib demonstrated clinical, biological, and radiological improvements. Alpelisib was not associated with adverse events during the 12-mo follow-up. Faltering growth was restored following alpelisib introduction in both patients.

In a proof-of-concept study, we recently demonstrated alpelisib efficacy in a mouse model of PROS and in a few patients (Venot et al., 2018). These data were then confirmed in additional case reports (Garneau et al., 2021; López Gutiérrez et al., 2019; Pagliuzzi et al., 2021) and very recently in the EPIK-P1 clinical trial (NCT04285723), a retrospective chart review of patients receiving alpelisib for compassionate use under a managed access program (Canaud, G., J.C. López Gutiérrez, A. Irvine, N. Ankrah, A. Papadimitriou, A. Ridolfi, and D.M. Adams. 2021. European Society for Medical Oncology Annual Meeting. Abstr. LBA23). However, in the EPIK-P1 study, no infants were included, and no PK analysis were performed. Currently, a randomized controlled study is ongoing to assess the efficacy of alpelisib in patients with PROS (EPIK P2-NCT04589650). In EPIK-P2, no children under 2 yr of age are eligible, and preliminary results are expected in 2024. Therefore, the data presented here are unique, since we report the first infants ever treated with alpelisib, and we provide for the first time PK analysis in patients with PROS.

Interestingly, we recently created a mouse model of specific *PIK3CA* gain-of-function mutation specifically in lymphatic endothelial cells and demonstrated in the mouse model and then in patients, including pediatrics (2–39 yr old), that alpelisib was very efficient at improving isolated or generalized lymphatic malformations (Delestre et al., 2021). This observation is consistent with the dramatic improvement observed in patient 1 that presented with complex and extensive vascular malformations mixing lymphatic and vein anomalies. In the present paper, we have tried to provide objective changes to support the efficacy of alpelisib in the two patients. Indeed, we could measure and monitor the volume of the malformations in patient

1 using MRI. In addition, biological changes were observed following alpelisib initiation such as the correction of anemia in both patients. Anemia in patients with PROS is explained by chronic bleeding, inflammation, or malabsorption (Canaud et al., 2021). Meaningful clinical impacts were also noticed. Notably, following alpelisib initiation, patient 1 did not experience any new sepsis or hospitalization. In patient 2, alpelisib initiation was associated with the control of epilepsy. The impact of *PIK3CA* inhibition on epilepsy is intriguing since the drug is not supposed to cross the blood–brain barrier. It is tempting to speculate that alpelisib induces modifications of the cerebral microcirculation leading to improved perfusion, and/or that an abnormal blood–brain barrier allows the passage of alpelisib or its derivative in patients with megalencephaly. The effect of this drug on this specific population deserves further investigation.

We further noticed correction of the faltering growth in both patients. We have attributed the low IGF1 circulating levels observed in both patients to the chronic illness (Suris et al., 2004), and their resumption may be favored by the improvement of patients' general condition (Suris et al., 2004).

PK data of alpelisib reported here are the first obtained in patients with PROS and the first PK data obtained in pediatric patients of any disease status. These data, even limited, suggested higher accumulation of alpelisib and lower relative abundance of the major metabolite M4 (BZG791) in these two young children, indicating likely lower clearance and longer half-life of alpelisib in these young children with PROS compared with adult cancer patients (Bertho et al., 2021). The C_{max} observed following 25 mg alpelisib in these children was well below the approved adult dose of 300 mg in adult cancer patients (steady-state C_{max} ~3,000 ng/ml; Bertho et al., 2021). Given the well-established safety profile of alpelisib at the approved 300-mg dose in adults, these low exposures support the continuous treatment of 25 mg alpelisib in these young patients with PROS.

The limitations of the study include the variability of the clinical presentation of patients in this work, the small number of patients, and the potential patient selection bias since only patients with severe forms of PROS were treated with alpelisib.

In conclusion, alpelisib in these two infants gave encouraging results that should be interpreted with caution and will have to be confirmed by future studies.

Materials and methods

The two patients were treated at Hôpital Necker Enfants Malades, Université de Paris, under a compassionate use program. This program was approved by French regulatory agency (Agence nationale de sécurité du médicament et des produits de santé) for patients with severe conditions and for whom no

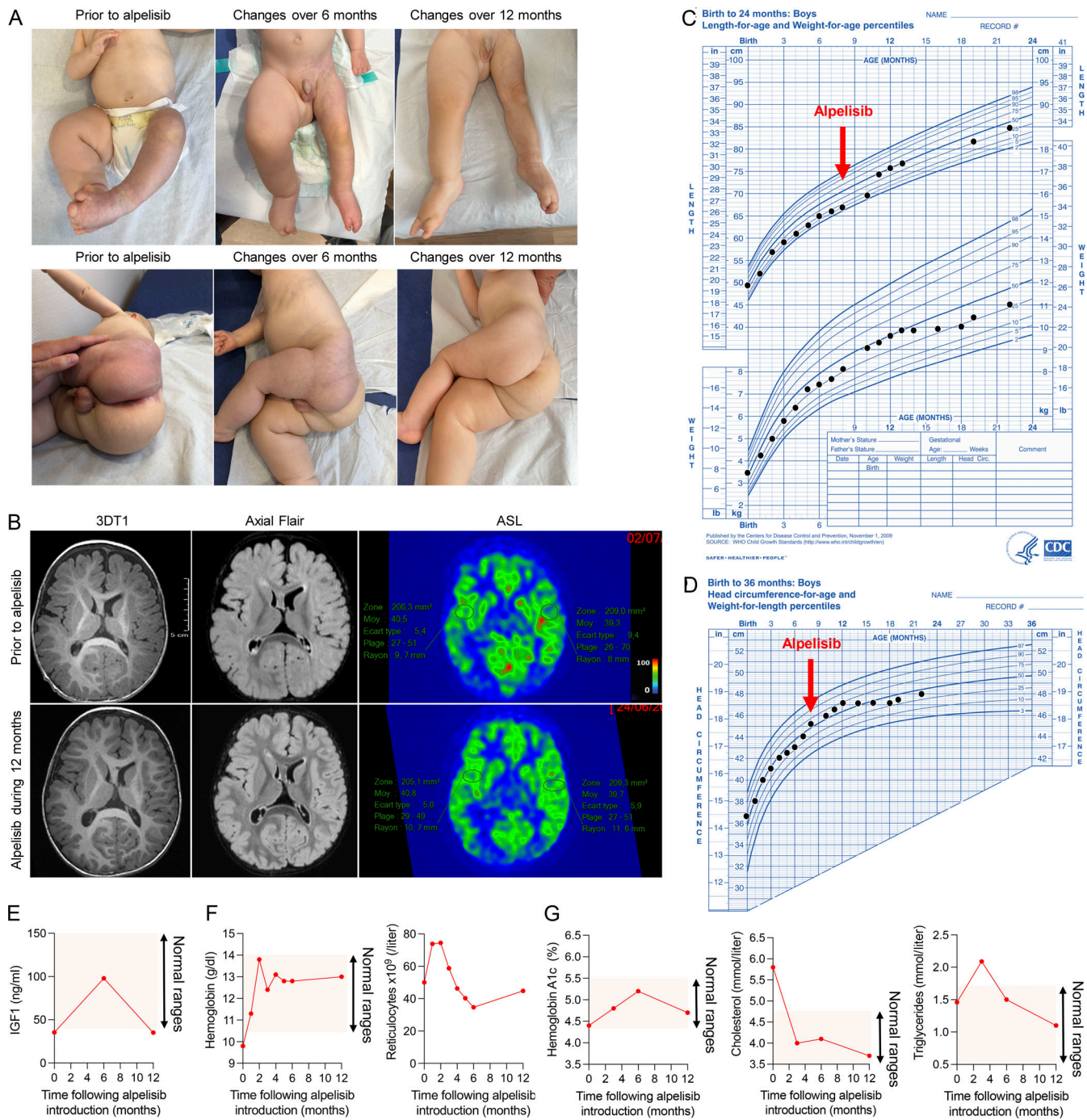


Figure 2. Changes associated with alpelisib in an 8-mo-old patient with a severe form of PROS and hemimegalencephaly. (A) Representative pictures of overgrowth of the right limb and vascular malformations of the left leg before and then following alpelisib introduction. **(B)** Brain MRI of patient 2 before and following alpelisib introduction (scale bar: 5 cm). ASL, arterial spin labeling. **(C)** Growth characteristics before and after alpelisib introduction. **(D)** Evolution of head circumference before and after alpelisib introduction. **(E)** Circulating IGF1 levels before and following alpelisib introduction. The pink area shows normal values of the laboratory for the age. **(F)** Hemoglobin and reticulocyte levels before and after alpelisib introduction. The pink area shows normal values of the laboratory for the age. **(G)** HbA1c, cholesterol, and triglyceride levels before and following alpelisib introduction. The pink area shows normal values of the laboratory for the age.

other treatment is feasible. In this context, parents provided their consent. Predefined efficacy and safety assessments were performed to monitor the efficacy and safety of treatment. Exceptionally, in these two cases, PK samples were taken to inform the best management of the patient.

The study was conducted from July 2020 to August 2021. Patients had a documented *PIK3CA* gain-of-function variant in affected tissues and no family history of overgrowth syndrome.

Patients underwent MRI follow-up before alpelisib introduction and then at 6 and 12 mo on treatment. For patient 1, as a

Table 1. PK results following oral 25-mg alpelisib in the two infants

	Time	Alpelisib concentration (ng/ml)	BZG791 concentration (ng/ml)
Patient 1			
First dose	3 h after dose	96.1	3.26
Steady-state	0 h before dose (C _{trough} , ss)	188	6.82
Steady-state	3 h after dose (C _{max} , ss)	543	11.6
Patient 2			
First dose	3 h after dose	240	11.9
Steady-state	0 h before dose (C _{trough} , ss)	85.5	4.88
Steady-state	3 h after dose (C _{max} , ss)	835	28.8

C_{trough}, concentration reached by a drug immediately before the next dose is administered; ss, steady-state.

lesion of interest, we monitored pelvic and right leg malformations using T1-, T2-, and short TI inversion recovery (STIR)-weighted sequences. Volumetric evaluation of the lesion was determined with 3D Slicer software by thresholding and delineating the contours of the lesion image by image (Fedorov et al., 2012). Volume was calculated by summing images based on the two-dimensional contours and slice thickness. For patient 2, the brain was monitored. Three-dimensional (3D) T1, T2 axial, 3D flair, 3D star-weighted angiography, diffusion, arterial spin labeling, T1, and T1-fat saturation with gadolinium-weighted sequences were used.

Alpelisib was delivered orally every morning during breakfast at a dose of 25 mg QD, and this regimen began in the hospital.

Adverse events were graded according to the National Cancer Institute Common Terminology Criteria for Adverse Events, version 5.0. Glycemia was monitored before every meal over 1 wk and then stopped. Patients underwent regular physical examination. The growth of the children was monitored at each clinical appointment. Laboratory evaluation was performed at baseline before drug initiation and then on the same schedule as clinical follow-up. Blood tests included blood electrolytes; complete blood count with platelets; and measurements of the levels of C-reactive protein, D-dimer, fibrinogen, HbA1c, low-density lipoprotein cholesterol, triglycerides, alanine aminotransferase, aspartate aminotransferase, alkaline phosphatase, serum creatinine, blood urea nitrogen, creatine phosphokinase, amylase, lipase, lactate dehydrogenase, IGF1, and serum uric acid. Urinary dipstick testing was performed.

Clinical characteristics and laboratory and imaging measurements were compared descriptively between prior and following alpelisib introduction. Data from the two patients were available during the 12-mo follow-up. Because of the small number of cases, formal statistical testing was not conducted; the findings should be interpreted as descriptive and exploratory.

In both patients, PK analysis of alpelisib and its first metabolite (BZG791) was performed at two time points, 3 h following the first dose of alpelisib and then on day 84 of treatment. For the latter, alpelisib and its metabolites were measured at steady-state before dose and then 3 h after dose. PK analysis was

performed to support the management of alpelisib in case of safety issues. At the request of the treating physicians, PK was performed by Novartis.

Online supplemental material

Fig. S1 provides additional radiological changes associated with alpelisib in patient 1.

Data availability

All the data are presented in the main text.

Acknowledgments

This study was supported by the European Research Council (CoG 2020 101000948 to G. Canaud), the Agence Nationale de la Recherche—Programme d'Investissements d'Avenir (ANR-18-RHUS-005 to G. Canaud), the Agence Nationale de la Recherche—Programme de Recherche Collaborative (19-CE14-0030-01 to G. Canaud) and the Fondation pour la Recherche Médicale (FDM202006011222 to G. Morin). This work was also supported by the CLOVES Syndrome Community to G. Canaud, Fonds de Dotation Emmanuel Boussard to G. Canaud, the Fondation Day Solvay to G. Canaud, the Fondation Tourre to G. Canaud, the Fondation Bettencourt Schueller to G. Canaud, the Fondation Simone et Cino Del Duca to G. Canaud, the Fondation Line Renaud-Loulou Gaste to G. Canaud, the Fondation Schlumberger pour l'Éducation et la Recherche to G. Canaud, the Association Robert Debré pour la Recherche Médicale awarded to G. Canaud, Institut national de la santé et de la recherche médicale, Assistance Publique Hôpitaux de Paris, and l'Université de Paris. We are also very grateful to our generous donors.

G. Morin, C. Degrugillier-Chopin, M. Vincent, H. Aubert, F. Dubos, B. Catteau, F. Petit, A. Mezel, O. Domanski, G. Herbreteau, M. Alesandrini, C. Broissand, S. Sarnaki, and T. Blanc followed the patients. A. Fraissenon, N. Boddaert, N. Boutry, and L. Guibaud designed and analyzed MRI follow-up. C. Chapelle and C. Hoguin were in charge of serum samples for PK analysis. T.K. Han and F. Branle provided support and performed PK analysis. G. Canaud followed the patients, provided the conceptual framework, designed the study, supervised the project, and wrote the paper.

Disclosures: F. Dubos reported personal fees from Sanofi-Pasteur, MSD, and Takeda outside the submitted work. T.K. Han reported being an employee at Novartis. F. Branle reported "other" from Novartis.Pharma.AG during the conduct of the study; and is a full-time employee of Novartis.Pharma AG Switzerland. A patent application ("BYL719 [alpelisib] for use in the treatment of PIK3CA-related overgrowth spectrum"; #WO2017140828A1) has been filed by Institut National de la Santé et de la Recherche Médicale, Centre National De La Recherche Scientifique, Université Paris Descartes, and Assistance Publique-Hôpitaux De Paris for the use of BYL719 (alpelisib) in the treatment of PIK3CA-related overgrowth spectrum (PROS/CLOVES syndrome). G. Canaud is the inventor. G. Canaud receives or has received consulting fees from Novartis, Vaderis, Fresenius Medical Care, Alkermes, IPSEN, and BridgeBio. No other disclosures were reported.

Submitted: 18 October 2021

Revised: 25 November 2021

Accepted: 3 January 2022

References

- André, F., E. Ciruelos, G. Rubovszky, M. Campone, S. Loibl, H.S. Rugo, H. Iwata, P. Conte, I.A. Mayer, B. Kaufman, et al. SOLAR-1 Study Group. 2019. Alpelisib for PIK3CA-Mutated, Hormone Receptor-Positive Advanced Breast Cancer. *N. Engl. J. Med.* 380:1929–1940. <https://doi.org/10.1056/NEJMoal813904>
- Bertho, M., A. Patsouris, P. Augereau, M. Robert, J.S. Frenel, C. Blonz, and M. Campone. 2021. A pharmacokinetic evaluation of alpelisib for the treatment of HR+, HER2-negative, PIK3CA-mutated advanced or metastatic breast cancer. *Expert Opin. Drug Metab. Toxicol.* 17:139–152. <https://doi.org/10.1080/17425255.2021.1844662>
- Canaud, G., A.M. Hammill, D. Adams, M. Vikkula, and K.M. Keppler-Noreuil. 2021. A review of mechanisms of disease across PIK3CA-related disorders with vascular manifestations. *Orphanet J. Rare Dis.* 16:306. <https://doi.org/10.1186/s13023-021-01929-8>
- Castel, P., F.J. Carmona, J. Grego-Bessa, M.F. Berger, A. Viale, K.V. Anderson, S. Bague, M. Scaltriti, C.R. Antonescu, E. Baselga, and J. Baselga. 2016. Somatic PIK3CA mutations as a driver of sporadic venous malformations. *Sci. Transl. Med.* 8:332ra42. <https://doi.org/10.1126/scitranslmed.aaf1164>
- Delestre, F., Q. Venot, C. Bayard, A. Fraissenon, S. Ladraa, C. Huguin, C. Chapelle, J. Yamaguchi, R. Cassaca, L. Zerbib, et al. 2021. Alpelisib administration reduced lymphatic malformations in a mouse model and in patients. *Sci. Transl. Med.* 13:eabg0809. <https://doi.org/10.1126/scitranslmed.abg0809>
- Fedorov, A., R. Beichel, J. Kalpathy-Cramer, J. Finet, J.C. Fillion-Robin, S. Pujol, C. Bauer, D. Jennings, F. Fennessy, M. Sonka, et al. 2012. 3D Slicer as an image computing platform for the Quantitative Imaging Network. *Magn. Reson. Imaging.* 30:1323–1341. <https://doi.org/10.1016/j.mri.2012.05.001>
- Garneau, A.P., L. Haydock, L.E. Tremblay, and P. Isenring. 2021. Somatic non-cancerous PIK3CA-related overgrowth syndrome treated with alpelisib in North America. *J. Mol. Med. (Berl.)*. 99:311–313. <https://doi.org/10.1007/s00109-020-02030-6>
- Keppler-Noreuil, K.M., J.J. Rios, V.E. Parker, R.K. Semple, M.J. Lindhurst, J.C. Sapp, A. Alomari, M. Ezaki, W. Dobyns, and L.G. Biesecker. 2015. PIK3CA-related overgrowth spectrum (PROS): diagnostic and testing eligibility criteria, differential diagnosis, and evaluation. *Am. J. Med. Genet. A.* 167A:287–295. <https://doi.org/10.1002/ajmg.a.36836>
- López Gutiérrez, J.C., R. Lizarraga, C. Delgado, M.J. Martínez Urrutia, M. Díaz, M. Miguel, and P. Triana. 2019. Alpelisib Treatment for Genital Vascular Malformation in a Patient with Congenital Lipomatous Overgrowth, Vascular Malformations, Epidermal Nevi, and Spinal/Skeletal Anomalies and/or Scoliosis (CLOVES) Syndrome. *J. Pediatr. Adolesc. Gynecol.* 32:648–650. <https://doi.org/10.1016/j.jpjag.2019.07.003>
- Morin, G., and G. Canaud. 2021. Treatment strategies for mosaic overgrowth syndromes of the PI3K-AKT-mTOR pathway. *Br. Med. Bull.* 140:36–49. <https://doi.org/10.1093/bmb/ldab023>
- Pagliuzzi, A., T. Oranges, G. Traficante, C. Trapani, F. Facchini, A. Martin, A. Semeraro, A. Perrone, C. Filippeschi, and S. Giglio. 2021. PIK3CA-Related Overgrowth Spectrum From Diagnosis to Targeted Therapy: A Case of CLOVES Syndrome Treated With Alpelisib. *Front Pediatr.* 9:732836. <https://doi.org/10.3389/fped.2021.732836>
- Parker, V.E.R., K.M. Keppler-Noreuil, L. Faivre, M. Luu, N.L. Oden, L. De Silva, J.C. Sapp, K. Andrews, M. Bardou, K.Y. Chen, et al. PROMISE Working Group. 2019. Safety and efficacy of low-dose sirolimus in the PIK3CA-related overgrowth spectrum. *Genet. Med.* <https://doi.org/10.1038/s41436-018-0297-9>
- Reis, J. III, A.I. Alomari, C.C. Trenor III, D.M. Adams, S.J. Fishman, S.A. Spencer, R. Shaikh, A.P. Lillis, M.K. Surnedi, and G. Chaudry. 2018. Pulmonary thromboembolic events in patients with congenital lipomatous overgrowth, vascular malformations, epidermal nevi, and spinal/skeletal abnormalities and Klippel-Trénaunay syndrome. *J. Vasc. Surg. Venous Lymphat. Disord.* 6:511–516. <https://doi.org/10.1016/j.jvsv.2018.01.015>
- Suris, J.C., P.A. Michaud, and R. Viner. 2004. The adolescent with a chronic condition. Part I: developmental issues. *Arch. Dis. Child.* 89:938–942. <https://doi.org/10.1136/adc.2003.045369>
- Vanhaesebroeck, B., L. Stephens, and P. Hawkins. 2012. PI3K signalling: the path to discovery and understanding. *Nat. Rev. Mol. Cell Biol.* 13:195–203. <https://doi.org/10.1038/nrm3290>
- Venot, Q., T. Blanc, S.H. Rabia, L. Berteloot, S. Ladraa, J.P. Duong, E. Blanc, S.C. Johnson, C. Huguin, O. Boccara, et al. 2018. Targeted therapy in patients with PIK3CA-related overgrowth syndrome. *Nature.* 558: 540–546. <https://doi.org/10.1038/s41586-018-0217-9>

Supplemental material

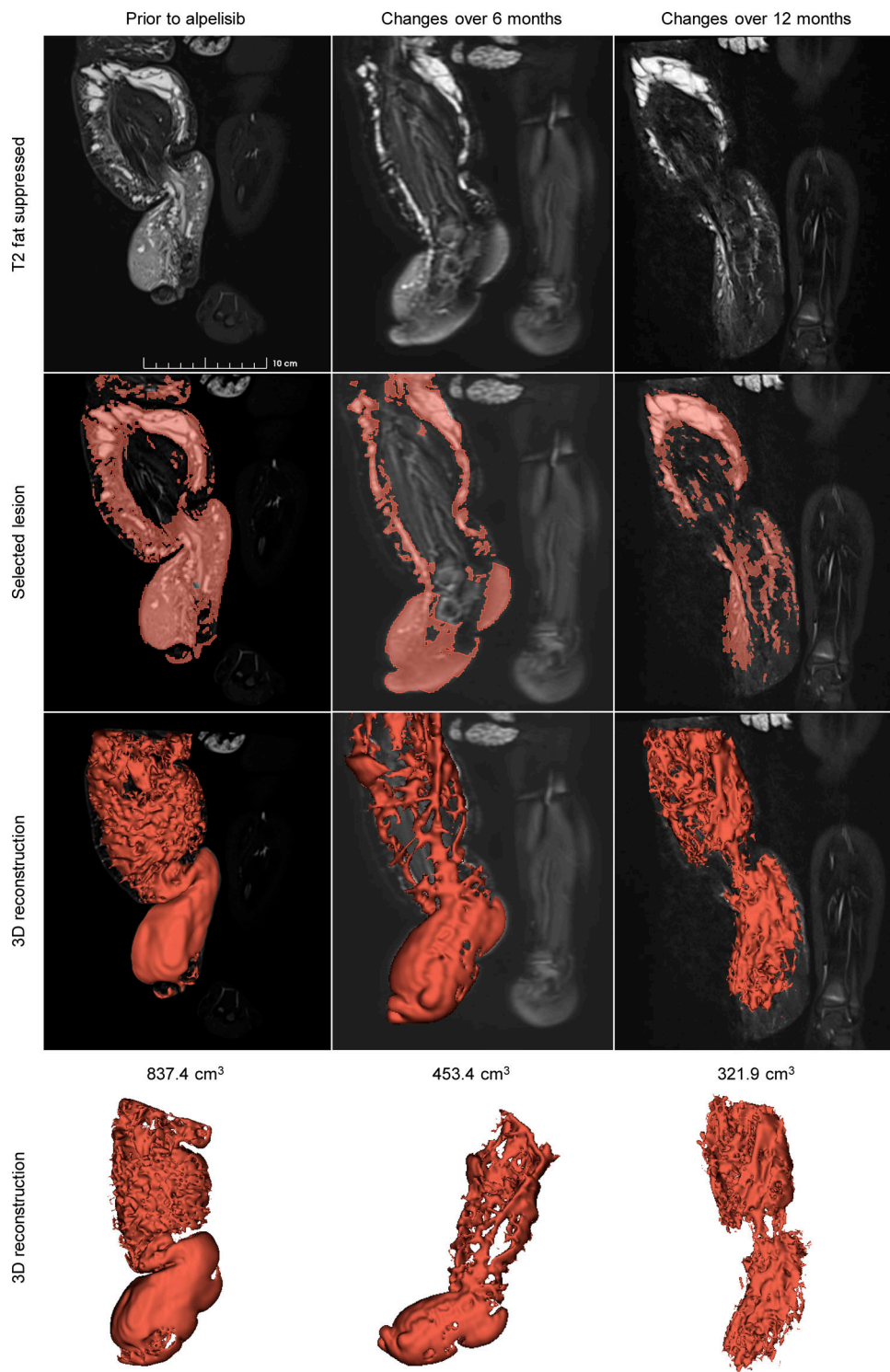


Figure S1. Radiological changes associated with alpelisib in a 9-mo-old patient with a severe form of PROS. Coronal STIR-weighted MRI with 3D reconstruction of the legs of patient 1 before and following alpelisib introduction (scale bar: 10 cm).