



HAL
open science

Electro-clinical presentation of hereditary transthyretin related amyloidosis when presenting as a polyneuropathy of unknown origin in northern France.

Jean-Baptiste Davion, P. Bocquillon, F. Cassim, N. Frezel, Alexandre Lacour, Claire-Marie Dhaenens, Claude-Alain Maurage, J. B. Gibier, Eric Hachulla, Sylvie Nguyen The Tich, et al.

► To cite this version:

Jean-Baptiste Davion, P. Bocquillon, F. Cassim, N. Frezel, Alexandre Lacour, et al.. Electro-clinical presentation of hereditary transthyretin related amyloidosis when presenting as a polyneuropathy of unknown origin in northern France.. *Revue Neurologique*, 2021, *Revue Neurologique*, 10.1016/j.neurol.2021.02.392 . hal-04480571

HAL Id: hal-04480571

<https://hal.univ-lille.fr/hal-04480571v1>

Submitted on 22 Jul 2024

HAL is a multi-disciplinary open access archive for the deposit and dissemination of scientific research documents, whether they are published or not. The documents may come from teaching and research institutions in France or abroad, or from public or private research centers.

L'archive ouverte pluridisciplinaire **HAL**, est destinée au dépôt et à la diffusion de documents scientifiques de niveau recherche, publiés ou non, émanant des établissements d'enseignement et de recherche français ou étrangers, des laboratoires publics ou privés.



Distributed under a Creative Commons Attribution - NonCommercial 4.0 International License

Title: Electro-clinical presentation of hereditary transthyretin related amyloidosis when presenting as a polyneuropathy of unknown origin in northern France

Authors and affiliations: Jean-Baptiste Davion MD^{1,7}, Perrine Bocquillon MD², François Cassim MD², Nadia Frezel MD², Arnaud Lacour MD³, Claire-Marie Dhaenens PharmD PhD⁴, Claude-Alain Maurage MD PhD⁵, Jean-Baptiste Gibier MD⁵, Eric Hachulla MD PhD⁶, Sylvie Nguyen MD PhD^{1,7}, Luc Defebvre MD PhD⁸, Philippe-Edouard Merle MD⁹, Céline Tard MD PhD^{1,8}

¹Centre de référence des Maladies Neuromusculaires, CHU Lille, F-59000, Lille, France

² Service de Neurophysiologie clinique, CHU Lille, F-59000, Lille, France

³ Service de Neurologie, CHU de Saint-Etienne, 42000, Saint-Etienne, France

⁴ University of Lille, Inserm UMR-S 1172, CHU Lille, Biochemistry and Molecular Biology Department - UF Génopathies, Lille, France

⁵ Service de Pathologie, CHU Lille, F-59000, Lille, France

⁶ Service de Médecine Interne et Immunologie Clinique, CHU Lille, F-59000 Lille, France

⁷ Service de Neurologie pédiatrique, CHU Lille, F-59000, Lille, France

⁸ Service de Neurologie et pathologie du mouvement, CHU Lille, F-59000, Lille, France

⁹ Service des Explorations Fonctionnelles du Système Nerveux, CHU Amiens-Picardie, 80000 Amiens, France

Corresponding author: Jean-Baptiste Davion
jeanbaptiste.davion@chru-lille.fr
Neurologie, hôpital Roger Salengro
Avenue Emile Laine, CHRU Lille, 59037 Lille cedex, France

Keywords: TTR, transthyretin, amyloidosis, neuropathy, electromyography, northern France

Running title: TTR North of France

Ethical Publication Statement: We confirm that we have read the Journal's position on issues involved in ethical publication and affirm that this report is consistent with those guidelines.

Disclosure of Conflicts of Interest: Jean-Baptiste Davion has received travel grants from Alnylam. Eric Hachulla has received consultant fees from AKCEA Therapeutics. Céline Tard has received consultant fees from AKCEA Therapeutics, Sanofi-Genzyme, Pfizer, Alnylam, Ultragenyx, and was investigator for studies promoted by Pharnext, Alnylam, Sanofi-Genzyme, Amicus. The remaining authors have no conflicts of interest.

INTRODUCTION: Hereditary transthyretin related amyloidosis (h-ATTR) classically presents as a small fiber neuropathy with positive family history, but can also be revealed by various other types of peripheral neuropathy.

OBJECTIVE: To describe the initial electro-clinical presentation of patients from in a single region (northern France) of h-ATTR when it presents as a polyneuropathy of unknown origin.

METHOD: We reviewed the records of patients referred to two neuromuscular centers from northern France with a peripheral neuropathy of unknown origin who were subsequently diagnosed with h-ATTR.

RESULTS: Among 26 h-ATTR patients (10 Val30Met, 16 Ser77Tyr), only 14 patients had a suspicious family history (53.8%). The electro-clinical presentation was mostly a large-fiber sensory motor polyneuropathy (92.3%), which could be symmetric or not, length-dependent or not, or associated with nerve entrapment or not. Demyelinating signs were observed in 17 patients (70.8%), among whom nine fulfilled the criteria for a definite diagnosis of chronic inflammatory demyelinating polyradiculoneuropathy (37.5%).

CONCLUSION: h-ATTR may have a wide spectrum of clinical profiles, and should be considered in the screening of polyneuropathies of unknown origin.

Keywords : TTR; transthyretin; Amyloidosis; Neuropathy; electromyography

Introduction

Hereditary transthyretin related amyloidosis (h-ATTR) is a genetic condition related to a pathogenic mutation in the *TTR* gene, leading to the production of unstable monomers of transthyretin which progressively aggregate to form amyloid deposits in several organs (Fig. 1) (1). Although the type of mutation impacts the prognosis, h-ATTR is a life-threatening condition with a mean survival of 10 years, mainly related to dysautonomia, cardiac involvement, cachexia, infections or bedsores complications (2). As treatments slowing the progression of the disease are now available (3–5), early diagnosis of h-ATTR is critical. Diagnosis of h-ATTR is based on symptomatic organ involvement as a progressive neuropathy; a pathogenic *TTR* mutation, and classically a pathological confirmation of amyloidosis.

The classical initial clinical presentation of h-ATTR was described by Corinho Andrade in 1952 in a population from the north of Portugal (6): a peripheral neuropathy starting and predominating distally in the lower limbs, involving first peripheral small fibers (loss of heat pain discrimination, dysautonomia) and then spreading to the entire peripheral nervous system and to other organs such as the eyes or the heart, associated with positive family history and the histopathological presence of multiple organ amyloid deposits. More recently, varied electro-clinical phenotypes of h-ATTR neuropathies have been described (7), such as axonal or demyelinating polyneuropathy, small or large fiber polyneuropathy, length-dependent or non-length-dependent polyneuropathy, or symmetric or asymmetric large-fiber neuropathy (8). It has been described that h-ATTR may mimic classical length-dependent polyneuropathy (9), chronic inflammatory demyelinating polyradiculoneuropathy (CIDP), mononeuritis multiplex (10), or even motor neuronopathy (11). Moreover h-ATTR cases may appear to be sporadic, because of de novo mutations, incomplete penetrance, unspecific symptoms, early parental loss or false paternity (8). Finally, the pathological confirmation of amyloidosis can be difficult to obtain and require repeated biopsies over multiple sites (minor salivary gland, abdominal wall fat pad or nerve). For all these reasons, the diagnosis of h-ATTR can be challenging.

As the diagnosis can be challenging because of varied presentations but needs to be early, physicians must recognize electro-clinical features raising the hypothesis of h-ATTR in a patient consulting for a polyneuropathy of undetermined origin. As there can be phenotypical differences between patients of different geographic origins (12), descriptions of patients from different regions can be useful. Our objective was to review the initial electro-clinical presentation of h-ATTR patients from northern France who consulted at first for a polyneuropathy of undetermined origin.

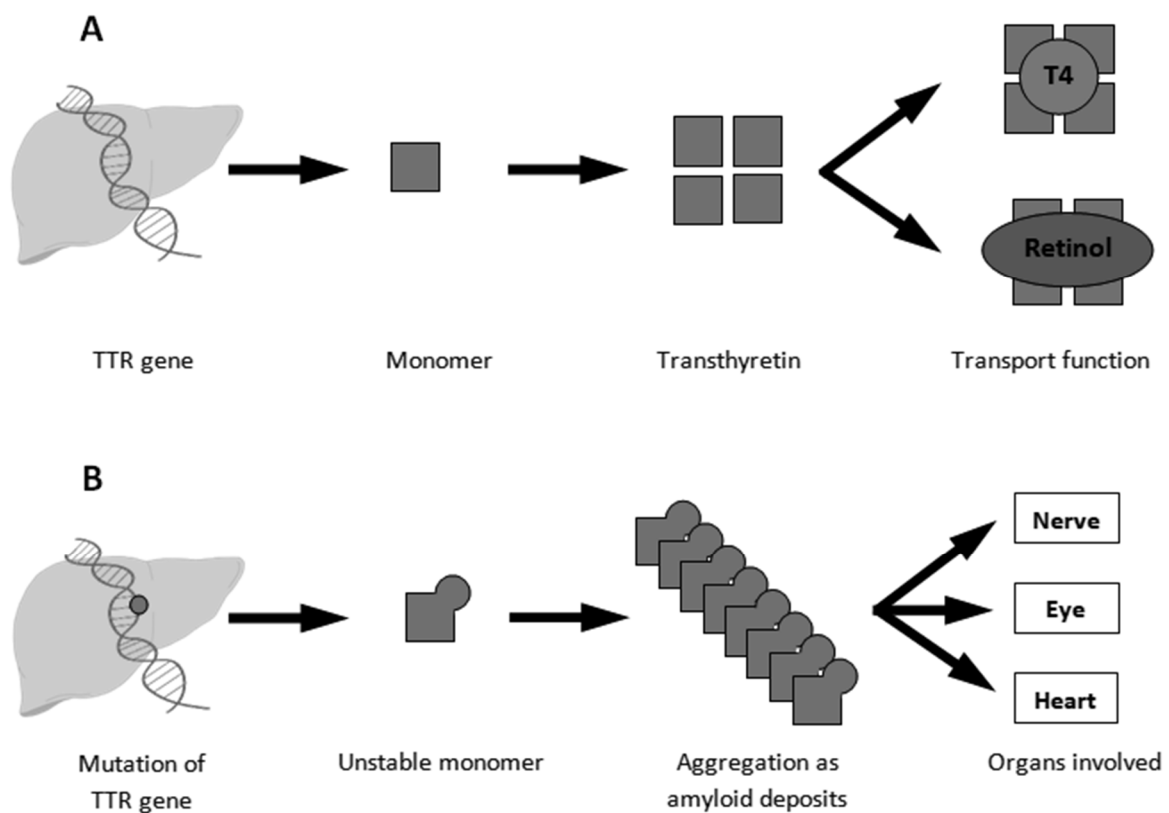


Figure 1: A. In healthy subjects, the *TTR* gene encodes for monomers which self-assemble to form transthyretin, a primary transport protein for thyroxin (T4) and retinol. B. In hereditary transthyretin related amyloidosis, a mutation of the *TTR* gene produces unstable monomers which aggregate to form amyloid deposits in several organs, leading to clinical signs.

Methods

We searched the CeMaRa database (French database for rare disease) for h-ATTR adult patients followed in the neuromuscular reference centers of two university hospitals of northern France (Amiens and Lille) between 1996 and 2019. We then reviewed the medical records of those who were referred to our center to investigate a polyneuropathy of unknown origin before being diagnosed with h-ATTR. Diagnosis of h-ATTR was made by experts, based on the presence of a pathological TTR mutation, a compatible clinical presentation, and eventual pathological evidence of amyloid deposits. If there was no histopathological evidence of h-ATTR, diagnosis had to be confirmed by neuromuscular experts during the follow-up based on the compatible clinical course and multi-organ involvement, without evidence of another etiology for the polyneuropathy. As our objective was to describe the electro-clinical presentations of h-ATTR patients consulting at first for a polyneuropathy of unknown origin in our region, we excluded patients referred because of known familial cases of h-ATTR, patients with pre-symptomatic diagnosis of h-ATTR or harboring exclusively extra-neurological involvement. We focused on the physical examination and neurophysiological data recorded for routine etiological assessment the year preceding the diagnosis of h-ATTR (Table 1). Our study was approved by a local ethic committee, and by the national commission for numeric data (CNIL number 1187326).

Statistical analysis

We performed a descriptive analysis, using percentages for categorical variables, and medians, quartiles, minimums and maximums for continuous variables. We used the Mann-Whitney U test to compare continuous variables, and Fisher's exact test to compare categorical variables. Statistical significance was set for p-values under 0.05.

Table 1: Data collected at the time of referral for investigation of polyneuropathy, before the diagnosis of h-ATTR (ENMG = electroneuromyography; CIDP = chronic inflammatory demyelinating polyneuropathy, EFNS/PNS = European Federation of Neurological Societies/Peripheral Nerve Society, NMC = neuromuscular center)

Clinical data	<ul style="list-style-type: none"> - Sex, age - Past medical history (including carpal tunnel syndrome, glaucoma, cardiac involvement) - Family history of neuropathy or neurological disorders. - Description of the neuropathy: <ul style="list-style-type: none"> o Age at time of the first neuropathy-related symptom , o Delay between this first symptom and the NMC consultation, o Topography, o Neuropathic pain o Signs of large nerve fiber involvement (weakness, hyporeflexia, epicritic discrimination loss, hypopallesthesia, ataxia) o Signs of small nerve fiber involvement (loss of heat pain discrimination, autonomic symptoms, especially an abnormal orthostatic hypotension test) - Weight loss (> 10% during the previous 12 months)
ENMG data	<ul style="list-style-type: none"> - First ENMG: <ul style="list-style-type: none"> o Sensory and/or motor involvement, o Axonal and/or demyelinating features according to the EFNS/PNS electrodiagnostic criteria for CIDP (13), o Asymmetry (defined as a left – right amplitude difference $\geq 50\%$ for at least one sensory or motor distal nerve without any other explanation, if distal amplitude was > 10% of the lower normal limit), o Length-dependency (defined by a more severe alterations of potential amplitudes in lower limbs compared to upper limbs, and in distal nerves compared to proximal nerves in each limb), o Abnormal spontaneous needle activities (fibrillations, positive sharp waves, fasciculations), o Evidence of nerve entrapment. o Sympathetic skin responses (interpreted as present or absent) - Second ENMG within the following 18 months (when performed)
Diagnosis work-up	<ul style="list-style-type: none"> - Pathology when performed (minor salivary gland, nerve, muscle) - Other cause of neuropathy in the patient's history or diagnosed at the NMC (including diabetes mellitus, chronic alcohol consumption, exposure to a neurotoxic drug or substance, hypothyroidism, chronic kidney failure, monoclonal gammopathy). - Reasons for the <i>TTR</i> gene sequencing - Identification of the <i>TTR</i> mutation (Sanger sequencing).
Cardiological evaluation	<ul style="list-style-type: none"> - Echocardiography and/or cardiac magnetic resonance imaging (MRI) in the 12 months following the diagnosis of h-ATTR

Results

There were 1276 patients presenting a neuropathy in the CEMARA database referred to the neuromuscular centers (NMC) of Amiens and Lille between 1996 and 2019 for a polyneuropathy of unknown origin. Among them, we identified 26 patients (2%) who were later diagnosed with h-ATTR in our centers (14 from Lille, 12 from Amiens). These patients came from 23 different families. Most of them were male (20/26, 76.9%). Val30Met mutation, which is the most frequent worldwide, was detected in ten (38.5%) patients, and Ser77Tyr mutation, which is the most frequent in northern France, was detected in 16 (61.5%) patients.

Clinical manifestations

Among these 26 patients, one had diabetes mellitus and five had chronic alcoholism, and these six patients were at first mistakenly diagnosed with alcoholic or diabetic neuropathy, but later investigations or expert evaluation confirmed that neuropathy was mainly related to h-ATTR. Before referral, the suspected diagnosis was CIDP in four patients, amyotrophic lateral sclerosis in one, paraneoplastic neuropathy in one, and lumbar spinal stenosis in one, all having been finally ruled out. No patient had had monoclonal gammopathy. Some patients had a history possibly evocative of h-ATTR: 10 had a history of carpal tunnel syndrome (38.5%), and six known cardiac involvement (23.1%): ischemic cardiomyopathy in two patients, hypertrophic cardiomyopathy with heart failure in three, and atrioventricular nodal reentrant tachycardia in one. No personal history of glaucoma was reported. A suspicious family history was found in 14/26 cases (54.0%): peripheral neuropathy in nine, and gait disorder in five. One patient had Portuguese origins, and two others Polish origins.

Table 2 shows the clinical characteristics of the peripheral neuropathy. The only significant clinical differences observed between Val30Met and Ser77Tyr carriers were an older age at onset and a more frequent ataxia and loss of heat pain discrimination in Val30Met patients.

Table 2: Clinical characteristics of neuropathy in the 26 patients with h-ATTR. Quantitative variables are expressed as median \pm interquartile (minimum - maximum) and qualitative variables as proportions.

Characteristic	All patients (n = 26)	Val30Met (n = 10)	Ser77Tyr (n = 16)	p-value
Age at first symptom and time to consultation				
Age at first symptom (years)	61.0 \pm 8.5 (39.0 - 81.0)	67.5 \pm 9.0 (61.0 - 81.0)	58.5 \pm 9.7 (39.0 - 80.0)	0.002*
Delay between onset and evaluation (months)	31.0 \pm 31.5 (3.0 - 187.0)	24.0 \pm 22.7 (5.0 - 53.0)	31.0 \pm 40.0 (3.0 - 187.0)	0.544
Topography				
Lower limbs only	3 / 26 (11.5 %)	0 / 10 (0.0 %)	3 / 16 (18.8 %)	0.347
Lower then upper limbs	9 / 26 (34.6 %)	5 / 10 (50.0 %)	4 / 16 (25.0 %)	
Upper limbs only	0 / 26 (0.0 %)	0 / 10 (0.0 %)	0 / 16 (0.0 %)	
Upper then lower limbs	6 / 26 (23.1 %)	3 / 10 (30.0 %)	3 / 16 (18.8 %)	
Four limbs simultaneously	8 / 26 (30.8 %)	2 / 10 (20.0 %)	6 / 16 (37.5 %)	
Large and small fiber involvement				
Pain	18 / 26 (69.2 %)	6 / 10 (60.0 %)	12 / 16 (75.0 %)	0.664
Large fiber involvement				
Weakness	21 / 26 (80.8 %)	9 / 10 (90.0 %)	12 / 16 (75.0 %)	0.627
Hyporeflexia	23 / 24 (95.8 %)	10 / 10 (100.0 %)	13 / 14 (92.9 %)	1.000
Epicritic discrimination loss	20 / 26 (76.9 %)	9 / 10 (90.0 %)	11 / 16 (68.8 %)	0.352
Hypopallesthesia	17 / 21 (81.0 %)	8 / 8 (100.0 %)	9 / 13 (69.2 %)	0.131
Ataxia	13 / 26 (50.0 %)	9 / 10 (90.0 %)	4 / 16 (25.0 %)	0.004*
Small fiber involvement				
Loss of heat pain discrimination	13 / 19 (68.4 %)	8 / 8 (100.0 %)	5 / 11 (45.5 %)	0.018*
At least one dysautonomia symptom	16 / 26 (61.5 %)	6 / 10 (60.0 %)	10 / 16 (62.5 %)	1.000
Proven orthostatic hypotension	8 / 14 (57.1 %)	3 / 5 (60.0 %)	5 / 9 (55.6 %)	1.000
Vasomotor dysfunction	3 / 16 (18.8 %)	2 / 6 (33.3 %)	1 / 10 (10.0 %)	0.528
Erectile dysfunction	5 / 12 (41.7 %)	0 / 4 (0.0 %)	5 / 8 (62.5 %)	0.081
Urinary complain	4 / 16 (25.0 %)	2 / 6 (33.3 %)	2 / 10 (20.0 %)	0.604
Digestive complain	8 / 16 (50.0 %)	4 / 6 (66.7 %)	4 / 10 (40.0 %)	0.618
Extra-neurological symptoms				
Weight loss	10 / 25 (40.0 %)	4 / 10 (40.0 %)	6 / 15 (40.0 %)	1.000

* Significant differences between the two genotypes ($p < 0.05$)

Neurophysiology

Complete initial electroneuromyography (ENMG) data were available for 25 of the 26 patients (96.2%), and are reported in Table 3. Data were incomplete for one patient who was therefore not included in this analysis.

Only one patient (Ser77Tyr), who presented with typical small-fiber neuropathy (pain, heat pain hypoesthesia, no signs of large-fiber involvement including all muscle stretch reflexes present) had a completely normal ENMG but laser evoked potentials showed absent potential. One Ser77Tyr patient displayed a pure sensory, axonal, symmetric non-length-dependent neuropathy, without clinical or ENMG motor involvement which led to the initial diagnosis of sensory neuronopathy. The other 23 patients had a sensorimotor polyneuropathy, considered as length-dependent in 11 cases (47.8%) and non-length dependent in 12 cases (52.2%), symmetric in 15 cases (65.2%) and asymmetric in eight cases (34.8%). Axonal involvement was observed in all patients. Based on the EFNS/PNS electrodiagnostic criteria for CIDP, signs of demyelination were found in at least one nerve in 17 patients (70.8%) (Table 4). Demyelination signs in the distal (distal CMAP duration increase) or intermediate (reduction of conduction velocity) segments of the nerves were more frequent than proximal demyelination signs (such as prolongation of F-wave latency or absence of F-wave). Partial motor conduction blocks ($\geq 50\%$ amplitude reduction) were less frequent than milder conduction abnormalities (abnormal temporal dispersion, $\geq 30\%$ amplitude reduction). The electrodiagnostic criteria of “definite CIDP” were fulfilled in nine patients (37.5%), and “possible CIDP” in eight patients (33.3%). Four patients received intravenous immunoglobulin therapy in the hypothesis of a CIDP before the diagnosis of h-ATTR. Abnormal spontaneous needle activities were observed in 16 / 25 patients (64.0%), mostly in distal lower limb muscles (tibialis anterior, extensor hallucis longus). Evidence for nerve entrapment were found in 17 of the 25 patients (68.0%): carpal tunnel syndrome in 16 / 25 patients (64.0%), cubital tunnel syndrome in 4 / 15 patients (26.7%); none had a common peroneal nerve entrapment. Three patients had both cubital tunnel and carpal tunnel syndromes. No significant ENMG differences between Val30Met and

Ser77Tyr carriers were observed, but Val30Met carriers trended to exhibit asymmetric involvement more frequently than Ser77Tyr carriers.

Sympathetic skin responses were investigated in 14 patients and were absent in seven (50.0%). Among them, four complained of autonomic symptoms (57.1%) but none had a positive test for orthostatic arterial hypotension. Among the seven patients with normal sympathetic skin responses, four complained of autonomic dysfunction (57.1%), but only two of them had a positive test for orthostatic arterial hypotension (29.0%).

Follow-up ENMG studies performed within 18 months (mean delay 11.8 months) of diagnosis were available in only nine patients but showed an almost systematic decrease of the amplitudes of sensory and motor nerves (Fig. 2).

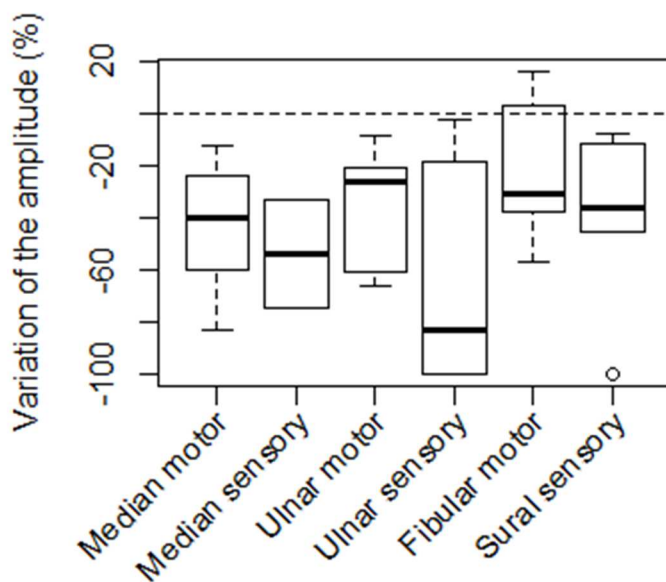


Figure 2: Variation of compound muscle action potential and sensory nerve action potential amplitudes in 9 patients between the first and the second ENMG (percentage).

Table 3: ENMG characteristics.

Characteristic	All patients (n = 24)	Val30Met (n = 10)	Ser77Tyr (n = 14)	p-value
Asymmetric	8 / 24 (33.3 %)	6 / 10 (60.0 %)	2 / 14 (14.3 %)	0.032*
Non-length dependent	13 / 24 (54.2 %)	5 / 10 (50.0 %)	8 / 14 (57.1 %)	1.000
Demyelination signs	17 / 24 (70.8 %)	8 / 10 (80.0 %)	9 / 14 (64.3 %)	0.653

Characteristic	All patients (n = 24)	Val30Met (n = 10)	Ser77Tyr (n = 14)	p-value
Definite CIDP criteria fulfilled	9 / 24 (37.5 %)	5 / 10 (50.0 %)	4 / 14 (28.6 %)	0.403
Possible CIDP criteria fulfilled	8 / 24 (33.3 %)	3 / 10 (30.0 %)	5 / 14 (35.7 %)	1.000
Abnormal spontaneous activities	16 / 24 (66.7 %)	6 / 10 (60.0 %)	10 / 14 (71.4 %)	0.673
At least one nerve entrapment	6 / 10 (60 %)	11 / 14 (78.6 %)	17 / 24 (70.8 %)	0.393

* Significant differences between the two genotypes ($p < 0.05$)

Table 4: Demyelinating features according to the ENFS/PNS electrodiagnostic criteria for chronic inflammatory demyelinating polyradiculoneuropathy (when present). The number indicates the number of nerves with a demyelinating feature for a given subject.

Subject	1	2	3	4	5	6	7	8	9	10	11	12	13	14	15	16	17
ENFS/PNS electrodiagnostic criteria	Definite									Possible							
Distal latency prolongation	0	1	0	0	0	0	2	0	0	0	0	0	0	0	0	0	0
Reduction of conduction velocity	1	1	1	0	1	0	1	0	0	0	0	0	1	0	0	0	0
Prolongation of F-wave latency	0	0	1	0	0	1	0	0	0	0	0	0	0	0	0	0	0
Absence of F-wave	0	0	0	0	0	1	0	0	0	0	0	0	0	0	0	0	0
Partial motor conduction block (≥50% amplitude reduction)	0	0	1	1	0	0	0	1	0	0	0	0	0	0	0	0	0
Abnormal temporal dispersion	1	1	1	1	0	0	0	3	1	0	0	0	0	0	0	0	0
Distal CMAP duration increase	3	1	3	0	3	3	0	1	2	1	1	4	0	1	1	4	1
No partial motor conduction block but ≥30% amplitude reduction	0	0	1	0	0	1	1	2	1	0	0	0	0	0	0	0	0

Diagnosis work-up

Minor salivary gland biopsy (MSGB) was performed in 21 patients and showed amyloid deposits in 11 (52.4%). Combined nerve and muscle biopsy (sensitive superficial fibular nerve/peroneus brevis muscle) was performed in five patients: three had signs of chronic denervation without amyloid deposits, one had signs of axonal and demyelinating neuropathy (axon loss, thinning of myelin, no fiber teasing performed) associated with amyloid deposits,

and one had an unremarkable nerve pathology but amyloid deposition in a concomitant muscle biopsy. No patient had fat pad biopsy. Overall, 17 patients had a pathological confirmation of amyloidosis (65%) at the diagnosis of h-TTR neuropathy.

The recorded reasons why *TTR* gene was sequenced in our 26 patients were as follows: demonstration of amyloid deposits on a first MSGB (n=10, 38.5%), positive family history of neuropathy (n=7, 26.9%), presence of amyloid deposits on repeated MSGB after a first normal biopsy (n=3, 11.5%), on muscle biopsy (n=2, 7.7%) or on nerve biopsy (n=1, 3.8%), and coexistence of unexplained cardiomyopathy (n=2, 7.7%) or severe dysautonomia associated with neuropathy (n=1, 3.8%). The mean delay between symptoms onset and positive diagnosis of h-ATTR was 3.9 years, ranging from seven months to 15 years.

Among the 20 patients without a known cardiomyopathy before diagnosis, 17 had a cardiological evaluation in the following year (echocardiography and eventually cardiac MRI). Radiological signs of cardiac amyloidosis (interatrial septum thickening and/or signal intensity changes) were found in 11 patients (64.7%), although they did not complain of cardiac symptoms. Cardiac MRI was not performed in the six patients with normal echocardiography so that we cannot formally exclude an amyloid cardiomyopathy in these patients.

Discussion

Our results confirm that the electro-clinical presentation of peripheral neuropathies related to h-ATTR can be quite varied. A family history suggestive of h-ATTR was present in only approximately half of the patients and symptoms were sometimes nonspecific (described as “gait disorders”). There was a male predominance in our population, as in other studies (14). Large-fiber impairment was as frequent or even sometimes more frequent than small-fiber involvement, with one patient presenting even as a sensory neuronopathy (ganglionopathy), which is unusual. In our series, clinical and electrophysiological features were mostly similar between Val30Met and Ser77Tyr carriers, but patients with the Ser77Tyr mutation tended to have a younger age at onset, less pronounced ENMG asymmetry, and suffered less frequently from ataxia and loss of heat pain discrimination in comparison with Val30Met patients.

As previously described (8), most of our patients displayed some demyelinating features according to the EFNS/PNS electrodiagnostic criteria for CIDP, mimicking CIDP. Indeed, more than one-third and one-third of them respectively fulfilled the electrodiagnostic of “definite” or “possible” CIDP. This observation emphasizes that h-ATTR has to be considered as a differential diagnosis of CIDP (particularly when the response to immune treatment is poor), and also illustrates the low specificity of the EFNS/PNS electrodiagnostic criteria for CIDP.

In our cohort, evidence of active denervation such as abnormal spontaneous activities and/or reduction in the amplitudes of sensory nerve and/or muscle action potentials during the follow-up, were identified as ENMG clues that may raise suspicion for h-ATTR.

We also observed dissociation between the presence of autonomic symptoms or proven orthostatic hypotension and the preservation of sympathetic skin responses. This highlights the poor sensitivity of sympathetic skin responses and the importance of including the exploration of small fibers to confirm their involvement, as suggested previously (15).

These descriptions highlight the many faces of h-ATTR neuropathy, which represented approximately 2% of the patients referred to our department for a polyneuropathy of unknown origin, thus a non-negligible proportion of patients who can benefit from a specific treatment.

Amyloid deposition is a major diagnostic clue to h-ATTR. In this retrospective study, only half of patients had salivary amyloid deposition, in keeping with previous reports (8). Amyloid deposits were found on histopathological examination in only one of the five patients who underwent a nerve biopsy. Interestingly, amyloid deposits were only identified in muscle but not in nerve sections in a single patient who had both nerve and muscle biopsies, confirming the interest of a systematic muscle biopsy concomitantly to the nerve biopsy if possible. A tenosynovial biopsy may also be considered in patients undergoing carpal tunnel release (16).

Because this disease is characterized by multiple organ deposits of amyloidogenic TTR protein, the heart as well as other organs may be involved. In our series as in others (8), asymptomatic cardiac involvement was found in approximately two-thirds of sporadic patients event at the diagnosis of h-ATTR, but we cannot exclude that the presence of amyloid cardiomyopathy has been underestimated given that cardiac evaluation was limited to echocardiography in some patients. The h-ATTR neuropathy diagnosis therefore led to an early diagnosis, management and follow-up of the cardiomyopathy in most of our cases.

The strength of our study is to provide feedback from our experience in a single region (northern France), with a high proportion of Ser77Tyr patients, with mostly non-related patients, and give precise ENMG data that may be lacking in previous studies. There are limitations to acknowledge including that our study was retrospective, without systematic ENMG evaluation, with a small sample size, there is a potential selection bias in patients referred to specialized centers, and some missing data may limit more detailed analysis. Finally some patients had no pathological evidence of amyloidosis, whereas many authors consider that amyloidosis remains a pathological diagnosis (17). Nevertheless, the diagnosis of h-ATTR was not invalidated for any of these patients during several years of follow-up by neuromuscular experts.

Conclusion

Altogether, our data on the various electro-clinical presentations of polyneuropathy, the non-systematic presence of familial history or of extra-neurological involvement, and the potential difficulty to demonstrate pathological amyloid deposits on MSGB suggest that h-ATTR can be evoked for most of the polyneuropathies of unknown etiology, especially with few demyelinating abnormalities, active denervation, clear reduction of amplitude in follow up or non-length-dependent ENMG abnormalities. Moreover, in adult patients, some conditions such as diabetes mellitus or chronic alcoholism may induce a polyneuropathy indistinguishable from h-ATTR and therefore lead to misdiagnosis or delayed diagnosis. We thus believe that *TTR* gene sequencing should have a place in the second-line evaluation of patients presenting a polyneuropathy of unknown origin, or when the evolution of an alcoholic or diabetic polyneuropathy is more severe than expected, as this would enable early genetic counselling and early introduction of specific treatment. Two ongoing multicentric French studies (ADDITION (18), PRE-TRANS (19)) investigating h-ATTR screening in idiopathic polyneuropathies should determine whether this strategy could help and determine clinical or neurophysiological criteria arguing for *TTR* gene sequencing.

Abbreviations

CIDP: Chronic inflammatory demyelinating polyradiculoneuropathies

EFNS/PNS = European Federation of Neurological Societies/Peripheral Nerve Society

ENMG: Electroneuromyography

h-ATTR: Hereditary transthyretin related amyloidosis

MRI: Magnetic resonance imaging

MSGB: Minor salivary gland biopsy

NMC: Neuromuscular centers

TTR: Transthyretin gene

Acknowledgements

We acknowledge Frederic London, MD, for English Language editing.

Disclosures

Jean-Baptiste Davion has received travel grants from Alnylam. Eric Hachulla has received consultant fees from AKCEA Therapeutics. Céline Tard has received consultant fees from AKCEA Therapeutics, Sanofi-Genzyme, Pfizer, Alnylam, Ultragenyx, and was investigator for studies promoted by Pharnext, Alnylam, Sanofi-Genzyme, Amicus. The remaining authors have no conflicts of interest.

References

1. Saraiva MJ, Birken S, Costa PP, Goodman DS. Amyloid fibril protein in familial amyloidotic polyneuropathy, Portuguese type. Definition of molecular abnormality in transthyretin (prealbumin). *J Clin Invest.* 1984 Jul;74(1):104–19.
2. Ando Y, Coelho T, Berk JL, Cruz MW, Ericzon B-G, Ikeda S, et al. Guideline of transthyretin-related hereditary amyloidosis for clinicians. *Orphanet J Rare Dis.* 2013 Feb 20;8:31.
3. Coelho T, Maia LF, Martins da Silva A, Waddington Cruz M, Planté-Bordeneuve V, Lozeron P, et al. Tafamidis for transthyretin familial amyloid polyneuropathy: a randomized, controlled trial. *Neurology.* 2012 Aug 21;79(8):785–92.
4. Benson MD, Waddington-Cruz M, Berk JL, Polydefkis M, Dyck PJ, Wang AK, et al. Inotersen Treatment for Patients with Hereditary Transthyretin Amyloidosis. *N Engl J Med.* 2018 Jul 5;379(1):22–31.
5. Adams D, Gonzalez-Duarte A, O’Riordan WD, Yang C-C, Ueda M, Kristen AV, et al. Patisiran, an RNAi Therapeutic, for Hereditary Transthyretin Amyloidosis. *N Engl J Med.* 2018 05;379(1):11–21.
6. Andrade C. A peculiar form of peripheral neuropathy; familiar atypical generalized amyloidosis with special involvement of the peripheral nerves. *Brain.* 1952 Sep;75(3):408–27.
7. Ikeda S. Is familial amyloid polyneuropathy rare? DNA testing is changing the concept of this disease. *Neurology.* 2007 Aug 14;69(7):627–8.
8. Planté-Bordeneuve V, Ferreira A, Lalu T, Zaros C, Lacroix C, Adams D, et al. Diagnostic pitfalls in sporadic transthyretin familial amyloid polyneuropathy (TTR-FAP). *Neurology.* 2007 Aug 14;69(7):693–8.
9. Luigetti M, Conte A, Del Grande A, Bisogni G, Madia F, Lo Monaco M, et al. TTR-related amyloid neuropathy: clinical, electrophysiological and pathological findings in 15 unrelated patients. *Neurol Sci.* 2013 Jul;34(7):1057–63.
10. Shirota Y, Iwata A, Ishiura H, Hashimoto M, Goto J, Shimizu J, et al. A case of atypical amyloid polyneuropathy with predominant upper-limb involvement with the diagnosis unexpectedly found at lung operation. *Intern Med.* 2010;49(15):1627–31.
11. Lozeron P, Lacroix C, Theaudin M, Richer A, Gugenheim M, Adams D, et al. An amyotrophic lateral sclerosis-like syndrome revealing an amyloid polyneuropathy associated with a novel transthyretin mutation. *Amyloid.* 2013 Sep;20(3):188–92.
12. Planté-Bordeneuve V, Carayol J, Ferreira A, Adams D, Clerget-Darpoux F, Misrahi M, et al. Genetic study of transthyretin amyloid neuropathies: carrier risks among French and Portuguese families. *J Med Genet.* 2003 Nov;40(11):e120.
13. Van den Bergh PYK, Hadden RDM, Bouche P, Cornblath DR, Hahn A, Illa I, et al. European Federation of Neurological Societies/Peripheral Nerve Society guideline on management of chronic inflammatory demyelinating polyradiculoneuropathy: report of a joint task force of the European Federation of Neurological Societies and the Peripheral Nerve Society - first revision. *Eur J Neurol.* 2010 Mar;17(3):356–63.

14. Rapezzi C, Riva L, Quarta CC, Perugini E, Salvi F, Longhi S, et al. Gender-related risk of myocardial involvement in systemic amyloidosis. *Amyloid*. 2008 Mar;15(1):40–8.
15. Lefaucheur J-P, Wahab A, Planté-Bordeneuve V, Sène D, Ménard-Lefaucheur I, Rouie D, et al. Diagnosis of small fiber neuropathy: A comparative study of five neurophysiological tests. *Neurophysiol Clin*. 2015 Dec;45(6):445–55.
16. Sperry BW, Reyes BA, Ikram A, Donnelly JP, Phelan D, Jaber WA, et al. Tenosynovial and Cardiac Amyloidosis in Patients Undergoing Carpal Tunnel Release. *Journal of the American College of Cardiology*. 2018 Oct 23;72(17):2040–50.
17. Kapoor M, Rossor AM, Laura M, Reilly MM. Clinical Presentation, Diagnosis and Treatment of TTR Amyloidosis. *J Neuromuscul Dis*. 6(2):189–99.
18. Early Diagnosis of TTR Amyloidosis by Use of Molecular Biology - ClinicalTrials.gov [Internet]. [cited 2019 Dec 14]. Available from: <https://clinicaltrials.gov/ct2/show/NCT03373370>
19. Assessment of the Prevalence of TTR Amyloid Neuropathy in a Population of Patients With Neuropathy of Unknown Aetiology - ClinicalTrials.gov [Internet]. [cited 2019 Dec 14]. Available from: <https://clinicaltrials.gov/ct2/show/NCT03190577>