



HAL
open science

Treatment of Eosinophilic Annular Erythema: Retrospective multicenter study and literature review.

M. Chastagner, J. Shourik, M. Jachiet, M. Battistella, Guillaume Lefevre,
Jean-Baptiste Gibier, H. Aubert, M. Musquer, V. Descamps, L. Deschamps,
et al.

► To cite this version:

M. Chastagner, J. Shourik, M. Jachiet, M. Battistella, Guillaume Lefevre, et al.. Treatment of Eosinophilic Annular Erythema: Retrospective multicenter study and literature review.. Annales de Dermatologie et de Vénérologie, 2021, Annales de Dermatologie et de Vénérologie, 10.1016/j.annder.2021.07.007 . hal-04483268

HAL Id: hal-04483268

<https://hal.univ-lille.fr/hal-04483268>

Submitted on 22 Jul 2024

HAL is a multi-disciplinary open access archive for the deposit and dissemination of scientific research documents, whether they are published or not. The documents may come from teaching and research institutions in France or abroad, or from public or private research centers.

L'archive ouverte pluridisciplinaire **HAL**, est destinée au dépôt et à la diffusion de documents scientifiques de niveau recherche, publiés ou non, émanant des établissements d'enseignement et de recherche français ou étrangers, des laboratoires publics ou privés.



Distributed under a Creative Commons Attribution - NonCommercial 4.0 International License

ANNDER-D-21-00060

Original article

Treatment of Eosinophilic Annular Erythema: retrospective multicenter study and literature review

M. Chastagner¹⁺⁺, J. Shourik²⁺⁺, M. Jachiet³, M. Battistella⁴, G. Lefevre^{5,6}, J.-B. Gibier⁷, H. Aubert⁸, M. Musquer⁹, V. Descamps¹⁰, L. Deschamps¹¹, O. Chosidow¹², N. Ortonne¹³, M. Groh^{5,14}, M. Bernier¹⁵, D. Jullien¹, F. Chasset², D. Staumont-Salle¹⁶, J.-D. Bouaziz³, J. Kanikatis¹⁺⁺, A.P. Villani^{1*++}

++: equal contributors

¹ Department of Dermatology, CHU Lyon, Université Claude Bernard Lyon I, 69000 Lyon, France

² Sorbonne université, Faculté de médecine, Service de Dermatologie et Allergologie, Hôpital Tenon, AP-HP, 75020 Paris, France

³ Department of Dermatology, Hôpital Saint-Louis, AP-HP Université de Paris, 75010 Paris, France

⁴ Pathology Department, Hôpital Saint-Louis, AP-HP, Université de Paris, INSERM U976, 75010 Paris, France

⁵ CEREO (National reference center for Hypereosinophilic Syndromes), 75010 Paris, France

⁶ Department of Internal Medicine, CHU Lille, 59000 Lille, France

⁷ Pathology Department, CHU Lille, 59000 Lille, France

⁸ Dermatology Department, CHU Nantes, 44000 Nantes, France

⁹ Pathology Department, CHU, 44000 Nantes, France

¹⁰ Dermatology Department, Hôpital Bichat, 75018 Paris, France

¹¹ Pathology Department, Hôpital Bichat, 75018 Paris, France

¹² Faculté de Santé de Créteil et Service de Dermatologie, APHP, Hôpital Henri-Mondor, Université Paris-Est, Créteil, France and Research Group Dynamic, EA7380, Faculté de Santé de Créteil, Ecole Nationale Vétérinaire d'Alfort, USC ANSES, Université Paris-Est Créteil, 94010 Créteil, France

¹³ Pathology Department, Hôpital Mondor, CHU Créteil, 94010 Créteil, France

¹⁴ Department of Internal Medicine, Hôpital Foch, 92150 Suresnes, France

¹⁵ Pathology Department, Hôpital Foch, 92150 Suresnes, France

¹⁶ Department of Dermatology, CHU Lille, Inserm U1286 INFINITE (Institute for Translational Research in Inflammation), Univ. Lille, F-59000 Lille, France

*** Corresponding author**

E-mail: axel.villani@chu-lyon.fr (Axel P Villani)

Hôpital Edouard Herriot – Service de Dermatologie – Pavillon R, 5 place d'Arsonval, 69003 Lyon, France

Abstract

Background: Eosinophilic annular erythema (EAE) is a rare eosinophil-related skin disease which typically manifests with annular erythematous plaques and severe pruritus. Besides the diagnosis, the treatment of EAE is challenging since relevant published data are sparse.

Methods: The aim of this study was to assess the underlying diseases, treatments and outcomes of patients with EAE. To this end, we conducted a retrospective multicenter study and a systematic review of the MEDLINE database.

Results: We included 18 patients with EAE followed in 8 centers. The MEDLINE database search yielded 37 relevant publications reporting 55 cases of EAE with 106 treatment sequences. The most common and efficient treatments included topical or systemic corticosteroids, hydroxychloroquine and dapsone. In refractory patients, a combination of systemic corticosteroids with hydroxychloroquine was associated with 88% of complete clinical response.

Discussion: To improve the management of EAE patients, we discuss the following treatment strategy: in topical steroid-resistant patients, hydroxychloroquine can be given as first-line systemic treatment. Dapsone, hydroxychloroquine or systemic corticosteroids are second-line options to consider. Last, monoclonal antibodies or JAK inhibitors targeting type 2 inflammation could represent promising last-resort options in refractory patients.

Keywords: eosinophilic annular erythema; eosinophil; Wells syndrome; eosinophilic cellulitis; Treatment

1. Introduction

Eosinophilic annular erythema (EAE) is a rare eosinophil-related skin disease that typically manifests with annular erythematous plaques with central pigmentation and severe pruritus [1]. The disease is characterized by dermal infiltration of eosinophils and, in some cases, blood eosinophilia [1, 2]. Due to shared histologic features, EAE might be a subtype of eosinophilic cellulitis (EC/Wells syndrome) with a more superficial inflammatory infiltrate [3]. Flame figures, which are characteristic of EC, are missing in acute lesions and are only observed in well-developed and long-standing lesions of EAE [2-4]. Whether EAE is a superficial form of EC or a separate entity is unknown. Yet, their inherent clinical manifestations (nodules/plaques in EC *versus* figurate/annular lesions in EAE) significantly differ. The pathogenesis of EAE is not fully understood, but the current hypothesis favors interleukin (IL)-5-mediated recruitment of eosinophils to the skin in response to an unknown epidermal trigger, such as an allergic stimulus or insect bites [1]. Since relevant published data are sparse and consist mostly of case reports or small case series, the treatment of EAE can be challenging, with various treatment strategies being reported.

The aim of this study was to assess the underlying diseases, treatments and outcomes of patients with EAE in order to better define a treatment strategy for this rare disease. To this end, we conducted a retrospective multicenter observational study and a review of the MEDLINE database.

2. Patients and methods

2.1. Patients from the retrospective multicenter study:

We performed a French nationwide observational retrospective multicenter study. EAE cases were retrieved from 8 centers using the pathology database codes ADICAP 'OT0411', associated with eosinophilic cellulitis, and 'OT7550', associated with eosinophilic inflammation. Each patient's medical record was then analyzed to ensure that the diagnosis of EAE had been confirmed by a dermatologist, based on typical annular plaques and consistent histology (Fig. 1a,b), as described elsewhere (perivascular and interstitial eosinophilic infiltrate of the superficial dermis without flame figures in early-stage lesions and with flame figures in late-stage lesions) [1]. Cases with predominantly non-annular presentation were excluded. One author (JS) reviewed all eligible cases and recorded the following parameters for each confirmed case of EAE: age, gender, pruritus, course and duration of the disease, comorbidities. Treatment data were also assessed: dosage, duration, outcome (complete response/CR - partial response/PR - no response or worsening/NR), relapse during and after treatment. This study was conducted in compliance with the Helsinki declaration (as revised in 2008) and French MR004 legislation and was approved by the local Ethics Committee of the Foch Hospital (approval number HJ-2018-05).

2.2. Literature review

Two investigators (MC and AV) independently searched for published studies indexed in the MEDLINE database up to December 2020, using the search chain '*eosinophilic annular erythema*'. All the articles reporting case reports and case series with a diagnosis of EAE, based on typical annular plaques and consistent histology, were selected and analyzed. Cases not clearly identified as EAE were excluded from analysis. Treatment outcomes were

classified as CR, PR and NR, based on the same definitions used previously. If the outcome was not clearly reported by the authors, the case was excluded from analysis.

3. Results

3.1. Multicenter retrospective study:

From 1994 to 2019, 18 patients fulfilling the inclusion criteria were recorded for 8 centers: 10 women and 8 men with a mean age of 59 years (median=63 years). Sixteen of 18 patients (89%) reported pruritus. Five of the 11 EAE patients aged over 60 years (46%) had an underlying disease at the time of diagnosis. A hematologic malignancy was found in 4/11 patients (36%), including *polycythemia vera* (n=2) and B-cell lymphoma (n=2). One patient presented EAE concomitantly with a breast carcinoma. Two of the 7 EAE patients aged under 60 years (29%) had an underlying disease, including systemic lupus erythematosus (n=1) and eosinophilic granulomatosis with polyangiitis (EGPA, formerly Churg-Strauss syndrome) (n=1). Eleven of the 18 patients (61%) had no underlying disease at the time of EAE diagnosis.

Among our 18 patients, we assessed 27 treatment sequences. The median treatment duration was 16 months (range: 2-48 months). First-line treatment consisted of either topical (8/18 patients, 44%) or systemic (2/18 patients, 11%) corticosteroids, dapsone (2/18 patients, 11%), combined chloroquine and systemic corticosteroids (n=1), and a combination of cancer therapy and corticosteroids (2/18 patients, 11%). Second-line treatments included dapsone (3/18 patients, 17%), hydroxychloroquine (2/18 patients, 11%), and cancer therapy associated with systemic corticosteroids (n=1).

Topical corticosteroids enabled PR and CR in 3/8 (38%) and 4/8 (50%) patients, respectively (a single patient failed to respond). Among the 7 patients with either PR or CR, only 2 (29%) did not relapse after treatment discontinuation. Likewise, PR (n=1, with relapse after

discontinuation) and CR (n=1, without subsequent relapse, in a patient otherwise diagnosed with EGPA) were reported with systemic corticosteroids (1 mg/kg/day). Patients treated with hydroxychloroquine (200-400 mg/day) achieved CR (without relapse) in 1/3 patient and PR in 1/3 patient. The third (elderly) patient died under treatment of multiple comorbidities (aged over 85 years, type II diabetes, arterial hypertension). Patients treated with dapsone (100 mg/day) achieved CR (with no relapse after discontinuation) in 2/5 (40%) patients, PR (with relapse after discontinuation) in 2/5 (40%) patients and no response in one patient.

Relapse and NR were observed in 6/8 (75%) patients treated with topical corticosteroids, 2/3 (66%) treated with corticosteroids, and 3/5 (60%) treated with dapsone. Hydroxychloroquine alone was given to only one patient, who relapsed after complete response.

In patients with associated hematologic malignancies, CR of EAE was obtained in 3/4 patients (75%) following the use of cancer therapy combined with systemic or topical corticosteroids. Patients with B-cell lymphoma were treated respectively with bendamustine, rituximab and topical corticosteroids and vincristine, rituximab and corticosteroids, achieving CR in both cases. One patient with *polycythemia vera* was treated with systemic corticosteroids and hydroxyurea (CR). One *polycythemia vera* patient was not treated and was lost to follow-up.

Anecdotally, methotrexate, baricitinib and thalidomide were used in one case each. Relapse-free CR was obtained using baricitinib and thalidomide in our cohort.

Finally, spontaneous improvement was also reported in 3/18 (17%) patients (but the time to improvement was not reported).

3.2. Review of the MEDLINE database

The MEDLINE database search yielded 48 potentially relevant publications between 1978 and 2020. Eight publications were excluded after reading of the title and abstract because they

did not report EAE cases. Eight publications were excluded because treatment outcome was not clearly reported. We analyzed 32 publications reporting 55 cases of EAE with 106 treatment sequences, for which outcomes were clearly reported (Table S1; see supplementary material available on line) [1,2, 5-34]. Combined results from our cohort and the data extracted from the systematic literature review are summarized in Figure 2 (limited to treatments with at least 2 sequences).

Associated disorders consisted mainly of malignancies (8/73 patients, 11%), including hematologic disorders, breast cancer, metastatic prostate carcinoma and thymoma and autoimmune diseases (8/73 patients, 11%), including EGPA, systemic lupus erythematosus, autoimmune pancreatitis, autoimmune hepatitis, Hashimoto disease and rheumatoid arthritis.

Overall, PR or CR were achieved with 18/21 (86%) treatment sequences using topical corticosteroids (clobetasol or betamethasone for 2 weeks to 6 months), 9/14 (64%) using antimalarial drugs (chloroquine 250 mg/day, hydroxychloroquine 200-400 mg/day for 3-9 weeks), 19/29 (66%) using systemic corticosteroids (prednisone ~1 mg/kg/day for 2-8 weeks), and 9/13 (69%) using dapsone (50-100 mg/day for 3-8 weeks). Among these responding patients, CR was obtained in 61% of treatment sequences using topical corticosteroids, 57% using antimalarial drugs, 46% using dapsone and 41% using systemic corticosteroids.

Mepolizumab and dupilumab were reported as being effective in a few cases (n=3) [11, 25,34]. Spontaneous improvement was observed in 8 cases [1, 21,28,31]. A combination of anti-malarial drugs with systemic corticosteroids was given to 8 patients (7 from the literature and 1 from our cohort) and resulted in CR in 7/8 patients (88%) [2, 22,27].

4. Discussion

To better define treatment strategies in EAE, we report here in the treatment outcomes for 18 new cases along with a thorough analysis of previously published cases. Given the low

prevalence of EAE, our analysis revealed strong heterogeneity regarding the prescribed treatments involving over 20 different strategies when combining results from our cohort and the MEDLINE database. Overall, topical corticosteroids, systemic corticosteroids and, at a lesser degree, dapson and anti-malarial drugs, were the most commonly reported treatments. Topical and systemic corticosteroids were associated with high rates of partial response and relapse. Though used in fewer patients, dapson and antimalarial drugs seemed to result in better therapeutic responses. Hydroxychloroquine was efficient in our cohort as in previous studies but its discontinuation was followed by clinical relapse in our study (n=1), contrary to previously reported cases [2,5,8,14,16,18,23]. This may be explained by a shorter follow-up time in the previous studies. Regarding dapson, the majority of patients achieved CR or PR with no serious adverse events. In previously published cases, dapson also resulted in CR in antimalarial-resistant EAE patients [9,26,33].

Combination treatments were rarely prescribed to patients in our cohort and did not prove better compared with monotherapy. However, in a few cases the combination of anti-malarial drugs with systemic corticosteroids was reported to be highly effective, with complete improvement in 88% of cases; this combination could thus be of value in refractory patients [2,22,27].

We also report 4 patients above the age of 60 years who developed EAE associated with hematologic malignancies. In most of these patients, CR of EAE was obtained with treatment of the hematologic disorder. These observations suggest that some cases of EAE are paraneoplastic, as claimed in previous case reports [10,15]. Nevertheless, given the low prevalence of this disease and its potential association with malignancies/hematologic disorders, EAE patients could benefit from cancer screening.

Our study has several limitations inherent to its retrospective design, including missing data, and the impossibility of clearly assessing relapse and heterogeneity of patient management

over time and within centers. Also, it remains debated whether EAE and EC represent genuinely distinct entities or rather form a continuum of the same disease. Both belong to the spectrum of eosinophilic dermatoses, which encompass diseases of different etiologies with no validated classification and treatment. Indeed, the clinical manifestations are extremely heterogeneous, including nodules, plaques, pustules, blisters and urticarial lesions; the shared feature is an eosinophilic infiltration of the skin. Despite different clinical manifestations between EC (nodules, plaques) and EAE (figurate/annular lesions), some authors believe that they represent the same entity, essentially because of overlapping histologic features [2, 3]. Of note, our results suggest a favorable course using antimalarial drugs in more than 60% of EAE patients, whereas such treatment is not reported as efficient in EC [35]. In the light of our results, the following treatments may be considered in EAE: since spontaneous improvement can be observed, the first-line strategy should not be very aggressive. In patients without pruritus, therapeutic abstention is an option. Otherwise, topical corticosteroids (betamethasone or clobetasol for 4-8 weeks) appear to be a reasonable first-line option, given their safety and the high rates of CR and PR achieved. In patients resistant to topical corticosteroids, anti-malarial drugs (namely hydroxychloroquine 200-400 mg/day for 2-3 months) seems a well-balanced option, as it achieves high rates of clinical responses and has a good safety profile. In patients resistant to both topical corticosteroids and hydroxychloroquine, dapsone (50-100 mg/day for 2-3 months) or hydroxychloroquine combined with systemic corticosteroids are interesting third-line options (200-400 mg/day and 0.5-1 mg/kg/day respectively for 2-3 months); the choice between these two strategies will mostly depend on the associated comorbidities. Finally, in refractory patients, thalidomide, UVB phototherapy and type 2-targeted therapies, such as mepolizumab (an IL-5 inhibitor), dupilumab (an IL-4Ra inhibitor), or baricitinib (a JAK1/2 inhibitor), could be last-resort options as they were reported as being effective in at least one patient each.

References

1. Nakazato S, Fujita Y, Shinkuma S, Nomura T, Shimizu H. Eosinophilic annular erythema is clinically characterized by central pigmentation reflecting basal melanosis: a clinicopathological study of 10 cases. *J Eur Acad Dermatol Venereol* 2017;31:1916-23.
2. El-Khalawany M, Al-Mutairi N, Sultan M, Shaaban D. Eosinophilic annular erythema is a peculiar subtype in the spectrum of Wells syndrome: a multicentre long-term follow-up study. *J Eur Acad Dermatol Venereol* 2013;27:973-9.
3. Rongioletti F, Fausti V, Kempf W, Rebora A, Parodi A. Eosinophilic annular erythema: an expression of the clinical and pathological polymorphism of Wells syndrome. *J Am Acad Dermatol* 2011;65:e135-e7.
4. Leiferman KM, Peters MS. Eosinophil-Related Disease and the Skin. *J Allergy Clin Immunol Pract* 2018;6:1462-82 e6.
5. Abarzua A, Giesen L, Silva S, Gonzalez S. Eosinophilic annular erythema in childhood - Case report. *An Bras Dermatol* 2016;91:503-5.
6. Alharbi R, Peric J, Wolff H, Wollenberg A. Dapsone treatment for eosinophilic annular erythema. *J Eur Acad Dermatol Venereol* 2017;31:e153-e4.
7. Awosika O, Totoraitis K, Eleryan M, Rengifo-Pardo M, Ehrlich A. A case of eosinophilic annular erythema as a presenting sign for autoimmune hepatitis. *JAAD Case Rep* 2018;4:84-6.
8. Dereure O, Guilhou JJ. [Eosinophilic-like erythema: a clinical subset of Wells' eosinophilic cellulitis responding to antimalarial drugs?]. *Ann Dermatol Venereol* 2002;129:720-3.
9. Fania L, Provini A, Rota L, Mazzanti C, F RI, Panebianco A, et al. Eosinophilic annular erythema: Report of four cases. *Dermatol Ther* 2020;33:e14369.

10. Gonzalez-Lopez MA, Lopez-Escobar M, Fernandez-Llaca H, Gonzalez-Vela MC, Lopez-Brea M. Eosinophilic annular erythema in a patient with metastatic prostate adenocarcinoma. *Int J Dermatol* 2015;54:e80-2.
11. Gordon SC, Robinson SN, Abudu M, Her M, Deverapalli S, Levin A, et al. Eosinophilic annular erythema treated with dupilumab. *Pediatr Dermatol* 2018;35:e255-e6.
12. Heras MO, Munoz NP, Sancho MI, Millet PU. Eosinophilic annular erythema in adults: report of two cases and review of the literature. *An Bras Dermatol* 2017;92:S65-8.
13. Hioki T, Takama H, Makita S, Shibata A, Akiyama M, Watanabe D. Eosinophilic annular erythema localized on the neck. *Eur J Dermatol* 2017;27:673-4.
14. Howes R, Girgis L, Kossard S. Eosinophilic annular erythema: a subset of Wells' syndrome or a distinct entity? *Australas J Dermatol* 2008;49:159-63.
15. Iga N, Otsuka A, Kaku Y, Miyachi Y, Kabashima K. Eosinophilic annular erythema limited on the palms and the soles and possibly associated with thymoma. *J Eur Acad Dermatol Venereol* 2016;30:1213-4.
16. Kahofer P, Grabmaier E, Aberer E. Treatment of eosinophilic annular erythema with chloroquine. *Acta Derm Venereol* 2000;80:70-1.
17. Kanameishi S, Goto K, Ogawa M, Fukumoto T, Tanabe H. Efficacy of suplatast tosilate in a case of recurrent eosinophilic annular erythema. *Int J Dermatol* 2018;57:e66-e8.
18. Karatas Togrul A, Seckin D. Eosinophilic annular erythema: A late but complete response to hydroxychloroquine. *Australas J Dermatol* 2017;58:228-30.
19. Kato K, Namiki T, Tokoro S, Takayama K, Yokozeki H. Bullous eosinophilic annular erythema. *J Dermatol* 2017;44:e42-e3.
20. Kim YS, Song YM, Seo HM, Bang CH, Lee JH, Lee JY, et al. Eosinophilic Annular Erythema Associated with Churg-Strauss Syndrome. *Ann Dermatol* 2017;29:813-4.

21. Kunz M, Hamm K, Brocker EB, Hamm H. [Annular erythema in childhood--a new eosinophilic dermatosis]. *Hautarzt* 1998;49:131-4.
22. Lee HS, Yang JY, Kim YC. Eosinophilic Annular Erythema Localized to the Palms and the Soles. *Ann Dermatol* 2016;28:769-71.
23. Ljubojevic Hadzavdic S, Bartolic L, Bradamante M. Prolonged Treatment of Eosinophilic Erythema Annulare with Chloroquine. *Acta Dermatovenerol Croat* 2018;26:262-3.
24. Lobo MA, Gonzalo ES, Jimenez-Reyes J. Eritema anular eosinofilico en un adulto Eosinophilic annular erythema in an adult. *Dermatol Online J.* 2017;23: 13030/qt22c95125
25. Maione V, Caravello S, Cozzi C, Venturini M, Incardona P, Frassi M, et al. Refractory eosinophilic annular erythema treated successfully with dupilumab. *J Dtsch Dermatol Ges.* 2020;18(9):1031-2.
26. Manriquez J, Berroeta-Mauriziano D, Andino-Navarrete R, Vera-Kellet C. Eosinophilic annular erythema: complete clinical response with dapsona. *Int J Dermatol* 2015;54:e96-8.
27. Mebazaa A, Kenani N, Ghariani N, Denguezli M, Sriha B, Belajouza C, et al. Eosinophilic annular erythema responsive to chloroquin. *Eur J Dermatol* 2009;19:84-5.
28. Neuberger A, Enk A, Toberer F. Atypical presentation of eosinophilic annular erythema in a 5-year-old girl. *J Eur Acad Dermatol Venereol* 2018;32:e220-e1.
29. Ogawa K, Fukumoto T, Yoshida M, Matsumoto Y, Shobatake C, Asada H. Eosinophilic annular erythema in a patient with autoimmune pancreatitis: Nicotinamide therapy may be beneficial for achieving remission. *J Dermatol* 2016;43:1380-1.
30. Paulitschke V, Tittes J, Tanew A, Radakovic S. [Eosinophilic annular erythema in a 20-month-old girl]. *Hautarzt* 2021;72:332-6.

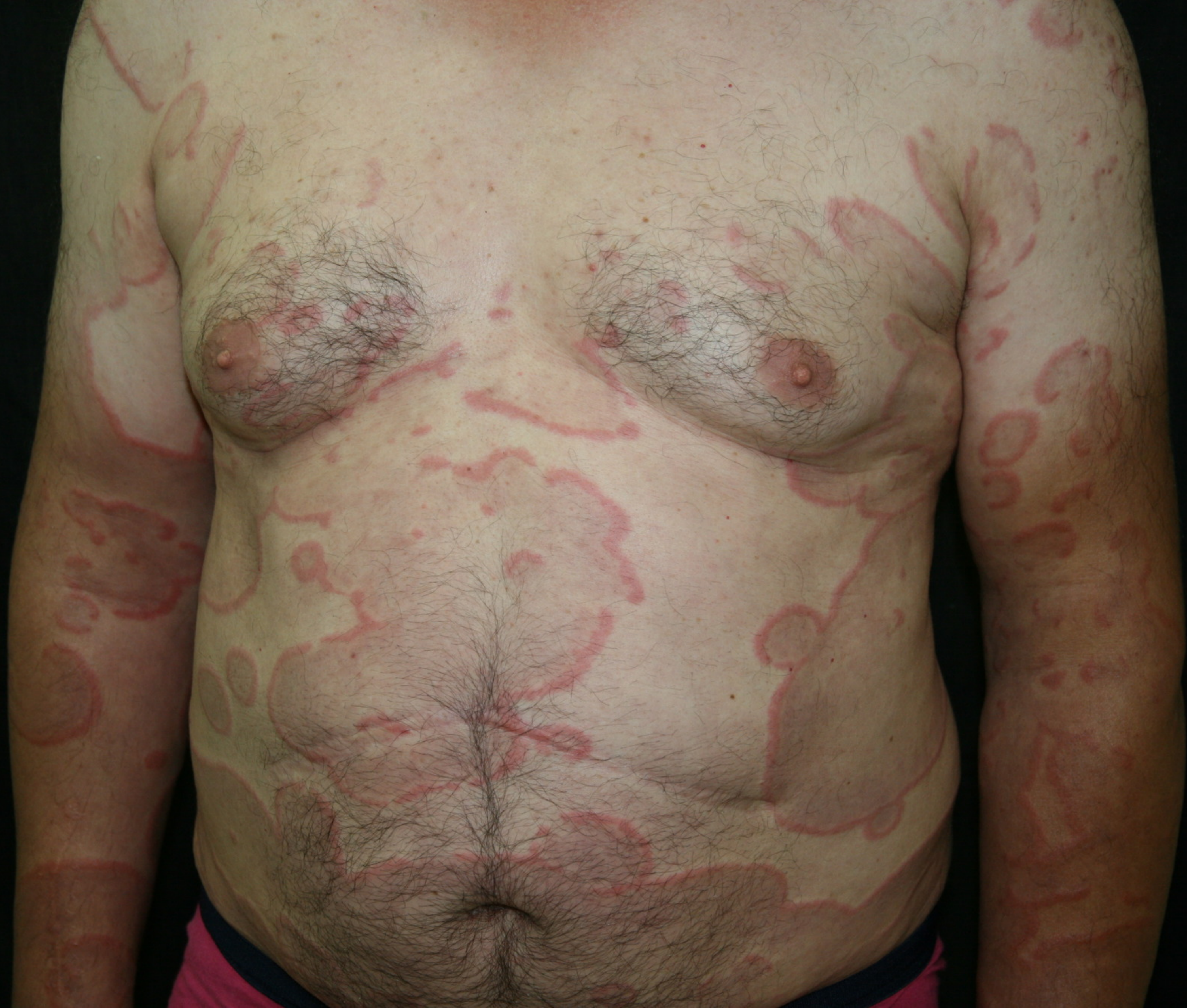31. Prajapati V, Cheung-Lee M, Schloss E, Salopek TG. Spontaneously resolving eosinophilic annular erythema. *J Am Acad Dermatol* 2012;67:e75-7.
32. Thomas L, Fatah S, Nagarajan S, Natarajan S. Eosinophilic annular erythema: successful response to ultraviolet B therapy. *Clin Exp Dermatol* 2015;40:883-6.
33. Wallis L, Gilson RC, Gilson RT. Dapsone for recalcitrant eosinophilic annular erythema: a case report and literature review. *Dermatol Ther (Heidelb)* 2018;8:157-63.
34. Zychowska M, Tutka K, Reich A. Mepolizumab therapy for recalcitrant eosinophilic annular erythema in an adult: a case report and review of treatment options. *Dermatol Ther (Heidelb)* 2020;10:893-9.
35. Ressler F, Lukacs J, Elsner P. Treatment of eosinophilic cellulitis (Wells syndrome) - a systematic review. *J Eur Acad Dermatol Venereol* 2016;30:1465-79.

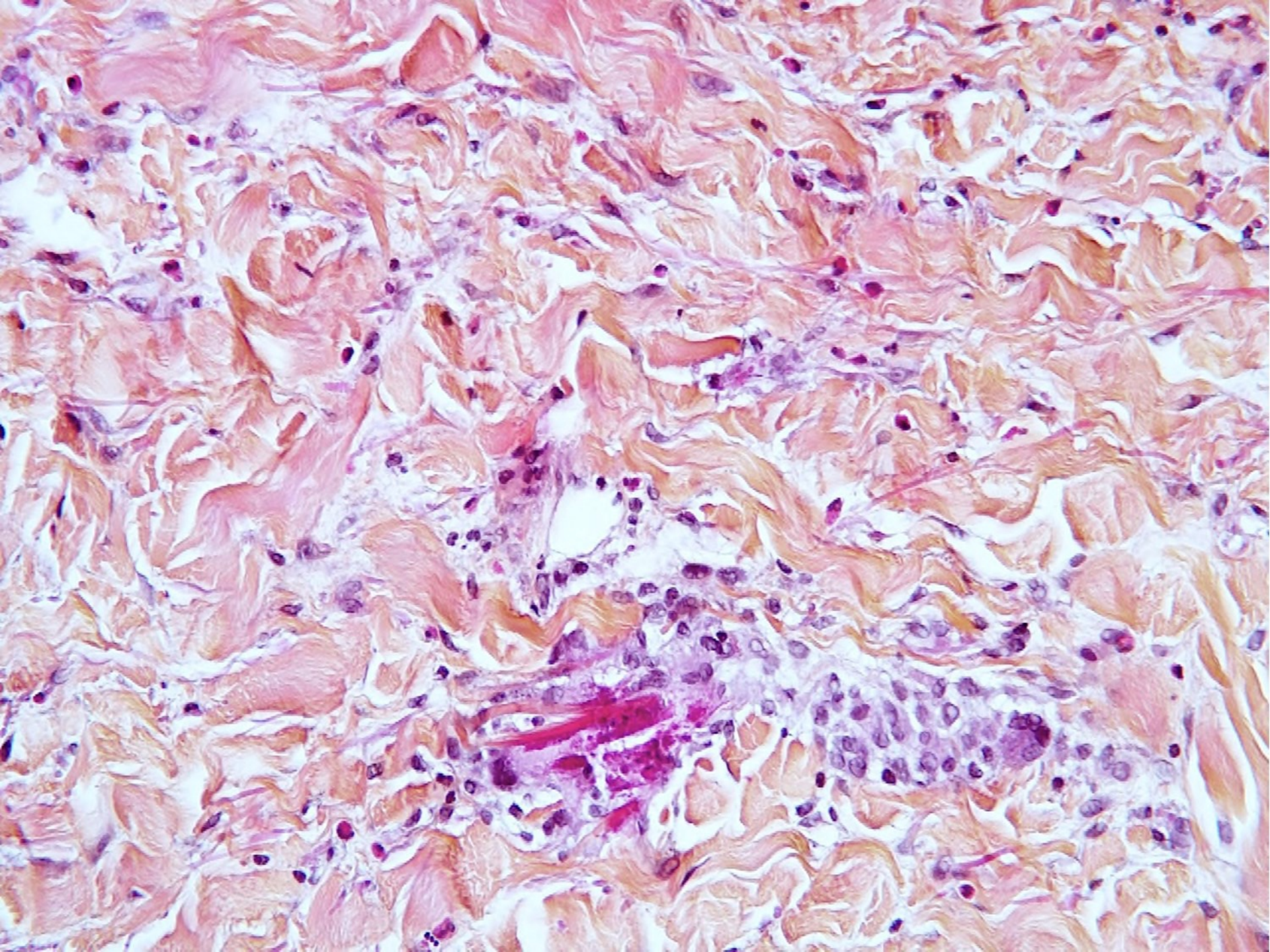
Figure 1: (a) Eosinophilic annular erythema: typical annular lesions with a pigmented center.

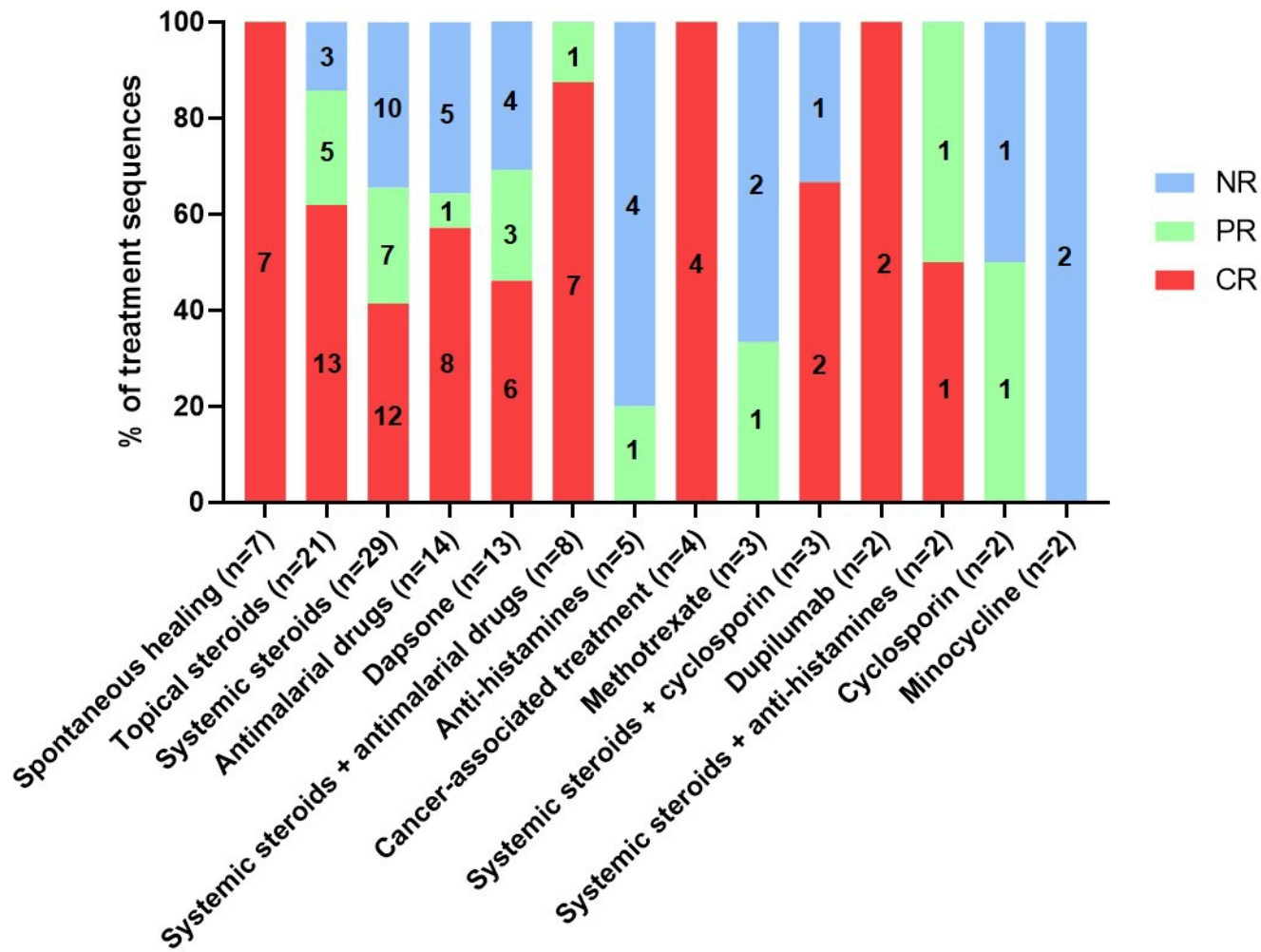
(b) Histopathological features of late-stage eosinophilic annular erythema: interstitial and perivascular eosinophilic dermal infiltrate (original magnification x250;

* simple flame figure)

Figure 2: Treatment outcomes in patients with EAE for the 18 patients of our case series and the for 55 patients extracted from the literature review. Outcomes are classified as CR (complete response), PR (partial response) and NR (no response or worsening).







Patient No	Treatment No	Sex, Age	Associated comorbidities	Therapeutic	Clinical response Relapse	Posology	Reference
1	1	M, 73	Churg and Strauss disease	Systemic steroids	CR, no	10 mg/kg/day then progressive discontinuation	20
2	1	F, 14		Topical steroids	NR	NA	11
2	2	F, 14		Systemic steroids	NR	NA	11
2	3	F, 14		Dapsone	NR	NA	11
2	4	F, 14		Tofacitinib	NR	NA	11
2	5	F, 14		Dupilumab	CR, no	600 mg then 300 mg every 2 weeks	11
3	1	M, 74		Topical steroids	CR, yes	Clobetasol	12
4	1	M, 75		Systemic steroids	CR, yes	NA	12
4	2	M, 75		Topical steroids	CR, no	Clobetasol	12
5	1	M, 72		Systemic steroids	NR	0.25 mg/kg/day	13
6	1	F, 69		Systemic steroids	CR, no	1 mg/kg/day	19
7	1	M, 60		Systemic steroids + Cyclosporine	NR	NA	22
8	1	M, 52		Topical steroids + Cyclosporine	PR, yes	NA	22
8	2	M, 52		Systemic steroids + Hydroxychloroquine	CR, no	Hydroxychloroquine (400 mg/day)	22
9	1	M, 38		Systemic steroids	NR	NA	33
9	2	M, 38		Hydroxychloroquine	PR, yes	200 mg/day	33
9	3	M, 38		Cyclosporine	PR, yes	NA	33
9	4	M, 38		Dapsone	CR, no	NA	33
10	1	F, 5		Topical Pimecrolimus + Antihistamines	PR, yes	NA	28
10	2	F, 5		Systemic steroids	PR, yes	30 mg/day	28
10	3	F, 5		Spontaneous healing			28
11	1	F, 69		Hydroxychloroquine	CR, no	400 mg/day	18
12	1	F, 3		Systemic steroids + Antihistamines	PR, yes	1 mg/kg/day	5

12	2	F, 3		Hydroxychloroquine	CR, no	50 mg/day	5
13	1	F, 29		Systemic steroids	NR	NA	26
13	2	F, 29		Hydroxychloroquine	NR	NA	26
13	3	F, 29		Dapsone	CR, no	25 mg/day	26
14	1	M, 27		Topical steroids	CR, yes	NA	1
15	1	F, 42	Cervical cancer, Rheumatoid arthritis	Topical steroids	CR, yes	NA	1
16	1	F, 68	Rheumatoid arthritis	Topical steroids	CR, no	NA	1
17	1	M, 47		Topical steroids	CR, yes	NA	1
18	1	F, 54	Breast cancer	Topical steroids	CR, no	NA	1
19	1	M, 31		Systemic steroids	CR, yes	40 mg/day	1
20	1	M, 82		Systemic steroids	CR, no	20 mg/day	1
21	1	F, 31		Spontaneous healing			1
22	1	F, 66		Systemic steroids	CR, no	20 mg/day	1
23	1	F, 32	EGPA	Systemic steroids	CR, no	30 mg/day	1
24	1	M, 22	Autoimmune hepatitis	Hydroxychloroquine	NR	400 mg/day	7
24	2	M, 22	Autoimmune hepatitis	Methotrexate	PR, yes	10 mg/week	7
24	3	M, 22	Autoimmune hepatitis	Topical steroids + Mycophenolate mofetil	PR, yes	1 g/day	7
24	4	M, 22	Autoimmune hepatitis	Systemic steroids	CR, no	60 mg/day	7
25	1	M, 20		Topical steroids	PR, yes	NA	17
25	2	M, 20		Sutaplast tosilate	CR, no	NA	17
26	1	M, 8		Topical steroids	NR	Clobetasol	32
26	2	M, 8		Systemic steroids	PR, yes	15 mg/day	32
26	3	M, 8		Hydroxychloroquine	NR	100 mg/day	32
26	4	M, 8		UVB phototherapy	CR, no	NA	32

27	1	M, 65	Autoimmune pancreatitis	Topical steroids	CR, yes	Betamethasone	29
27	2	M, 65	Autoimmune pancreatitis	Systemic steroids	PR, yes	NA	29
27	3	M, 65	Autoimmune pancreatitis	Minocycline	NR	NA	29
27	4	M, 65	Autoimmune pancreatitis	Nicotinamide	CR, no	900 mg/day	29
28	1	M, 60	Metastatic prostate cancer	Systemic steroids + topical steroids	PR, yes	20 mg/day + clobetasol	10
29	1	M, 72	Thymoma	Thymectomy	CR, no	NA	15
30	1	F, 65		Systemic steroids	NR	40 mg/day	34
30	2	F, 65		Hydroxychloroquine	NR	400 mg/day	34
30	3	F, 65		Dapsone	NR	100 mg/day	34
30	4	F, 65		Mepolizumab	CR, no	100 mg/month	34
31	1	M, 40		Systemic steroids	CR, yes	NA	2
32	1	F, 34		Systemic steroids	CR, yes	NA	2
33	1	F, 37		Systemic steroids + hydroxychloroquine	CR, yes	NA	2
34	1	F, 22		Systemic steroids + Cyclosporine	CR, yes	NA	2
35	1	F, 31		Systemic steroids + hydroxychloroquine	CR, yes	NA	2
36	1	M, 42		Systemic steroids + hydroxychloroquine	CR, yes	NA	2
37	1	F, 38		Systemic steroids	CR, yes	NA	2
38	1	F, 51		Systemic steroids + hydroxychloroquine	CR, yes	NA	2
39	1	M, 46		Systemic steroids + Cyclosporine	CR, yes	NA	2
40	1	F, 39		Systemic steroids + hydroxychloroquine	CR, yes	NA	2
41	1	M, 59		Systemic steroids	PR, yes	40 mg/day	23
41	2	M, 59		Chloroquine	CR, no	250 mg/day	23
42	1	F, 30		Systemic steroids	PR, yes	0.5 mg/kg/day	27

42	2	F, 30	Systemic steroids + chloroquine	CR, no	4 mg/kg/day	27
43	1	F, 24	Topical steroids	CR, yes	Clobetasol	24
44	1	F, 52	Systemic steroids	NR	10 mg/day	14
44	2	F, 52	Loratadine	NR	NA	14
44	3	F, 52	Azathioprine	NR	50 mg/day	14
44	4	F, 52	Indomethacin	CR, yes	NA	14
44	5	F, 52	Sulfasalazine	NR	NA	14
44	6	F, 52	Methotrexate	NR	10 mg/week	14
44	7	F, 52	Cyclosporine	NR	25 mg/day	14
44	8	F, 52	NSAID	NR	NA	14
44	9	F, 52	Leflunomide	NR	NA	14
44	10	F, 52	Hydroxychloroquine	CR, no	200-400 mg/day	14
45	1	F, 60	Systemic steroids	PR, yes	0.7 mg/kg/day	6
45	2	F, 60	Dapsone	CR, no	100 mg/day	6
46	1	F, 62	Topical steroids	PR, yes	NA	16
46	2	F, 62	Dapsone	PR, yes	NA	16
46	3	F, 62	Chloroquine	CR, no	250 mg/day	16
47	1	F, 74	Spontaneous healing			31
48	1	F, 35	Hydroxychloroquine	CR, no	NA	8
49	1	M, 4	Spontaneous healing			21
50	1	M, 0	Antihistamines	PR, no	NA	30
51	1	F, 75	Systemic steroids	NR	NA	9
51	2	F, 75	Antihistamines	NR	NA	9
51	3	F, 75	Dapsone	NR	NA	9
51	4	F, 75	Minocycline	NR	NA	9
52	1	F, 57	Systemic steroids	NR	NA	9
52	2	F, 57	Antihistamines	NR	NA	9

52	3	F, 57		Hydroxychloroquine	CR	400 mg/day	9
53	1	F, 52	Hashimoto's disease	Systemic steroids + Antihistamines	CR	40 mg/day + 10 mg/day	9
54	1	F, 60		Systemic steroids	NR	NA	9
54	2	F, 60		Antihistamines	NR	NA	9
54	3	F, 60		Hydroxychloroquine	NR	NA	9
54	4	F, 60		Dapsone	CR	100 mg/day	9
55	1	F, 56		Systemic steroids + Indomethacin	CR, yes	50 mg/day + 50 mg/day	25
55	2	F, 56		Systemic steroids + Dapsone	NR	50 mg/day + 50 mg/day	25
55	3	F, 56		Dupilumab	CR	600 mg then 300 mg every 2 weeks	25