



**HAL**  
open science

## **Interaction between sphingosine kinase/sphingosine 1 phosphate and transforming growth factor- $\beta$ /Smads pathways in experimental intestinal fibrosis. An in vivo immunohistochemical study.**

Roberta Sferra, Simona Pompili, Luca Ventura, Caroline Dubuquoy, Silvia Specca, Eugenio Gaudio, Giovanni Latella, Antonella Vetuschi

### ► To cite this version:

Roberta Sferra, Simona Pompili, Luca Ventura, Caroline Dubuquoy, Silvia Specca, et al.. Interaction between sphingosine kinase/sphingosine 1 phosphate and transforming growth factor- $\beta$ /Smads pathways in experimental intestinal fibrosis. An in vivo immunohistochemical study.. European Journal of Histochemistry, 2018, European Journal of Histochemistry, 62, 10.4081/ejh.2018.2956 . hal-04490158

**HAL Id: hal-04490158**

**<https://hal.univ-lille.fr/hal-04490158v1>**

Submitted on 22 Mar 2024

**HAL** is a multi-disciplinary open access archive for the deposit and dissemination of scientific research documents, whether they are published or not. The documents may come from teaching and research institutions in France or abroad, or from public or private research centers.

L'archive ouverte pluridisciplinaire **HAL**, est destinée au dépôt et à la diffusion de documents scientifiques de niveau recherche, publiés ou non, émanant des établissements d'enseignement et de recherche français ou étrangers, des laboratoires publics ou privés.



Distributed under a Creative Commons Attribution - NonCommercial 4.0 International License

# Interaction between sphingosine kinase/sphingosine 1 phosphate and transforming growth factor- $\beta$ /Smads pathways in experimental intestinal fibrosis. An *in vivo* immunohistochemical study

Roberta Sferra,<sup>1§</sup> Simona Pompili,<sup>1§</sup>  
Luca Ventura,<sup>2</sup> Caroline Dubuquoy,<sup>3</sup>  
Silvia Specca,<sup>4</sup> Eugenio Gaudio,<sup>5</sup>  
Giovanni Latella,<sup>6§</sup> Antonella Vetuschi<sup>1§</sup>

<sup>1</sup>Department of Biotechnological and Applied Clinical Sciences, University of L'Aquila, Italy

<sup>2</sup>Pathology Division, San Salvatore Hospital, L'Aquila, Italy

<sup>3</sup>Intestinal Biotech Development, Lille, France

<sup>4</sup>U995-LIRIC-Lille Inflammation Research International Center, University of Lille, France

<sup>5</sup>Department of Anatomical, Histological, Forensic Medicine and Orthopedic Sciences, Sapienza University of Rome, Italy

<sup>6</sup>Department of Life, Health and Environmental Sciences, Gastroenterology Unit, University of L'Aquila, Italy

<sup>§</sup>These authors contributed equally to this work

p-Smad3,  $\alpha$ -SMA, collagen I-III, SPHK1, RhoA, PI3K, Akt, p-Akt, p-mTOR. This study highlights the relationship between the two pathways and the possible role of SPHK1 in the intestinal fibrosis. These results, if confirmed by *in vitro* studies, may have important clinical implications in the development of new therapeutical approaches in inflammatory bowel disease.

## Introduction

Intestinal fibrosis is described as an uncontrolled accumulation of Extracellular Matrix (ECM) proteins and represents a common and progressive response to chronic inflammation, characterized by the rearrangement of normal tissue architecture, leading eventually to strictures, stenosis and intestinal obstruction, particularly in Crohn Disease (CD). Crucial effector cells of this process are activated myofibroblasts, derived not only from resident mesenchymal cells (fibroblasts, sub-epithelial myofibroblasts and smooth muscle cells) but also from epithelial and endothelial cells *via* a process of Epithelial-Mesenchymal Transition (EMT)/Endothelial-Mesenchymal Transition (EndoMT).<sup>1-3</sup> Several lines of evidence suggest that EMT is a crucial mechanism in the fibro-proliferative processes.<sup>4</sup>

Several biological mediators have been implicated in the activation of ECM producing cells, including cytokines, chemokines, growth factors, angiogenic factors and products of oxidative stress. Among these, Transforming Growth Factor- $\beta$  (TGF- $\beta$ ) plays a central role in sustaining and amplifying tissue remodeling and fibrosis. Previous studies have demonstrated that several anti-fibrotic molecules directly interact with the TGF- $\beta$ /Smad pathway to modulate intestinal fibrosis.<sup>5,6</sup> Although TGF- $\beta$  signaling is dependent on Smad family protein activity, other molecules, including those that regulate cytoskeletal function, have been implicated in fibrosis. Members of the Rho-GTPase family, in particular RhoA, play a fundamental role in TGF- $\beta$ -induced  $\alpha$ -Smooth Muscle Actin ( $\alpha$ -SMA) expression and EMT.<sup>7,8</sup> TGF- $\beta$  also activates the Phosphoinositide 3-Kinase (PI3K)/protein kinase B (AKT)/mammalian Target of Rapamycin (m-TOR)-dependent pathway, deregulated of which contributes to chronic fibrosis in several fibro-proliferative diseases.<sup>9</sup>

In addition, recent reports also demonstrate a connection between the TGF- $\beta$ /Smad and sphingosine 1 Phosphate (S1P) pathways in stimulating excessive ECM production in many organs.<sup>10</sup> S1P is a ceramide-derived lipid messenger of the sphingolipid family, the synthesis and stabi-

Corresponding Author: Roberta Sferra, Department of Biotechnological and Applied Clinical Sciences, Human Anatomy, University of L'Aquila, Via Vetoio, Coppito 2, 67100, L'Aquila, Italy.  
Tel.: +39.0862.433574, 433504 -  
Fax: +39.0862.433523.  
E-mail: roberta.sferra@univaq.it

Keywords: Intestinal fibrosis, epithelial to-mesenchymal transition, immunohistochemistry, TGF $\beta$ /Smads, sphingosine 1-phosphate.

Contributions: RS, study design and manuscript drafting; SP, immunohistochemical analyses and participation in the study design; LV, immunohistochemical analyses; SS, CD, experimental DSS-induced colitis and assessment of macroscopic colorectal lesions; EG, study supervision; GL, AV, study coordination, supervision and critical manuscript revision.

Conflict of interest: The Authors declare no conflict of interest.

Received for publication: 18 June 2018.

Accepted for publication: 19 July 2018.

This work is licensed under a Creative Commons Attribution-NonCommercial 4.0 International License (CC BY-NC 4.0).

©Copyright R. Sferra et al., 2018

Licensee PAGEPress, Italy

European Journal of Histochemistry 2018; 62:2956  
doi:10.4081/ejh.2018.2956

lization of which involves structural membrane components. Sphingosines are bioactive cytosolic lipids, deregulation in the synthesis and degradation of which is toxic and characterized by membrane damage or modification.<sup>11</sup>

Under normal conditions, cells control cytosolic sphingosine accumulation through the balanced action of S1P-lyase (SPL)-mediated degradation and specific S1P phosphorylate.<sup>11</sup> SPL is a crucial regulator of intracellular S1P levels and S1P phosphorylation is catalyzed by Sphingosine Kinase 1 (SPHK1) and Sphingosine Kinase 2 (SPHK2) that exhibit ubiquitous expression but differences in subcellular localization and biochemical properties.<sup>12</sup> S1P exhibits both intracellular and extracellular functions: it acts as a second messenger, interfering with intracellular pathways involved in variety of cellular processes but also binds specific S1P1, S1P2, S1P3, S1P4, S1P5 cell surface receptors, involved in cell growth, differentiation, survival, motility, inflammation and fibrosis,<sup>12,13</sup> each inducing a specific cellular response to S1P binding.<sup>14</sup>

There appear to be multiple ways

## Abstract

A concomitant action of multiple profibrotic mediators appears crucial in the development and progression of fibrosis. Sphingosine kinase/sphingosine 1 phosphate and transforming growth factor- $\beta$ /Smads pathways are both involved in pathogenesis of fibrosis in several organs by controlling differentiation of fibroblasts to myofibroblasts and the epithelial-to-mesenchymal transition. However, their direct involvement in chronic colitis-associated fibrosis it is not yet known. In this study we evaluated the immunohistochemical expression of some proteins implicated in sphingosine kinase/sphingosine 1 phosphate and transforming growth factor- $\beta$ /Smads pathways in Dextrane Sodium Sulphate (DSS)-induced colorectal fibrosis in mice. Compared to control mice, DSS-induced chronic colitis mice developed a marked intestinal fibrosis associated with a concomitant overexpression of TGF- $\beta$ ,

through which crosstalk between S1P and SPHK1 and TGF- $\beta$  signaling results in organ fibrosis.<sup>15</sup> In idiopathic pulmonary fibrosis (IPF), S1P directly stimulates airway epithelial cells by activating latent TGF- $\beta$  through Rho kinase and  $\alpha\beta6$  integrin.<sup>16</sup> TGF- $\beta$  activates SPHK1, Akt and AMPK, resulting S1P production.<sup>17</sup> Interaction between S1P/SPHK1 and TGF- $\beta$  signaling pathways induces the transition of alveolar epithelial cells into myofibroblasts resulting in the expression of fibronectin and  $\alpha$ -SMA and progression of lung fibrosis.<sup>18</sup> A link between S1P and TGF- $\beta$ -associated fibrosis has also been demonstrated in the cardiac muscle, in which TGF- $\beta$  stimulates SPHK1, inducing S1P production and activation of cardiac fibrosis *via* the S1P2 receptor.<sup>19</sup> Furthermore, the paracrine/autocrine action of S1P, produced by SPHK1 in the intracellular compartment and released into the extracellular compartment, promotes TGF- $\beta$ -induced cardiac fibroblasts to myofibroblasts trans-differentiation.<sup>20</sup> Previous reports have also associated ECM accumulation and renal fibrosis with activation of the SPHK1/S1P and TGF- $\beta$  pathways.<sup>21</sup> Furthermore, diabetic kidney and mesangial cells grown under high glucose conditions exhibit augmented expression of the S1P2 receptor, implicating the S1P-S1P2-MAPK axis in fibronectin overexpression.<sup>13</sup>

S1P receptors are also expressed by liver and stimulate hepatic stellate cells proliferation and contractility *in vitro*.<sup>22</sup> A potential role for S1P and S1P2 receptors in liver fibrosis and regeneration following carbon tetrachloride (CCl<sub>4</sub>) hepatic injury has also been reported in S1P2 knockout mice, characterized by reduced hepatic myofibroblasts numbers and proliferation in response to S1P.<sup>22</sup>

We hypothesized that the TGF- $\beta$ /Smad3 pathway, SPHK1, RhoA, PI3K, Akt, p-Akt, and p-mTOR may act as a complex signaling network, with extensive crosstalk and strong effects on intestinal fibrosis. Therefore, in this study, we evaluated the *in vivo* expression of all these molecules in a murine model of Dextran Sulphate Sodium (DSS)-induced colorectal fibrosis, and in particular the interaction between SPHK1 and TGF- $\beta$ /Smad pathways.

## Materials and Methods

The experimental colitis was carried out at the Institution of Pasteur, Animal Care Facility (Pasteur Institute de Lille, France) as per the governmental guidelines and approved by the Ethic Committee for Animal Experimentation of the region Nord-Pas de Calais-France (Comité

d'Ethique en Expérimentation Animale Nord-Pas de Calais; CEEA n.75).

### Animals

Twenty C57BL/6 wild-type mice were included in the study (Janvier, Le Genest-St-Isle, France). All animals were kept in a pathogen-free environment at constant room temperature, with 12h/12h light/darkness cycle and food and water *ad libitum*.

### Experimental design, induction and evaluation of chronic colitis

The mice were randomly divided into two groups: control (H<sub>2</sub>O) n=5 and DSS n=15. Chronic colitis and fibrosis were induced in mice by oral administration of 2.5% (w/v) DSS (MW: 36,000-44,000, purchased from TdB Consultancy, Uppsala, Sweden) solubilized in autoclaved tap water and administered *ad libitum* for three cycles (5 days DSS followed by 7 days of tap water) while control groups received only tap water. Animals were monitored daily for fluid intake, weight changes, and examined for signs of colitis such as weight loss, diarrhea (scored on a 0-2 scale, as follows: 0, absence; 1, mild; 2, severe), rectal bleeding, assessed with the ColoScreen III Lab Pack (Elitech, Salon-de-Provence, France) and rectal prolapse, (scored as 0, absence; 1, presence).

### Samples recovery and preparation

Four days after the last DSS cycle administration, the animals of each group were sacrificed through cervical dislocation after CO<sub>2</sub> anaesthesia. Following laparotomy, colon and rectum were identified and rapidly excised. On a scale from 0 to 2, the presence of adhesions between the colon-rectum and adjacent organs was assessed.<sup>23</sup> The length and the weight of colon and rectum were measured and then scored for macroscopic lesions. Then the colorectal samples were fixed in 4% buffered formaldehyde and embedded in paraffin for histological and immunohistochemical analysis.

### Macroscopic and microscopic evaluation of colonic injury

In order to score the macroscopic lesions, the colonic length and weight were measured. Macroscopic colonic lesions were scored on a 0-2 scale, as follows: colonic adhesions (0, absence; 1, mild/focal zonal; 2, severe/diffuse); colonic dilation (0, absence; 1, mild; 2, severe); colonic thickness (0, normal; 1, mild increase; 2, marked increase, >3 mm).<sup>23</sup>

The total macroscopic score was expressed as the sum of the individual scores of colonic alterations. Bowel fragments were subjected to conventional histological processing procedures, fixation in

4% buffered formalin in Phosphate Buffer Saline (PBS) (pH 7.4 for 3 h at room temperature) and paraffin embedding.

Serial 3- $\mu$ m sections were staining using Haematoxylin and Eosin (H&E), in order to highlight the degree of inflammation, and Masson's Trichrome to evaluate the deposition of connective tissue and fibrosis. The stained sections were then observed under an Olympus BX51 Light Microscope (Olympus Optical Co. Ltd., Tokyo, Japan). Two pathologists (AV and RS) independently examined and scored all histological sections of the colonic samples in double-blind, according to the presence of ulcerations (0, absent; 1, small ulcers; 2, big ulcers), degree of inflammation (0, absent; 1, mild; 2, moderate; ad 3, severe), depth of the lesions (0, absent; 1, lesions extending in the submucosa; 2, lesions in the muscularis propria; 3, lesions in the serosa) and degree of fibrosis (0, absent; 1, mild; 2, moderate; 3, severe). The sum of these scores was expressed as total microscopic score as previously reported.<sup>23</sup>

Intestinal inflammation was evaluated as absent, mild, moderate or severe according to the density and the extent of the inflammatory infiltrate, the loss of goblet cells, and the bowel wall thickening. Masson's Trichrome allowed to stage intestinal fibrosis as mild, moderate or severe, based on the density and the extent of connective tissue and disruption of tissue architecture.<sup>23</sup>

### Immunohistochemistry

Colonic samples, were also promptly fixed in 4% buffered formalin in PBS for 3 h at room temperature, dehydrated in graded ethanols and embedded in low-melting paraffin. Sections of 3- $\mu$ m in thickness were incubated for 40 min in methanol and in 3% hydrogen peroxide solution for 5 min. The specimens were incubated overnight at 4°C with specific antibodies (Table 1). The samples were washed in PBS for 5 min and incubated with streptavidin-biotin-peroxidase conjugated secondary antibody (K0675, Dako-Cytomation, Milano, Italy). After rinsed in PBS for 10 min the sections were incubated with 3,3'-diaminobenzidine-tetrahydrochloride for 1-3 min. Finally, the sections were counterstained with Mayer's Hematoxylin, mounted and observed under the Olympus BX51 Light Microscope (Olympus, Optical Co. Ltd., Tokyo, Japan).

To control the specificity of the immune reaction, negative and positive controls were performed for all immunoreactions (Table 1). For negative controls the sections were incubated omitting the primary antibody.



## Quantitative digital image analysis of immunohistochemical staining and statistical analyses

Quantitative comparison of immunohistochemical staining was measured by ImageJ, a digital image analysis public domain software (U.S. National Institutes of Health, Bethesda, MD; available at: <https://imagej.nih.gov/ij/>) for all antibody tested in the study. Five microscopic fields were selected from control and DSS groups, photographed at the same magnification and then subjected to IHC profiler software analysis. The immunopositivity was expressed as a percentage of the total software-classified areas and the data obtained were plotted as histograms. Results were expressed as means  $\pm$ SD; a P-value  $<0.05$  was considered statistically significant.

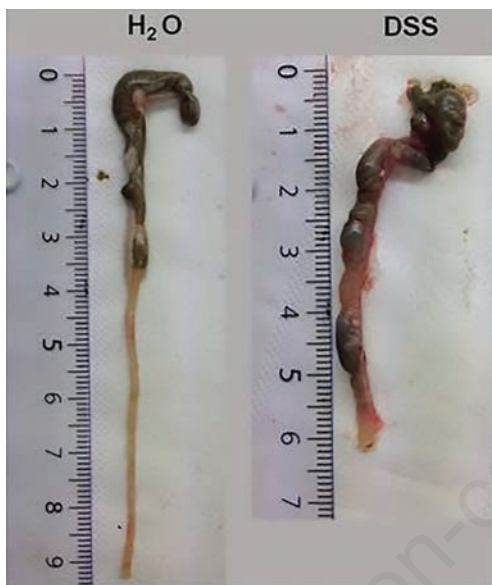

Figure 1. Macroscopic aspects of large bowel in DSS and control mice.

## Results

### Clinical and macroscopic findings of chronic colitis induced by DSS

Administration of DSS has led to a moderate body-weight loss and mortality in 13% of the animals.

The colon of DSS treated mice appeared increased in weight (referred to the last 8 cm of the distal large bowel) whereas colon length was reduced compared to control mice (Figure 1). In DSS group the ratio weight/length of the colon and the major macroscopic findings of fibrosis as dilation, thickness, stenosis and adhesion were significantly increased compared to untreated mice (Table 2).

### Microscopic features of colitis

In DSS treated mice histological evaluation assessed by H&E and Masson's Trichrome staining showed marked signs of inflammation and evidence of fibrosis (Figure 2 B,D), compared to controls (Figure 2 A,C). Mucosal and submucosal layers displayed inflammatory infiltrate and a reduction of goblet cells, associated with a marked distortion of crypt architecture and presence of erosions and ulcerations. Furthermore, a significant increase in connective tissue deposition was found in submucosa and serosa.

### Immunohistochemistry

The main fibrotic markers Collagen I-III and  $\alpha$ -SMA resulted mild expressed in

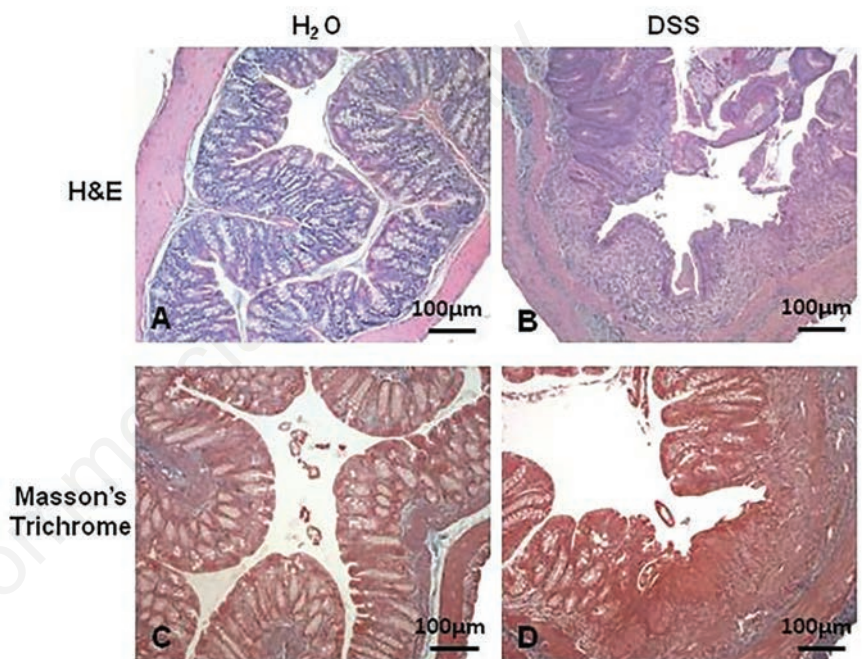


Figure 2. H&E and Masson Trichrome staining (original magnification 10x). DSS treated mice (B,D) show marked signs of inflammation (B) and several evidences of fibrosis (D) while in control specimens (A,C) a normal architecture of colonic wall is present.

Table 1. Antibodies used with their sources and dilutions together with the positive controls.

Antibodies	Sources	Dilutions	Positive controls
TGF- $\beta$	(Sc-146) Santa Cruz Biotechnology Inc., Santa Cruz, CA, USA	1:400	Intrinsic in the sample
p-Smad3	(Sc-130218) Santa Cruz Biotechnology Inc., CA, USA	1:100	Intrinsic in the sample
Smad7	(Sc-365846) Santa Cruz Biotechnology Inc., Santa Cruz, CA, USA	1:400	Intrinsic in the sample
$\alpha$ -SMA	(Sc-32251) Santa Cruz Biotechnology Inc., Santa Cruz, CA, USA	1:400	Vessel wall
Collagen I-III	(Sc-8784; sc-8781) Santa Cruz Biotechnology Inc., Santa Cruz, CA, USA	1:400	Intrinsic in the sample
SPHK1	(PA1996) BosterBio, Pleasanton, CA, USA	1:100	Human kidney cancer
RhoA	(SA2326231) ThermoFisher Scientific, Milan, Italy	1:100	Human kidney cancer
PI3K	(Sc- 2355932) ThermoFisher Scientific, Milan, Italy	1:100	Human prostate cancer
Akt	(ENTO-185) ElabScience Biotechnology Co., Houston, TX, USA	1:100	Human prostate cancer
p-Akt	(44621-G) ThermoFisher Scientific, Milan, Italy	1:100	Human prostate cancer
p-mTOR	(F17-65R) SignalChem, Richmond, BC, Canada	1:100	Human prostate cancer

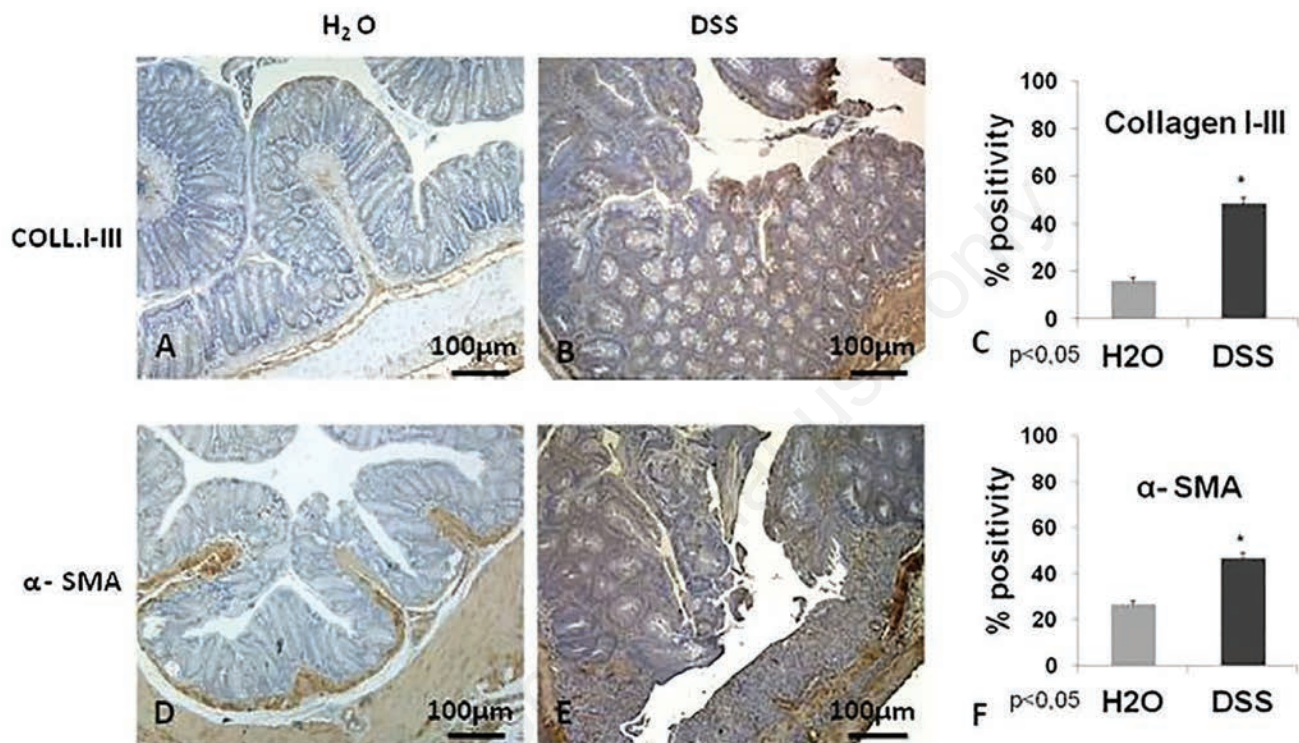
control mice (Figure 3 A,D), while there was a significant increase in immunopositivity in DSS mice (Figure 3 B,E) as confirmed by quantitative data (Figure 3 C,F). In particular, in DSS treated group,  $\alpha$ -SMA staining was not limited to the smooth muscle cells of the muscularis mucosa and muscularis propria but it was also present in lamina propria, submucosa and serosa

(Figure 3E). In control group the expression was restricted to typical layers (Figure 3D).

Immunopositivity for TGF- $\beta$  and phosphorylated Smad3 resulted slightly expressed in untreated control mice (Figure 4 A,D), while they were markedly increased in DSS group (Figure 4 B,E). Concerning Smad7 inhibitor protein, the immunopositivity was significantly higher

in control respect to DSS (Figure 4 G,H). These data were confirmed by quantitative analysis (Figure 4 C,F,I).

Immunohistochemical and quantitative analysis for Sphingosine Kinase 1 (SPHK1) showed an increased expression in DSS mice (Figure 5 B,C) compared to control group (Figure 5 A,C), according to the fact that TGF- $\beta$  is able to activate and upregu-



**Figure 3.** Immunohistochemistry (original magnification 10x). Collagen I-III and  $\alpha$ -SMA are mild expressed in control mice (A,D), while there is a significant increase in immunopositivity in DSS mice (B,E).

**Table 2.** Clinical findings and macroscopic features of DSS-induced chronic colitis.

Parametres	H <sub>2</sub> O	DSS
Duration of DSS administration (days)	0	36
Number of mice	5	15
Mortality (n.mice)	0	2
Body weight (gr)	28.44 $\pm$ 0.51	26.20 $\pm$ 0.31**
Colon weight (gr)	0.187 $\pm$ 0.006	0.305 $\pm$ 0.008**
Colon lenght (cm)	8.78 $\pm$ 0.015	6.8 $\pm$ 0.19**
Colon weight/size ratio (fold change)	1 $\pm$ 0.042	2.113 $\pm$ 0.08**
Dilatation	np	1.23 $\pm$ 0.22**
Tickness	np	0.76 $\pm$ 0.2*
Stenosis	np	0.92 $\pm$ 0.23*
Adhesions	np	0.73 $\pm$ 0.22 np
Total macroscopic score	np	3.64 $\pm$ 0.435**

Data are expressed as mean $\pm$ SEM; np, not present; \*P<0.05 vs H<sub>2</sub>O; \*\*P<0.01 vs H<sub>2</sub>O.



late this molecule in fibrotic condition. Above all, SPHK1 positivity was predominantly localized in mucosa layer and in submucosa of colon from DSS mice.

RhoA and PI3K staining resulted slightly expressed in control mice (Figure 5 D,G), while was highly increased in DSS treated group, mainly in mucosa (strongly in the epithelium, Supplementary Figure 1), but also in submucosa and in serosa (Figure 5 E,H). These data were confirmed by quantitative analysis (Figure 5 F,I). A marked increase of both Akt and phosphorylated Akt was observed in mucosa, submucosa and serosa of DSS treated mice (Figure 6 B,E) compared to untreated mice (Figure 6 A,D) has also shown by quantitative assessment (Figure 6 C,F).

Phosphorylated m-TOR staining was

mildly expressed in mucosa of control mice (Figure 6G), while was increased in mucosa (specially in the epithelial cells, Supplementary Figure 1), in submucosa and in serosa of mice receiving DSS (Figure 6H). The different levels of immunopositivity between the two groups were also highlighted by quantitative analysis (Figure 6I).

## Discussion

The activation of SPHK1 and generation of S1P, the bioactive lipid of sphingomyelin, plays an important role in a variety of physiologic and pathologic cellular processes in many organs.<sup>9,13,17</sup> Several evidences suggest a pro-fibrogenic role of

SPHK1 pathway carried out through different mechanisms including the influence on epithelial barrier function, the inflammatory cell recruitment and the activation of myofibroblast (migration, proliferation, differentiation and contraction).

In the present study we investigate the *in vivo* interaction between TGF- $\beta$  and SPHK1 signaling in a mouse model of DSS-induced chronic colitis, in order to verify whether SPHK1 and its effectors were able to interact with TGF- $\beta$ /Smad signaling and if they were involved in the induction and progression of the intestinal fibrosis. Clinical signs observed in DSS-receiving mice were coherent with the development of colonic fibrosis, with a significant increase of the total macroscopic score and histological parameters, com-

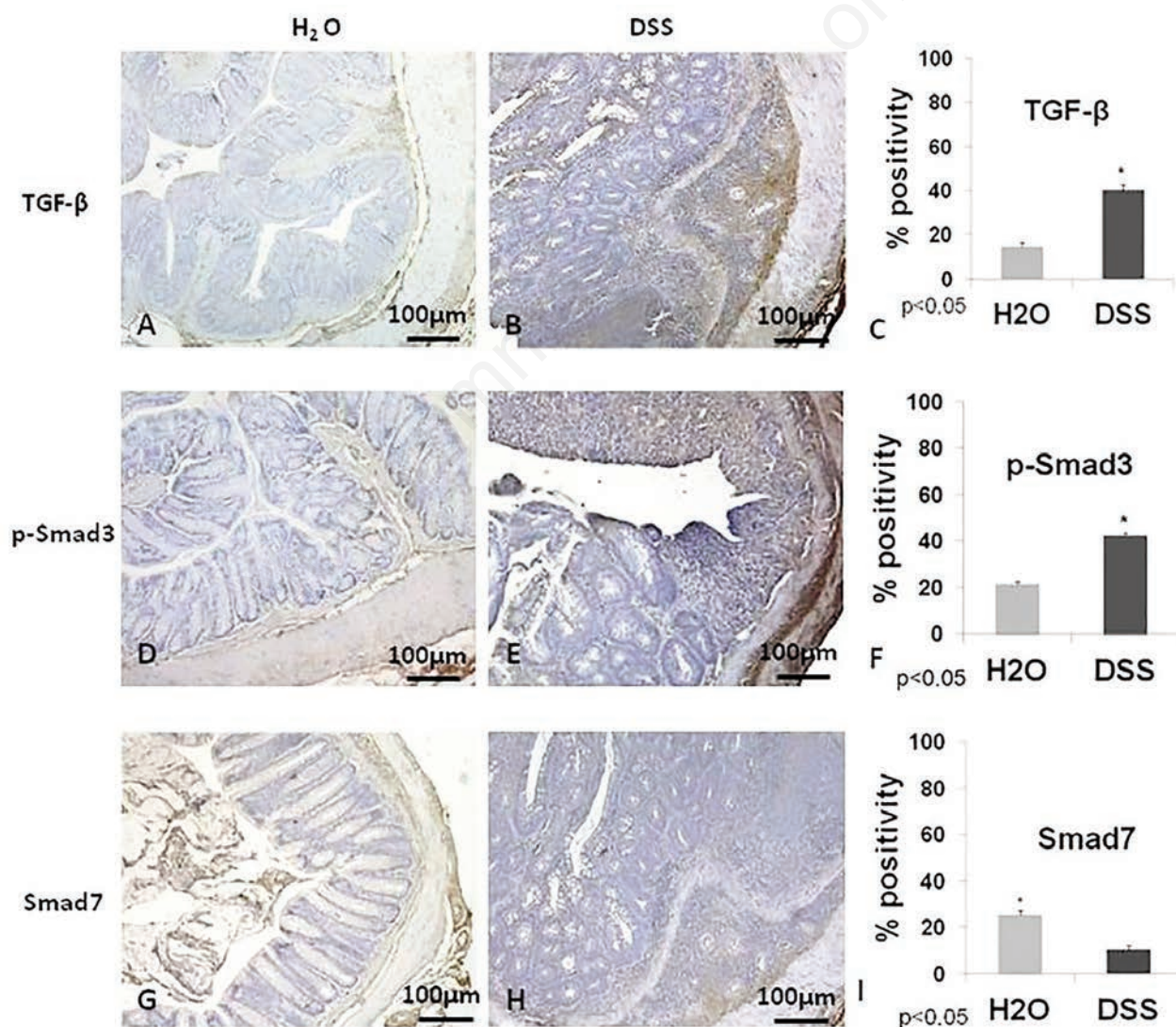


Figure 4. Immunohistochemistry (original magnification 10x). TGF- $\beta$ , p-Smad3, are significantly increased in DSS mice (B,E) while they are mild expressed in control mice (A,D). The inhibitor protein Smad7 shows a lower positivity in DSS mice (H) respect to control (G).

pared to control mice. Immunohistochemical evaluations demonstrated overexpression of the main marker of myofibroblasts activation, with consequent accumulation of collagen in lamina propria and submucosal layer altering the normal architecture of colonic wall with respect to the normal morphology of the control group.

According to other research group, which have previously shown the potential profibrotic role of SPHK1 in pulmonary, cardiac, liver and kidney fibrosis, we demonstrate a close relationship between TGF- $\beta$  and SPHK1 expressions in mice developing intestinal fibrosis. A concomitant upregulation of TGF- $\beta$ -1, p-Smad3, SPHK1, RhoA, PI3K was found in DSS mice compared to controls. These findings

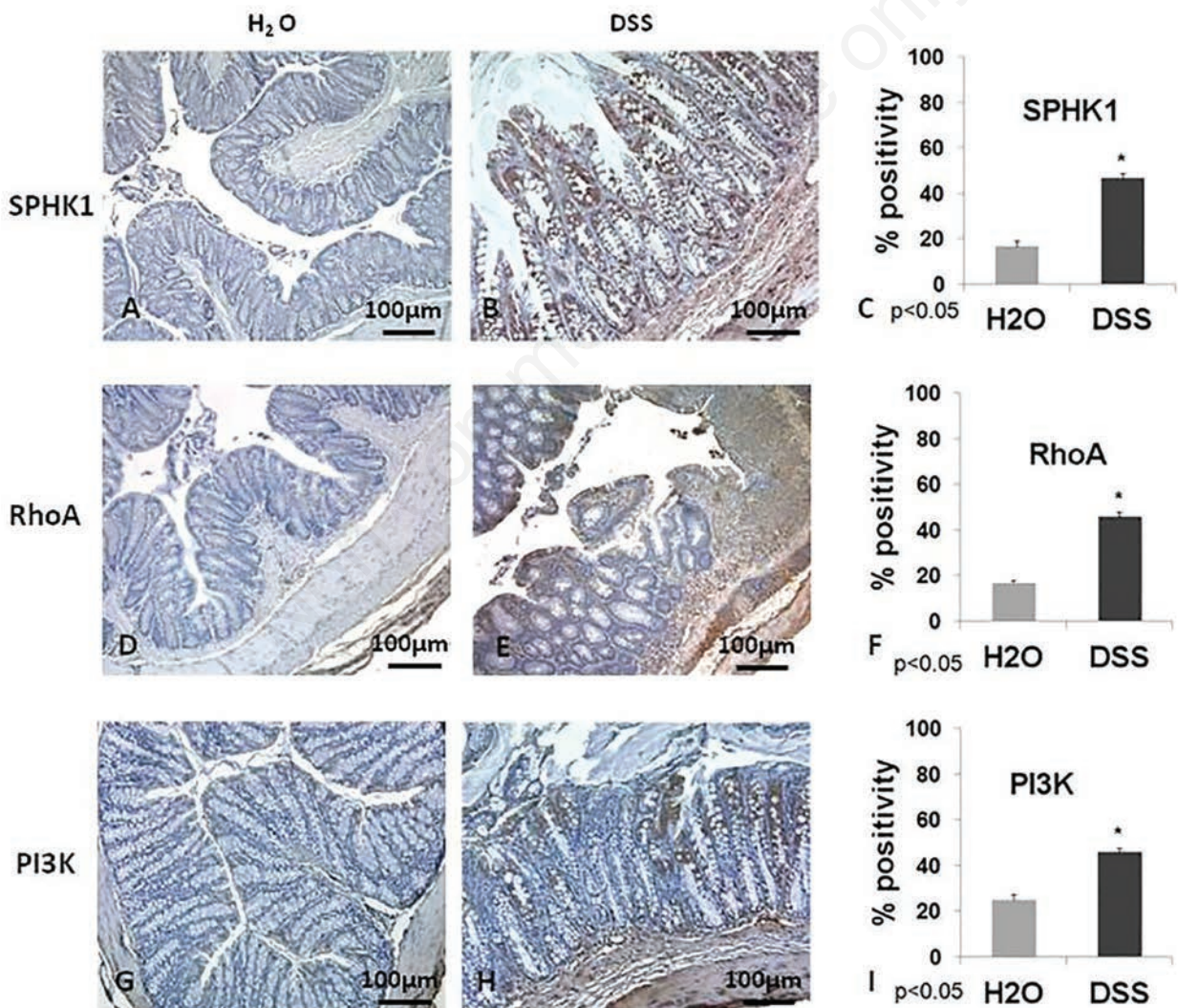
demonstrated that SPHK1 and RhoA are mediators of inflammation and fibrosis. As it occurs in other organs,<sup>24,25</sup> the increasing expression of SPHK1 could influence the upregulation of RhoA responsible for inflammatory gene expression subsequently leading to activation of autocrine inflammatory intestinal signaling. We have also observed an increased expression of PI3K, AKT, p-AKT and p-m-TOR in all colonic layers of DSS treated mice compared to controls. TGF- $\beta$  can activate PI3K/AKT/m-TOR signaling and RhoA may be an upstream mediator of AKT activation that can be also involved in the EMT.<sup>26,27</sup>

SPHK1 appears to facilitate also in the intestine the action of the critical pro-fibrotic factor TGF- $\beta$  as occur in other organs, promoting transformation of fibroblasts and

epithelial cells into activated myofibroblasts.<sup>28</sup>

These *in vivo* data support the hypothesis that TGF- $\beta$  stimulates production of S1P *via* increased SPHK1 activity which is then released and acts on the S1P2 receptor to promote pro-fibrotic cellular transformation and function. Therefore, the development of intestinal fibrosis could be influenced not only by TGF- $\beta$ /Smad pathway but also by crosstalk between TGF- $\beta$ /SPHK1/S1P signaling by influencing the expression of pro-fibrotic gene as collagen and  $\alpha$ -SMA levels (Figure 7).

Despite more detailed investigations, such as *in vitro* studies, are needed to elucidate the involvement of the different S1P receptors in chronic intestinal inflammation and fibrosis, these preliminary data support



**Figure 5.** Immunohistochemistry (original magnification 10x). The immunopositivity of SPHK1, RhoA and PI3K is prevalent in DSS mice (B,E,H) respect to control (A,D,G). In particular, in DSS mice, SPHK1 expression is predominantly localized in mucosa layer and in submucosa of colon (B). In the same group RhoA and PI3K staining results highly expressed (E,H) in mucosa, especially in the epithelium (supplementary Figure 1), but also in submucosa and in serosa.



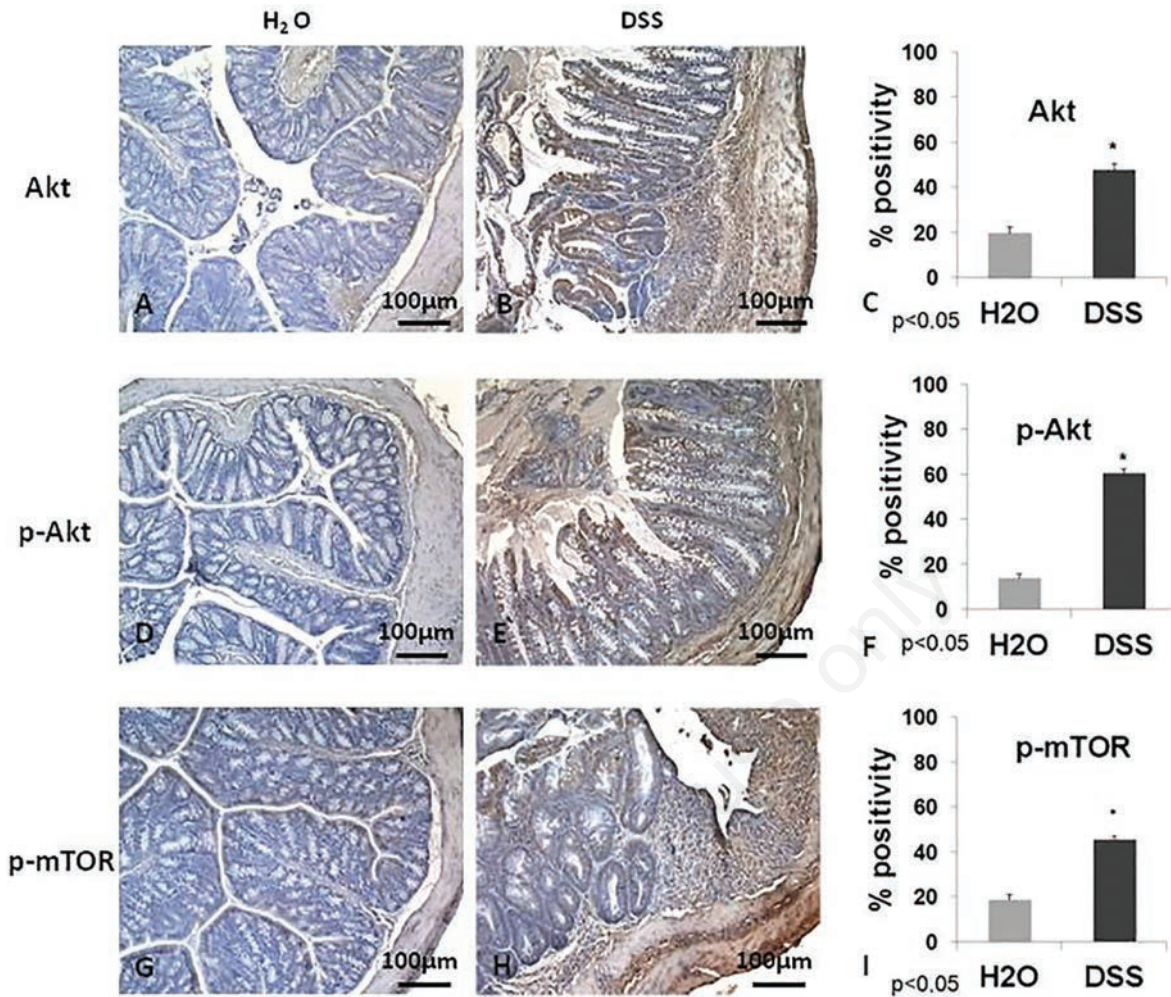


Figure 6. Immunohistochemistry (original magnification 10x). A marked increase of both Akt and phosphorilated Akt is observed in mucosa, submucosa and serosa of DSS treated mice (B,E) compared to controls (A,D). Phosphorilated m-TOR staining is mild expressed in mucosa of control mice (G), while the immunopositivity is increased in epithelial cells (supplementary Figure 1), in submucosa and in serosa of DSS treated mice (H).

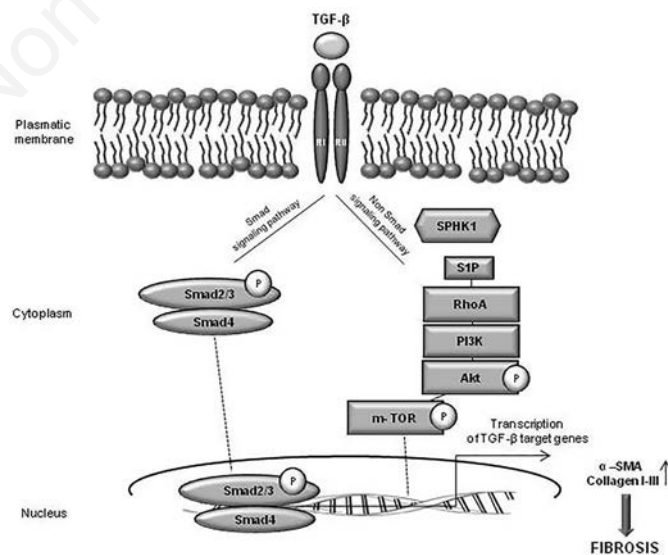


Figure 7. Schematic representation of TGF-β dependent signaling implicated in fibrosis process. TGF-β upon binding its receptors, activates both canonical Smads pathway and noncanonical pathway (SPHK1/S1P/mTOR), inducing transcription of pro-fibrotic target genes.



the hypothesis of a possible interaction between the above-mentioned molecules in the development of colorectal fibrosis in mice. Development of molecules to regulate the synthesis of S1P and to selectively block or stimulate different S1P receptor subtypes could be an attractive target for the development of new pharmacological treatments of intestinal fibrosis.<sup>29</sup>

## References

1. Fiocchi C, Lund PK. Themes in fibrosis and gastrointestinal inflammation. *Am J Physiol Gastrointest Liver Physiol* 2011;300:G677-83.
2. Rieder F, Fiocchi C. Mechanisms of tissue remodeling in inflammatory bowel disease. *Dig Dis* 2013 31:186-93.
3. Lawrance IC, Rogler G, Bamias G, Breynaert C, Florholmen J, Pellino G, et al. Cellular and molecular mediators of intestinal fibrosis. *J Crohns Colitis* 2017;11:1491-503.
4. Di Gregorio J, Sferra R, Specia S, Vetusch A, Dubuquoy C, Desreumaux P, et al. Role of glycogen synthase kinase-3 $\beta$  and PPAR- $\gamma$  on epithelial-to-mesenchymal transition in DSS-induced colorectal fibrosis. *PLoS One* 2017;12:e0171093.
5. Latella G, Vetusch A, Sferra R, Specia S, Gaudio E. Localization of  $\alpha$ v $\beta$ 6 integrin-TGF- $\beta$ 1/Smad3, mTOR and PPAR $\gamma$  in experimental colorectal fibrosis. *Eur J Histochem* 2013;57:e40.
6. Sferra R, Vetusch A, Pompili S, Gaudio E, Specia S, Latella G. Expression of pro-fibrotic and anti-fibrotic molecules in dimethylnitrosamine-induced hepatic fibrosis. *Pathol Res* 2016;213:58-65.
7. Bhowmick NA, Ghiassi M, Bakin A, Aakre M, Lundquist CA, Engel ME, et al. Transforming growth factor-beta1 mediates epithelial to mesenchymal transdifferentiation through a RhoA-dependent mechanism. *Mol Biol Cell* 2001;12:27-36.
8. Patel S, Takagi KI, Suzuki J, Imaizumi A, Kimura T, Mason RM, et al. RhoGTPase activation is a key step in renal epithelial mesenchymal transdifferentiation. *J Am Soc Nephrol* 2005; 16:1997-84.
9. Lawrence J, Nho R. The role of the mammalian target of rapamycin (mTOR) in pulmonary fibrosis. *Int J Mol Sci* 2018;19:778.
10. Ammit AJ, Hastie AT, Edsall LC, Hoffman RK, Amrani Y, Krymskaya VP, et al. Sphingosine 1-phosphate modulates human airway smooth muscle cell functions that promote inflammation and airway remodeling in asthma. *FASEB J* 2001;15:1212-4.
11. Hla T. Signaling and biological actions of sphingosine 1-phosphate. *Pharmacol Res* 2003;47:401-7.
12. Alemany R, van Koppen CY, Dannenberg K, Ter Braak M, Meyer Zu, Heringdorf D. Regulation and functional roles of sphingosine kinases. *Naunyn Schmiedebergs Arch Pharmacol* 2007;374:413-28.
13. Liu W, Lan T, Xie X, Huang K, Peng J, Huang J, et al. S1P2 receptor mediates sphingosine-1-phosphate-induced fibronectin expression via MAPK signaling pathway in mesangial cells under high glucose condition. *Exp Cell Res* 2012;318:936-43.
14. Yang AH, Ishii I, Chun J. In vivo roles of lysophospholipid receptors revealed by gene targeting studies in mice. *Biochim Biophys Acta* 2002;1582:197-203.
15. Schwalm S, Timcheva TM, Filipenko I, Ebadi M, Hofmann LP, Zangemeister-Wittke U, et al. Sphingosine kinase 2 deficiency increases proliferation and migration of renal mouse mesangial cells and fibroblasts. *Biol Chem* 2017;396:813-25.
16. Giacomini MM, Travis MA, Kudo M, Sheppard D. Epithelial cells utilize cortical actin/myosin to activate latent TGF- $\beta$  through integrin  $\alpha$ (v) $\beta$ (6)-dependent physical force. *Exp Cell Res* 2012;318:716-22.
17. Kono Y, Nishiuma T, Nishimura Y, Kotani Y, Okada T, Nakamura S, et al. Sphingosine kinase 1 regulates differentiation of human and mouse lung fibroblasts mediated by TGF-beta1. *Am J Respir Cell Mol Biol* 2007;37:395-404.
18. Milara J, Navarro R, Juan G, Peiró T, Serrano A, Ramón M, et al. Sphingosine-1-phosphate is increased in patients with idiopathic pulmonary fibrosis and mediates epithelial to mesenchymal transition. *Thorax* 2016;67: 147-56.
19. Gellings LN, Swaney JS, Moreno KM, Sabbadini RA. Sphingosine-1-phosphate and sphingosine kinase are critical for transforming growth factor-beta-stimulated collagen production by cardiac fibroblasts. *Cardiovasc Res* 2009;82:303-12.
20. Pchejetski D, Foussal C, Alfarano C, Lairez O, Calise D, Guilbeau-Frugier C, et al. Apelin prevents cardiac fibroblast activation and collagen production through inhibition of sphingosine kinase 1. *Eur Heart J* 2011;33:2360-9.
21. Lan T, Shen X, Liu P, Liu W, Xu S, Xie X, et al. Berberine ameliorates renal injury in diabetic C57BL/6 mice: Involvement of suppression of SphK-S1P signaling pathway. *Arch Biochem Biophys* 2010;502:112-20.
22. Ikeda H, Yatomi Y, Yanase M, Satoh H, Maekawa H, Ogata I, et al. Biological activities of novel lipid mediator sphingosine 1-phosphate in rat hepatic stellate cells. *Am J Physiol Gastrointest Liver Physiol* 2000;279:G304-10
23. Latella G, Vetusch A, Sferra R, Zanninelli G, D'Angelo A, Catitti V. Smad3 loss confers resistance to the development of trinitrobenzene sulfonic acid-induced colorectal fibrosis. *Eur J Clin Invest* 2009;39:145-56.
24. Dusaban SS, Chun J, Rosen H, Purcell NH, Brown JH. Sphingosine 1-phosphate receptor 3 and RhoA signaling mediate inflammatory gene expression in astrocytes. *J Neuroinflammation* 2017;14:111.
25. Tauseef M, Kini V, Knezevic N, Brannan M, Ramchandaran R, Fyrst H, et al. Activation of sphingosine kinase-1 reverses the increase in lung vascular permeability through sphingosine-1-phosphate receptor signaling in endothelial cells. *Circ Res* 2008;103: 1164-72.
26. Liu RH, Ning B, Ma Xiao-EN, Gong Wei-Ming, Jia TH. Regulatory roles of microRNA-21 in fibrosis through interaction with diverse pathways. *Mol Med Rep* 2016;13:2359-66.
27. Kattla JJ, Carew RM, Heljic M, Godson C, Brazil DP. Protein kinase B/Akt activity is involved in renal TGF- $\beta$ 1-driven. *Physiol Renal Physiol* 2008; 295:F215-2.
28. Wynn TA. Cellular and molecular mechanisms of fibrosis. *J Pathol* 2008; 214:199-210.
29. Rieder F, Latella G, Magro F, Yuksel ES, Higgins PD, Di Sabatino A, et al. European Crohn's and Colitis Organisation Topical review on prediction, diagnosis and management of fibrotic Crohn's Disease. *J Crohns Colitis* 2016;10:873-85.