



**HAL**  
open science

## Real-life evaluation of the treatment of actinic keratoses by textile photodynamic therapy (FLUXMEDICARE® device).

M. Dubois, Henry Abi Rached, Frédéric Dezoteux, Cyril Maire, C. Vicentini, Helene Behal, Elise Thecua, Fabienne Lecomte, Serge Mordon, Laurent Mortier

### ► To cite this version:

M. Dubois, Henry Abi Rached, Frédéric Dezoteux, Cyril Maire, C. Vicentini, et al.. Real-life evaluation of the treatment of actinic keratoses by textile photodynamic therapy (FLUXMEDICARE® device).. Photodiagnosis and Photodynamic Therapy, 2021, Photodiagnosis and Photodynamic Therapy, 34, pp.102213. 10.1016/j.pdpdt.2021.102213 . hal-04540070

HAL Id: hal-04540070

<https://hal.univ-lille.fr/hal-04540070>

Submitted on 22 Jul 2024

**HAL** is a multi-disciplinary open access archive for the deposit and dissemination of scientific research documents, whether they are published or not. The documents may come from teaching and research institutions in France or abroad, or from public or private research centers.

L'archive ouverte pluridisciplinaire **HAL**, est destinée au dépôt et à la diffusion de documents scientifiques de niveau recherche, publiés ou non, émanant des établissements d'enseignement et de recherche français ou étrangers, des laboratoires publics ou privés.



Distributed under a Creative Commons Attribution - NonCommercial 4.0 International License

## **Real-life evaluation of the treatment of actinic keratoses by textile photodynamic therapy (FLUXMEDICARE® device)**

M. Dubois<sup>1</sup>, H. Abi Rached<sup>1,2</sup>, F. Dezoteux<sup>1,3</sup>, C. Maire<sup>1,2</sup>, C. Vicentini<sup>1,2</sup>, H. Behal<sup>4</sup>, E. Thecua<sup>2</sup>,  
F. Lecomte<sup>2,5</sup>, S. Mordon<sup>2</sup>, L. Mortier<sup>1,2</sup>

1. CHU Lille, Service de Dermatologie, F-59000 Lille, France
2. Univ. Lille, Inserm, CHU Lille, U1189 - ONCO-THAI - Assisted Laser Therapy and Immunotherapy for Oncology, F-59000 Lille, France
3. Univ. Lille, Inserm, CHU Lille, U1286 - Institute for translational Research in Inflammation INFINITE, F-59000 Lille, France
4. Univ. Lille, CHU Lille, ULR 2694 - METRICS : Évaluation des technologies de santé et des pratiques médicales, F-59000 Lille, France
5. Univ. Lille, CHU Lille, EA2694: Santé Publique, épidémiologie et qualité des soins. CERIM, F-59000 Lille, France

Key words: actinic keratosis ; light emitting fabrics ; photodynamic therapy ; drug light interval

Conflict of interest: The FLUXMEDICARE device was graciously lent to the dermatology department of Lille university hospital by TEXINOV.

Corresponding authors: Manon Dubois

Adress: CHU Lille, Service de Dermatologie, F-59000, Lille, France

Phone: +33 3.20.44.41.93

Mail: [manon.dubois@chru-lille.fr](mailto:manon.dubois@chru-lille.fr),

Word count :

Abstract = 185 words

Capsule summary = 87 words

Manuscript text = 2472 words

Number of references = 34

Number of figures = 3

Number of tables = 1

## **Real-life evaluation of the treatment of actinic keratoses by textile photodynamic therapy (FLUXMEDICARE® device)**

### **ABSTRACT**

**Introduction:** Actinic keratoses (AK) are a common precancerous skin condition in dermatology practice. Photodynamic therapy (PDT) is an effective but painful treatment of fields of cancerization. Two studies showed that textile PDT was not inferior to conventional PDT. FLUXMEDICARE® (FLX-PDT) is the first medical device marketed. We realized a real-life study to evaluate efficacy and tolerance of this device.

**Methods:** We carried out a single-center retrospective study. We collected data from patients treated with FLX-PDT for AKs localized on scalp and temples between November 2018 and November 2019. The primary endpoint was complete clearance rate (CR) at 3 months-follow up.

**Results:** Data of 39 patients were reviewed in the study, with a total of 417 AKs. The CR rate was 72.6% (95%CI 67.9-77.0) at 3 months-follow up and 67.5% (95%CI 61.2-73.3) at 6 months-follow up. The median pain felt during the session was 0 and there wasn't erythema after the session for 64.1%.

**Conclusion:** Our real-life study confirms efficacy and safety of textile PDT by FLUXMEDICARE device in the treatment of scalp and temples AKs, with excellent tolerance.

### **CAPSULE SUMMARY**

#### **What's already known about this topic?**

- Photodynamic therapy is an effective but painful treatment for actinic keratosis.
- FLUXMEDICARE® is the only and the first marketed device, and presents some differences in tissue conformation compared to PHOS-ISTOS® device.

#### **What does this study add?**

- Our real-life study confirms efficacy, safety and tolerance of textile PDT by the first marketed device (FLUXMEDICARE®) in the treatment of scalp and temples AKs.
- The efficacy of textile PDT appears to be good in immunocompromised subjects.

## INTRODUCTION

Actinic keratoses (AKs) are a very common precancerous skin condition in daily dermatology practice<sup>1</sup>. AKs are a marker of UV-induced skin damage and precancerous lesions that carry a risk of evolving into a squamous cell carcinoma (SCC)<sup>2-4</sup>.

Multiple treatment options are available but have heterogeneous efficacy with sometimes high recurrence rates<sup>5</sup>. To date, no AKs treatment demonstrated a long-term efficacy on lesion clearance<sup>6</sup>. The role of “fields of cancerization”<sup>7-9</sup> is increasingly highlighted in publications, and many authors consider that treatments should target the entire affected area where subclinical lesions could be found<sup>10, 11</sup>.

Photodynamic therapy (PDT) is an effective treatment for “fields of cancerization”, with response rates between 80 and 90% at 3 months<sup>11-14</sup>. In Europe, conventional PDT (C-PDT) uses Methyl aminolevulinate (MAL) cream as a photosensitizer (Protoporphyrin IX or PpIX) precursor, and the AKTILITE CL 128<sup>®</sup> device (Galderma SA, Lausanne, Switzerland) for an illumination of 7 to 10 minutes after a 3 hours incubation of MAL in the dark, under a light protective dressing. The main limitation of C-PDT is pain during the sessions<sup>12, 13, 15</sup> due to the photodynamic reaction, that could be explained by the high delivered irradiance (75mW/cm<sup>2</sup>) and by PPIX accumulation during a long Drug Light Interval (DLI) (3 hours)<sup>16</sup>. Two randomized studies (FLEXITHERALIGHT<sup>®17</sup> and PHOS-ISTOS<sup>®18</sup> protocols) evaluated the efficacy of PDT using light emitting fabrics with lower fluence and irradiance (respectively 37J/cm<sup>2</sup> and 12.3 mW/cm<sup>2</sup> in FLEXITHERALIGHT<sup>®</sup> ; 12J/cm<sup>2</sup> and 1.3 mW/cm<sup>2</sup> in PHOS-ISTOS<sup>®</sup>). The results of FLEXITHERALIGHT<sup>®</sup> and PHOS-ISTOS<sup>®</sup> studies showed that PDT using light emitting fabrics was not inferior to conventional PDT (C-PDT), and reported AK complete clearance rate of 66% at 3 months with FLEXITHERALIGHT<sup>®</sup> device, and 79.3% at 3 months and 94.2% at 6 months with PHOS-ISTOS<sup>®</sup> device versus 80.7% at 3 months and 94.9% at 6 months with C-PDT. The medical device received a European EC labeling (to meet EU safety, health and environmental protection requirements) on 2018 and is marketed for clinical use under the name FLUXMEDICARE<sup>®</sup> (MDB Texinov, Saint Didier de la Tour, France). FLUXMEDICARE<sup>®</sup> delivers same fluence and irradiance as the device used in PHOS-ISTOS<sup>®</sup> study, but with some slight differences in tissue conformation. The aim of this study was to evaluate the efficacy and tolerance of FLUXMEDICARE<sup>®</sup> in a real-life practice.

## **PATIENTS AND METHODS**

### *Study design*

We carried out a single-center retrospective study in the dermatology department of the Lille University hospital. We collected data from patients treated with textile PDT using the FLUXMEDICARE® device (FLX-PDT) for actinic keratoses between November 2018 and November 2019.

This study has been declared to and accepted by the CNIL (Commission Nationale Informatique et Libertés), organization in charge of the ethical use of data collected for scientific purposes in France (DEC19-364). All patients agreed and signed a written consent to take and use photographs of their lesions for scientific purposes. In line with the French Data Use Act, patients were informed in writing of the anonymous use of their medical data and the possibility of removing their consent at any time.

### *Study population*

The medical records of patients treated by FLX-PDT for AK lesions on scalp and temples in Lille University hospital from November 2018 to November 2019 were reviewed. We collected the following informations from patients' medical files: demographic characteristics, history of skin cancer, immune status, Fitzpatrick's phototype, profession, past sun exposure, smoking habits, and history of previous AKs treatments, number of AKs, grade of AKs (according to the classification of Olsen *et al.*<sup>19</sup>), AKASI (Actinic Keratosis Area and Severity Index) score<sup>20, 21</sup>.

AKASI score is designed to quantitatively evaluate the severity of AK on the head, ranging from 0 to 18 and correlated with fields of cancerization severity<sup>20</sup>. AKASI score is associated with the incidence of SCC and seemed of interest as an assessment tool for standard patients follow-up<sup>21</sup>.

### *Features of the FLUXMEDICARE device*

The FLUXMEDICARE device is the only textile-PDT device currently available on the market. It consists of a light source connected to strips of knitted light emitting fabrics that can be adapted to various skin areas. The device is calibrated to deliver red light with a wavelength of 638nm, an irradiance of 1.3 mW/cm<sup>2</sup> for 150 minutes and a fluence of 12 J/cm<sup>2</sup> (Figure 1). Moreover, the DLI is only 30 minutes in our treatment protocol. We used the TEXTLIGHT1 (Figure 2A) band

(illuminated surface 18x20cm) for the treatment of the scalp and forehead and the TEXTLIGHT 3 (Figure 2B) bands (2 devices of 6x20cm allowing a simultaneous bilateral treatment of the 2 temples). Since the luminous textile is positioned in contact with the skin surface, there is no light emitted in the room. No eye protection is therefore necessary during the sessions.

### *Treatment*

**Pre-treatment:** The usual protocol in our center consists of prescribing to the patient a 20% urea dosed keratolytic preparation to be applied during 10 days before session on the to-be-treated area. A gentle curettage of lesions is performed before PDT session.

**Treatment:** A thin layer of MAL is applied on AKs with a margin of about 1 cm around each lesion and on the whole affected area (field of cancerization). The treatment area is covered by a transparent occlusive dressing or a transparent cap. The textile device TEXTLIGHT 1 (for scalp and forehead) or TEXTLIGHT 3 (for temples) is applicated and fixed by a net and covered by an opaque cap. The MAL cream is incubated in the dark for 30 minutes before illumination. The MAL cream is not removed, so incubation is not stopped during the illumination. Then, we deliver a 635nm red light through the light-emitting fabric previously knitted on the inside of a cap for 150 min. Afterwards, we advise the patient to apply simple healing ointment for a few days after sessions to improve healing process and we recommend avoiding sun exposure.

Patients were followed-up at 3 months after the first PDT session to assess the efficacy. When patients had more than four unresolved AKs after the first session, they received a second FLX-PDT.

When patients had less than five unresolved AKs after one session, a targeted treatment such as cryotherapy was performed to clear the remaining lesions. A satisfaction questionnaire completed by the patient after the PDT session was provided by the company during the first year of use of the device. This questionnaire evaluated: adaptability of the device, comfort, pain, light-induced discomfort, if the patient recommend the device, what the patient did during the treatment, if he had to interrupt the treatment and why, and if he had any comment or improvement about the device. The data from this questionnaire was collected.

### *End points*

The primary end point was PDT clinical efficacy defined by a AKs complete clearance rate (CR) at 3 months. The secondary endpoints were AKs CR at 6 months, AKASI score at 3 to 6 months, pain during illumination, erythema at the end of illumination, and the patient satisfaction. Pain was assessed by a simple numerical scale between 0 (no pain) and 10 (worst pain)<sup>22</sup>. Erythema was ranked as 0 (no erythema), 1 (mild erythema), 2 (moderate erythema) and 3 (severe erythema)<sup>23</sup>.

### *Statistical analysis*

Continuous variables were expressed as means and standard deviations in case of normal distribution or as medians and interquartile ranges otherwise. Normality of the distribution was checked graphically and using the Shapiro-Wilk test. The categorical variables were expressed as frequencies and percentages.

The complete response rate at 3 months was compared according to the grade, the localization, the immunocompromised status and the number of previous AK treatment, using the generalized linear mixed model to take into account for the correlation between repeated lesions within subjects by including a random coefficient. All of the statistical analyses were performed using SAS software version 9.4 (SAS Institute Inc., Cary, North Carolina, USA).

## **RESULTS**

### **Patients**

Data of 39 patients were reviewed in the study, with a total of 417 AKs. 35 patients were treated for scalp AKs, 3 for scalp and temples AKs, and 1 for temples AKs only. Patients had an average of 11.5 AKs (ranging from 5 to 25). PDT was the first line treatment for 10 patients. Eighteen patients had previously been treated with conventional PDT. Lesions were asymptomatic in 51.3% of our patients. 28% complained of pruritus and 12.8% of aesthetic discomfort. The average AKASI score at the first visit was 4.3. Five patients were immunocompromised and 3 were receiving PD1 inhibitors for an unrelated disease. 36 patients were evaluated at 3 months after FLX-PDT (3 patients died of an unrelated cause before reevaluation). Due to at least five remaining AK lesions, 14 patients received a second PDT session. Twenty-two patients were evaluated at 6 months of the follow-up. The remaining

patients had not yet been reassessed at the time of writing. Patients' baseline characteristics are presented in Table 1.

### **Efficacy**

The CR rate was 72.6% (95%CI 67.9-77.0) at 3 months-follow up. It was significantly higher for grade I AK (77.9%) compared to grade II AK (61.9%) ( $p = 0.011$ ). The CR rate for scalp AK lesions and temples AK lesions were similar (respectively 72.3% and 75.6%), and no significant difference were highlighted ( $p = 0.75$ ).

Twenty-two patients were evaluated at 6 months. The global CR rate was 67.5% (95%CI 61.2-73.3). The median AKASI score was 1.2 (IQR, 0.6 to 2.4) at 3 months and 1.8 (IQR, 0.8 to 2.8) at 6 months.

Five patients in our cohorts were immunocompromised (three patients were renal transplant patients with immunosuppressive therapy, one patient had high-dose corticosteroid therapy for diffuse interstitial lung disease, and one patient had rheumatoid arthritis treated with Rituximab). The CR rate at 3 months follow-up in this subgroup of patients was 78.0% versus 71.7% in the general population. No significant difference was highlighted between the 2 groups ( $p = 0.48$ ).

We compared patients who received 0 or 1 AK treatment prior to our study with patients treated more than once. The CR rate in the group "0 or 1 previous AK treatment" was significantly higher than multi treated patients (respectively 82.5% and 66.8%,  $p = 0.015$ ), but this difference was no longer significant after adjustment for lesion grade and AKASI ( $p = 0.15$ ).

### **Tolerability**

#### *Pain*

The median pain felt during the first session was 0 (range, 0 to 5) on the simple numerical scale. Five patients needed to take a break during treatment (less than 5 min), but none because of pain.

#### *Erythema*



The erythema observed at the end of the session was 0 (no erythema) for 25 patients (64.1%), 1 (mild erythema) for 11 patients (28.2%), 2 (moderate erythema) for 3 patients (7.7%). No patient had severe erythema following treatment. One patient consulted 4 days after PDT because of a mild skin inflammatory reaction that healed rapidly without further complication.

### *Satisfaction*

35 of the 39 patients completed the satisfaction standardized questionnaire. 22 (62.9%) of them found the device very convenient, 12 (34.3%) of them found it fairly convenient. 9 (25.7%) patients felt the device was very comfortable and 22 (62.9%) found it fairly comfortable. More than half patients stated the treatment was painless, 14 reported very little pain, 1 patient mild pain and 1 patient severe pain. Among the 35 patients who answered the questionnaire, 31 patients recommended FLX-PDT, and 4 of them refused to complete it because they were waiting for the final result to deliver a judgement.

## **DISCUSSION**

This study confirms the positive results of the previous textile PDT clinical trials<sup>17, 18</sup>. We observed 72.6% of CR rate at 3 months, which is comparable to the results published by Vicentini *et al.*<sup>17</sup> (66%) and Mordon *et al.*<sup>18</sup> (79.3%).

Few studies assess the long-term response of AKs. The data in the literature suggest a prolonged efficacy, with response rates around 70-80% at 12 months of treatment with conventional PDT or daylight PDT<sup>24,25</sup>. We do not yet have the results at 12 months, but the CR rate was 67.5% at 6 months which suggest a prolonged efficacy. However, our response rates at 6 months are lower than reported by Vincentini *et al.*<sup>17</sup> (84%) and Mordon *et al.*<sup>18</sup> (94%). The difference could be explained by various sample size between the three studies and slightly more severe patients in a real life setting. We could also argue that different physicians were involved in our study which leads to differences in skin preparation and lesion evaluation. Interestingly, patients who received multiple treatments have worse response rates than those who were did not. This result can be explained by the fact that these patients are multi-treated because they have more or more severe lesions, as shown in adjusted analysis, but we hypothesize also that AKs could become resistant after multiple therapies.

Despite limited number of patients, the response rate in immunocompromised patients appears to be comparable to immunocompetent subjects. Several studies in the literature confirm the effectiveness of PDT in treating AKs in transplanted subjects<sup>26,27</sup>.

The FLX-PDT procedure is based on a short DLI of 30 minutes and a low irradiance of 1.3 mW/cm<sup>2</sup> for 150 minutes, which allows a continuous metabolism and photodegradation of PpIX, thus ensuring low PpIX accumulation<sup>28</sup>. Furthermore, the continuous photobleaching prevents an unnecessarily high PpIX accumulation that could reach the dermis nerves and accentuate pain. Therefore, we obtained an excellent tolerance with a median pain of 0/10 during FLX-PDT, thus a high level of patients' satisfaction unlike to C-PDT with 55-60% of patients experiencing moderate pain<sup>29, 30</sup>. The patients' satisfaction rates are similar to FLEXITHERALIGHT<sup>®</sup> and PHOS-ISTOS<sup>®</sup> studies (median pain of 0,4/10 and 0,3/10). We found a similar tolerance to Daylight PDT<sup>29,30</sup>, with almost no pain. The FLX-PDT device allows treatment all year round, with precise control of irradiance which is not possible in Daylight PDT<sup>33</sup>. Other low-irradiance indoor PDT devices are developed, with a comparable tolerance to ours, and very good efficiency<sup>32,33</sup>. In order to improve tolerance, many other low irradiance schemes are being developed. Moreover, increasing the distance from the lamp with longer illumination time could also give good results<sup>36</sup>.

Most patients were followed-up and reassessed by a single physician, which is a bias in our study's results. In addition, the response was clinically evaluated (with the help of diagrams and photographs). No biopsy was performed to look for a potential subclinical residual dysplastic cell.

Vicentini *et al.* showed a flat light source cannot deliver a sufficient and homogeneous dose of light on a convex surface such as a scalp<sup>37</sup>. One of the advantages of a conformable textile device is that it adapts to the convexity of the scalp. One limitation is the shape of the TEXTLIGHT 1 band that is a rectangle measuring 18x20cm. Despite good conformability, it does not treat the entire surface of the skull and AK can often persist in the posterior area of the scalp. A device with a helmet (as PHOS-ISTOS<sup>®</sup> device) that covers the entire scalp should be considered. To treat limbs, circular devices or sleeves could be interesting in the future. The

light emitting fabrics is also interesting for treating areas that are difficult to illuminate, like vulvar areas (PAGETEX® protocol in Paget's vulvar disease Clinicaltrials.gov Identifier: NCT03713203).

The FLUXMEDICARE® device does not require eye protection. Unlike C-PDT, the patient can remain alone and does not need medical surveillance. The limit of this treatment is the duration of session. However, compared with the overall duration of C-PDT including a 2.5 hours of DLI, there was essentially no increase the time spent in hospital with the FLX-PDT procedure. Moreover, several studies show that the fluence required to treat AKs is probably lower, and that DLI could be reduced without loss of efficiency. So, treatment duration could be reduced<sup>16</sup> in the long term.

## **Conclusion**

Our real-life study confirms the efficacy, safety, and practical aspects of FLX-PDT with FLUXMEDICARE® device in the treatment of scalp AKs, with excellent tolerance. Good efficacy is obtained in immunocompromised patients, but larger studies are needed to confirm these results.

*Table 1 : Demographics and clinical characteristics of patients before treatment  
Values are presented as frequency (percentage) unless otherwise indicated.*

<b>Patients</b>	<b>n = 39</b>
<b>Age (years)</b>	
Mean +/- SD	75.0 ± 9.3
Range	57-92
<b>Sex</b>	
Male	38 (97.4)
Female	1 (2.6)
<b>Fitzpatrick skin phototype</b>	
I	4 (10.3)
II	28 (73.7)
III	7 (17.9)
<b>Immune status</b>	
Immunocompetent	34 (87.2)
Immunocompromised	5 (12.8)
<b>Smoking status</b>	
Active	0 (0)
Detoxed	39 (100)
<b>History of skin cancer</b>	
Basal cell carcinoma	15 (38.5)
Squamous cell carcinoma	11 (28.2)
Melanoma	8 (20.5)
Other skin cancer	3 (7.7)
<b>Previous treatments</b>	
Median (Interquartile Range)	1 (0 to 2)
Range	0 to 6
<b>Number of AK lesions</b>	
	417
Grade I	290 (69.5)
Grade II	127 (30.5)
<b>AKASI score</b>	
Median (Interquartile Range)	3.8 (2.4 to 5.6)
Range	1.6 to 11.2

Figure 1. FLUXMEDICARE® device f

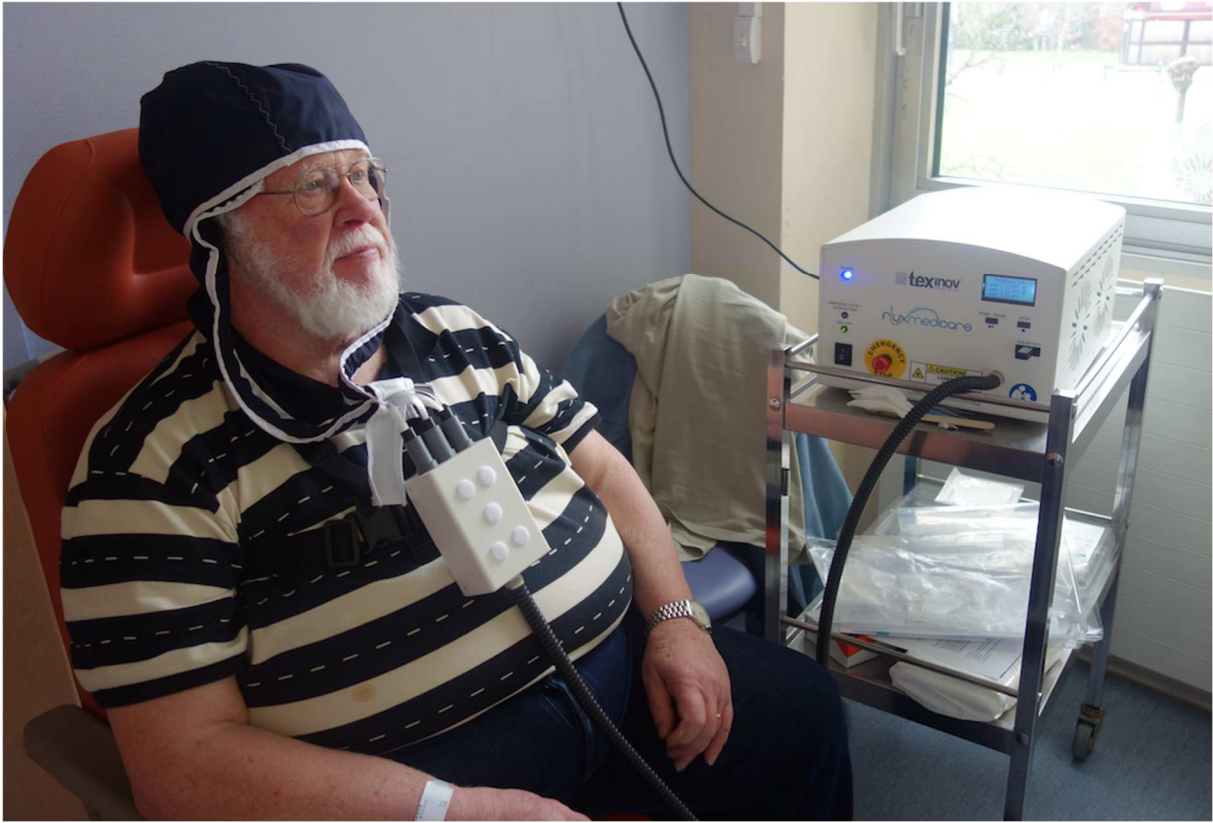

Figure 2A. FLUXMEDICARE® device (TEXTLIGHT 1)



Figure 2B. FLUXMEDICARE® device (TEXTLIGHT 3)


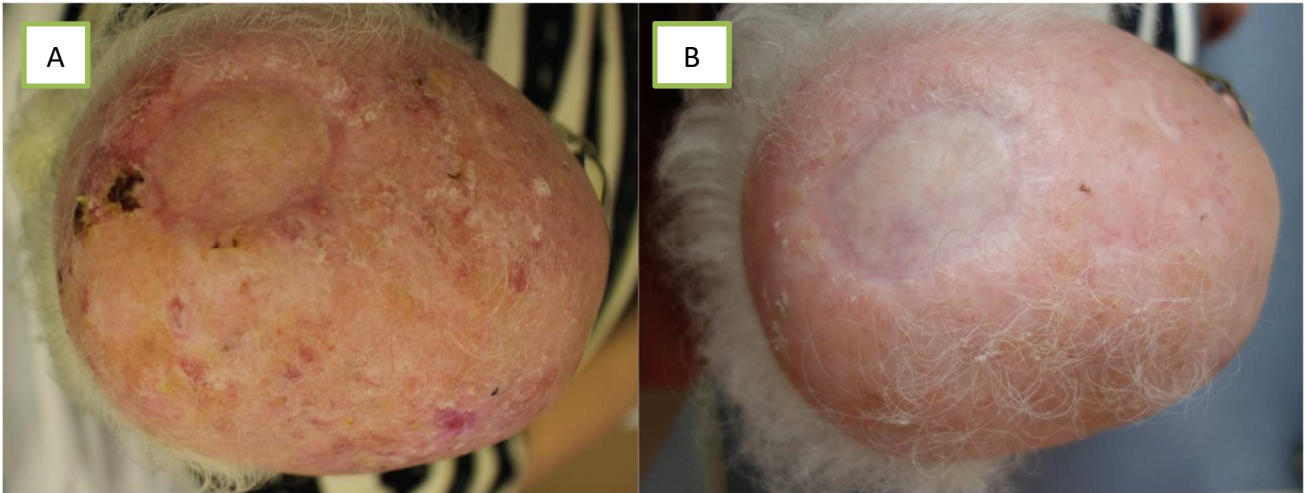


Figure 3 A. Patient before treatment B. Efficacy at 3 months



## References

1. Bernard P, Dupuy A, Sasco A, et al: Basal cell carcinomas and actinic keratoses seen in dermatological practice in France: a cross-sectional survey. *Dermatology (Basel)* 216:194–199, 2008
2. Marks R, Rennie G, Selwood TS: Malignant transformation of solar keratoses to squamous cell carcinoma. *Lancet* 1:795–797, 1988
3. Criscione VD, Weinstock MA, Naylor MF, et al: Actinic keratoses: Natural history and risk of malignant transformation in the Veterans Affairs Topical Tretinoin Chemoprevention Trial. *Cancer* 115:2523–2530, 2009
4. Fuchs A, Marmur E: The kinetics of skin cancer: progression of actinic keratosis to squamous cell carcinoma. *Dermatol Surg* 33:1099–1101, 2007
5. Jansen MHE, Kessels JPHM, Nelemans PJ, et al: Randomized Trial of Four Treatment Approaches for Actinic Keratosis. *N Engl J Med* 380:935–946, 2019
6. Steeb T, Hept MV, Becker L, et al: Long-term efficacy of interventions for actinic keratosis: protocol for a systematic review and network meta-analysis. *Syst Rev* 8:237, 2019
7. Figueras Nart I, Cerio R, Dirschka T, et al: Defining the actinic keratosis field: a literature review and discussion. *J Eur Acad Dermatol Venereol* 32:544–563, 2018
8. Torezan LAR, Festa-Neto C, Torezan LAR, et al: Cutaneous field cancerization: clinical, histopathological and therapeutic aspects. *Anais Brasileiros de Dermatologia* 88:775–786, 2013
9. Reygagne P, Rostain G: Au-delà des kératoses actiniques, le champ de cancérisation cutané. *Ann Dermatol Venereol*, 145:587-592, 2018.
10. Hofbauer GF, Anliker M, Boehncke W-H, et al: Swiss clinical practice guidelines on field cancerization of the skin. *Swiss Medical Weekly* 144, 2014.
11. Werner RN, Stockfleth E, Connolly SM, et al: Evidence- and consensus-based (S3) Guidelines for the Treatment of Actinic Keratosis - International League of Dermatological Societies in cooperation with the European Dermatology Forum - Short version. *J Eur Acad Dermatol Venereol* 29:2069–2079, 2015
12. Pariser D, Loss R, Jarratt M, et al: Topical methyl-aminolevulinate photodynamic therapy using red light-emitting diode light for treatment of multiple actinic keratoses: A randomized, double-blind, placebo-controlled study. *J Am Acad Dermatol* 59:569–576, 2008
13. Szeimies R-M, Matheson RT, Davis SA, et al: Topical methyl aminolevulinate photodynamic therapy using red light-emitting diode light for multiple actinic keratoses: a randomized study. *Dermatol Surg* 35:586–592, 2009
14. Morton C, Campbell S, Gupta G, et al: Intraindividual, right-left comparison of topical methyl aminolaevulinate-photodynamic therapy and cryotherapy in subjects with actinic keratoses: a multicentre, randomized controlled study. *Br J Dermatol* 155:1029–1036, 2006
15. Ang JM, Riaz IB, Kamal MU, et al: Photodynamic therapy and pain: A systematic review. *Photodiagnosis Photodyn Ther* 19:308–344, 2017
16. Mordon S: Painless and efficient ALA-PDT and MAL-PDT of Actinic Keratosis can be achieved by drastically reducing the Drug-Light Interval (DLI). *Dermatol Ther* e13423, 2020
17. Vicentini C, Vignion-Dewalle AS, Thecua E, et al: Photodynamic therapy for actinic keratosis of the forehead and scalp: a randomized, controlled, phase II clinical study evaluating the noninferiority of a new protocol involving irradiation with a light-emitting, fabric-based device (the Flexitheralight protocol) compared with the conventional protocol involving irradiation with the Aktelite CL 128 lamp. *Br J Dermatol* 180:765–773, 2019
18. Mordon S, Vignion-Dewalle AS, Abi-Rached H, et al: The conventional protocol versus a



protocol including illumination with a fabric-based biophotonic device (the Phosistos protocol) in photodynamic therapy for actinic keratosis: a randomized, controlled, non-inferiority clinical study. *Br J Dermatol*, 182(1):76-84, 2020

19. Olsen EA, Abernethy ML, Kulp-Shorten C, et al: A double-blind, vehicle-controlled study evaluating masoprocol cream in the treatment of actinic keratoses on the head and neck. *J Am Acad Dermatol* 24:738–743, 1991
20. Dirschka T, Pellacani G, Micali G, et al: A proposed scoring system for assessing the severity of actinic keratosis on the head: actinic keratosis area and severity index. *J Eur Acad Dermatol Venereol* 31:1295–1302, 2017
21. Schmitz L, von Dobbeler C, Gupta G, et al: Photodynamic therapy leads to significant improvement of actinic keratosis area and severity index (AKASI). *Photodiagnosis Photodyn Ther* 21:66–70, 2018
22. Haute Autorité de Santé: Liste d'échelles validées pour mesurer la douleur., 2019
23. U.S. DEPARTMENT OF HEALTH AND HUMAN SERVICES: Common Terminology Criteria for Adverse Events (CTCAE) Version 5.0, 2017
24. Sotiriou E, Evangelou G, Papadavid E, et al: Conventional vs. daylight photodynamic therapy for patients with actinic keratosis on face and scalp: 12-month follow-up results of a randomized, intra-individual comparative analysis. *J Eur Acad Dermatol Venereol* 32:595–600, 2018
25. Tschen EH, Wong DS, Pariser DM, et al: Photodynamic therapy using aminolaevulinic acid for patients with nonhyperkeratotic actinic keratoses of the face and scalp: phase IV multicentre clinical trial with 12-month follow up. *Br J Dermatol* 155:1262–1269, 2006
26. Perrett CM, McGregor JM, Warwick J, et al: Treatment of post-transplant premalignant skin disease: a randomized inpatient comparative study of 5-fluorouracil cream and topical photodynamic therapy. *Br J Dermatol* 156:320–328, 2007
27. Togsverd-Bo K, Halldin C, Sandberg C, et al: Photodynamic therapy is more effective than imiquimod for actinic keratosis in organ transplant recipients: a randomized intraindividual controlled trial. *Br J Dermatol* 178:903–909, 2018
28. Wiegell SR, Haedersdal M, Philipsen PA, et al: Continuous activation of PpIX by daylight is as effective as and less painful than conventional photodynamic therapy for actinic keratoses; a randomized, controlled, single-blinded study. *Br J Dermatol* 158:740–746, 2008
29. Szeimies RM, Karrer S, Radakovic-Fijan S, et al: Photodynamic therapy using topical methyl 5-aminolevulinate compared with cryotherapy for actinic keratosis: A prospective, randomized study. *Journal of the American Academy of Dermatology* 47:258–262, 2002
30. Pariser DM, Lowe NJ, Stewart DM, et al: Photodynamic therapy with topical methyl aminolevulinate for actinic keratosis: Results of a prospective randomized multicenter trial. *Journal of the American Academy of Dermatology* 48:227–232, 2003
31. Wiegell SR, Wulf HC, Szeimies R-M, et al: Daylight photodynamic therapy for actinic keratosis: an international consensus: International Society for Photodynamic Therapy in Dermatology. *J Eur Acad Dermatol Venereol* 26:673–679, 2012
32. Wiegell SR, Fabricius S, Gniadecka M, et al: Daylight-mediated photodynamic therapy of moderate to thick actinic keratoses of the face and scalp: a randomized multicentre study. *Br J Dermatol* 166:1327–1332, 2012
33. Wiegell SR, Fabricius S, Heydenreich J, et al: Weather conditions and daylight-mediated photodynamic therapy: protoporphyrin IX-weighted daylight doses measured in six geographical locations. *Br J Dermatol* 168:186–191, 2013
34. Maire C, Vignion-Dewalle AS, Cartier H, et al: Artificial white light photodynamic therapy for

actinic keratosis: a study of 38 patients in private office practice. *J Eur Acad Dermatol Venereol* 34:e165–e167, 2020

**35.** Mordon S, Vignion-Dewalle AS, Thecu E, et al: Can daylight-PDT be performed indoor? *G Ital Dermatol Venereol* 153:811–816, 2018

**36.** Martin GM: In-office Painless Aminolevulinic Acid Photodynamic Therapy. *J Clin Aesthet Dermatol* 9:19–26, 2016

**37.** Vicentini C, Tylcz J-B, Maire C, et al: Évaluation de la dose de lumière délivrée au cours du traitement de kératoses actiniques du scalp par photothérapie dynamique. *Annales de Dermatologie et de Vénérologie* 142:S599–S600, 2015