



**HAL**  
open science

## Targeting CCR4 with mogamulizumab in refractory CD3-CD4 + lymphocytic-variant hypereosinophilic syndrome.

Emmanuel Ledoult, Matthieu Groh, Bertrand Meresse, Romain Dubois, Jacques Trauet, E. Toussaint, Marie Delbeke, Eric Hachulla, Louis Terriou, A. de Masson, et al.

### ► To cite this version:

Emmanuel Ledoult, Matthieu Groh, Bertrand Meresse, Romain Dubois, Jacques Trauet, et al.. Targeting CCR4 with mogamulizumab in refractory CD3-CD4 + lymphocytic-variant hypereosinophilic syndrome.. *Haematologica*, 2024, *Haematologica*, 109 (6), pp.1984-1988. 10.3324/haematol.2023.284429 . hal-04601580

**HAL Id: hal-04601580**

**<https://hal.univ-lille.fr/hal-04601580>**

Submitted on 5 Jun 2024

**HAL** is a multi-disciplinary open access archive for the deposit and dissemination of scientific research documents, whether they are published or not. The documents may come from teaching and research institutions in France or abroad, or from public or private research centers.

L'archive ouverte pluridisciplinaire **HAL**, est destinée au dépôt et à la diffusion de documents scientifiques de niveau recherche, publiés ou non, émanant des établissements d'enseignement et de recherche français ou étrangers, des laboratoires publics ou privés.



Distributed under a Creative Commons Attribution - NonCommercial 4.0 International License

# Targeting CCR4 with mogamulizumab in refractory CD3<sup>-</sup>CD4<sup>+</sup> lymphocytic-variant hypereosinophilic syndrome

Lymphocytic-variant hypereosinophilic syndrome (L-HES) is an indolent T-cell lymphoproliferative disorder characterized by chronic blood hypereosinophilia and eosinophil-related organ damage<sup>1,2</sup> secondary to the production of eosinophilopoietic cytokines (including interleukin-5 [IL-5]) by clonal T cells, among which CD3<sup>-</sup>CD4<sup>+</sup> T cells are the most frequent subset.<sup>3,4</sup> L-HES is usually sensitive to oral corticosteroids (OCS), but high maintenance doses are frequently required. OCS-sparing treatment (including mepolizumab) has variable often transient efficacy.<sup>1,3,5,6</sup> Moreover, up to 5% to 10% of L-HES patients will ultimately develop an angioimmunoblastic T-cell lymphoma (AITL).<sup>3,7</sup> Overall, both high OCS exposure, failure and/or toxicity of OCS-sparing therapies and the risk of progression to AITL underscore the unmet need for novel treatments targeting clonal T cells and not only eosinophils. We previously reported that peripheral CD3<sup>-</sup>CD4<sup>+</sup> T cells express C-C chemokine receptor 4 (CCR4).<sup>8</sup> Here, we first report on the use of off-label mogamulizumab, a defucosylated monoclonal antibody targeting CCR4-positive cells through antibody-dependent cellular cytotoxicity<sup>9,10</sup> in refractory L-HES.

We assessed expression of CCR4 by clonal CD3<sup>-</sup>CD4<sup>+</sup> T cells in the skin and lymph nodes i.e., the two main organs involved in L-HES. We found significant CCR4 expression on tissue CD4<sup>+</sup> T cells (Figure 1A). We then confirmed the ability of mogamulizumab to induce antibody-dependent cellular cytotoxicity (ADCC) *in vitro* on sorted CD3<sup>-</sup>CD4<sup>+</sup> T cells from two L-HES patients, using homologous sorted natural killer (NK) cells as effector cells. As expected, NK cells induced the lysis of CD3<sup>-</sup>CD4<sup>+</sup> T cells coated with mogamulizumab (10 µg/mL) (Figure 1B). We then treated four refractory L-HES patients with off-label mogamulizumab, administered intravenously at 1.0 mg/kg weekly for the first 28-day cycle, then on days 1 and 15 of subsequent cycles. Blood response was defined as complete if the subset of CD3<sup>-</sup>CD4<sup>+</sup> T cells was <0.5% of all lymphocytes, or as partial if the number of CD3<sup>-</sup>CD4<sup>+</sup> T cells decreased by >50% without reaching complete response at the time of the last perfusion. Patients provided informed consent before receiving mogamulizumab as off-label treatment. Data were retrospectively collected from the French registry LYMPHEO (clinical and pathological characteristics of patients with LYMPHocyte-variant HyperEOsinophilic syndrome). As provided by the French legislation on the use of health data, the four patients were informed by their referring physician about the possibility of using their data and none objected. This study was conducted in accordance

with the Declaration of Helsinki and was approved by an Ethics Committee (IRB00012437).

Case #1 was a 60-year-old female complaining of severe refractory pruritus despite treatment with OCS and pegylated interferon  $\alpha$  (pINF- $\alpha$ ) (Table 1). Mogamulizumab was administered for 20 infusions and stopped after sustained response was achieved. Blood response was complete (CD3<sup>-</sup>CD4<sup>+</sup>: 0.003x10<sup>9</sup>/L vs. 4.624x10<sup>9</sup>/L at baseline) with no eosinophilia. Six months after stopping mogamulizumab, she was asymptomatic under 5 mg/day of OCS. Nevertheless, a clinical relapse occurred, preceded by an increase in T-cell clone size and absolute eosinophil count (AEC). She was successfully treated by another short course of 4 weekly infusions of mogamulizumab. No clinical relapse has been reported since then with 12 months of follow-up.

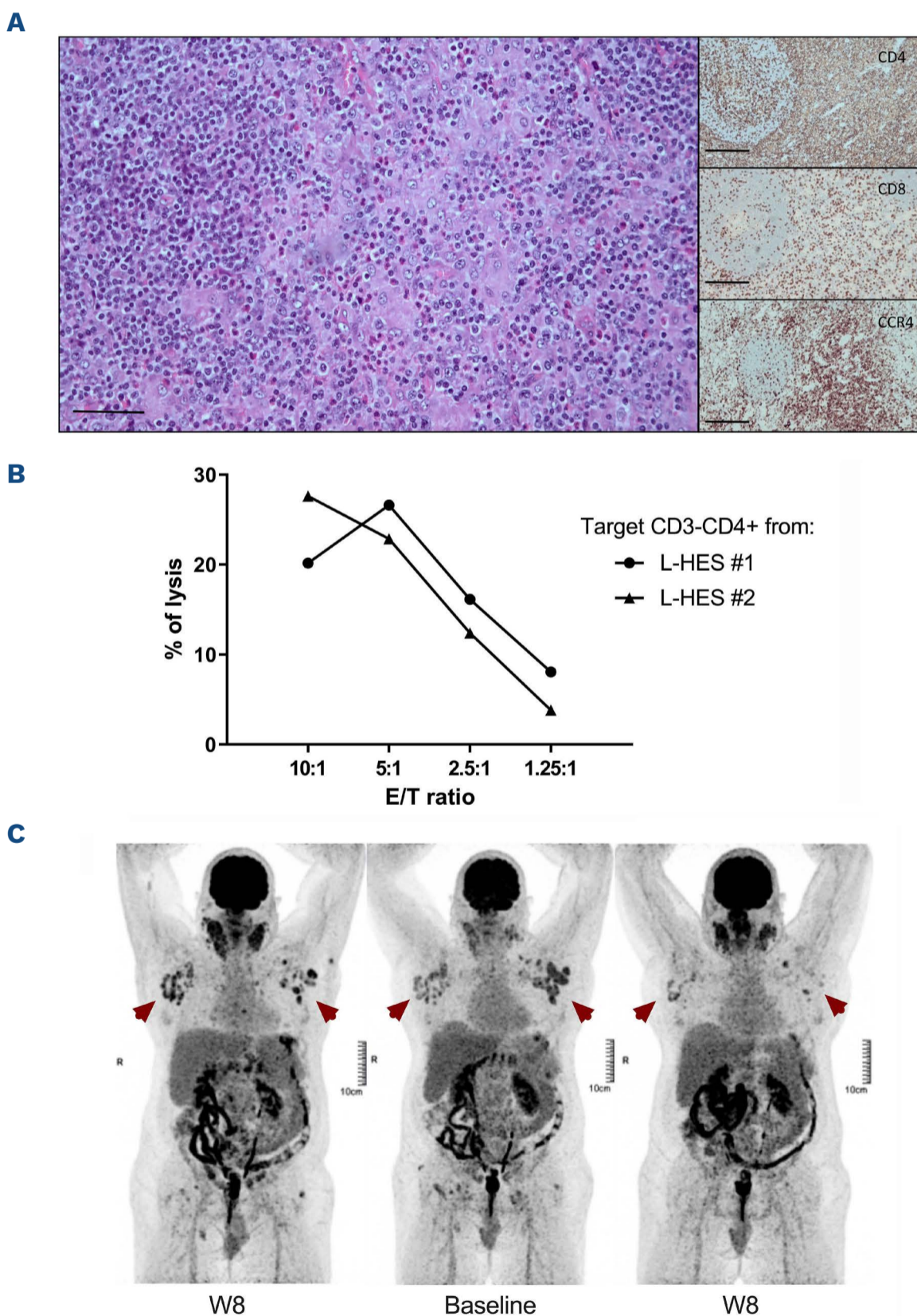
Case #2 was a 59-year-old male complaining of refractory pruritus and enlarged lymph nodes despite treatment with OCS and pINF- $\alpha$ . Lymph node biopsy showed an infiltration by CCR4<sup>+</sup>CD4<sup>+</sup> T cells without features of AITL. Eight weeks after starting mogamulizumab, positron emission tomography/computed tomography showed an improvement of lymph node enlargement (Figure 1C). After 27 perfusions, blood response was partial (CD3<sup>-</sup>CD4<sup>+</sup>: 0.050x10<sup>9</sup>/L vs. 0.336x10<sup>9</sup>/L at baseline) without eosinophilia. While remaining asymptomatic on low-dose OCS, grade 3 CD3<sup>+</sup>CD4<sup>+</sup> lymphopenia (yet without opportunistic infection) was reported. Mogamulizumab was discontinued due to personal convenience and no relapse has been reported since then with 12 months of follow-up.

Case #3 was a 41-year-old female presenting with pruritus, episodic angioedema, and enlarged lymph nodes. Mogamulizumab was initiated due to persistent episodic angioedema and a rapid increase of both CD3<sup>-</sup>CD4<sup>+</sup> T cells (up to 1.824x10<sup>9</sup>/L) and eosinophils (7.8x10<sup>9</sup>/L), despite treatment with both OCS and pINF- $\alpha$ . Mogamulizumab was discontinued after the seventh infusion due to recurrent grade 2 infusion-related systemic reactions. Blood response was complete (CD3<sup>-</sup>CD4<sup>+</sup>: 0.006x10<sup>9</sup>/L vs. 1.824x10<sup>9</sup>/L at baseline) with persistent moderate eosinophilia (1.0x10<sup>9</sup>/L). Grade 3 CD3<sup>+</sup>CD4<sup>+</sup> lymphopenia was reported with no opportunistic infection during follow-up. She remained asymptomatic (yet with persistent moderate eosinophilia) during the next 18 months, yet a relapse ultimately occurred preceded by an increase of both T-cell clone size and AEC.

Case #4 was a 47-year-old female complaining of chronic refractory urticaria and arthralgia. Seven years after

disease onset, she complained of erythroderma accompanied by skin ulcerations, lymph node enlargement and a drastic increase in the number of CD3<sup>+</sup>CD4<sup>+</sup> T cells (up to  $55.586 \times 10^9/L$ ). Clonal T cells were found in both skin and lymph node biopsies yet without signs of AITL. Mogamulizumab was started with OCS. Two hours after the second infusion, she was admitted to the intensive care unit for acute respiratory distress. Bronchoalveolar lavage showed mixed eosinophilic and lymphocytic (including 70% of CD3<sup>+</sup>CD4<sup>+</sup> T cells:  $1.332 \times 10^9/L$ ) alveolitis. AEC increased to  $15.0 \times 10^9/L$  and the serum level of IL-5 was high (162.0 pg/mL; normal range, 0.1-0.6). She received high-dose steroids and antibiotics, and her condition improved. Meanwhile, the CD3<sup>+</sup>CD4<sup>+</sup> T-cell count sharply plummeted to  $10.780 \times 10^9/L$  within a few days.

Nevertheless, lymph node enlargement increased, and erythroderma worsened over the following weeks. Mogamulizumab was resumed at a lower dose (1/10), with good tolerance and efficiency. After the fourth infusion, blood response was partial (CD3<sup>+</sup>CD4<sup>+</sup>:  $9.035 \times 10^9/L$  vs.  $55.586 \times 10^9/L$  at baseline) with moderate eosinophilia ( $0.7 \times 10^9/L$ ). Unfortunately, the following weeks were marked by multiple severe infectious events which delayed the mogamulizumab infusions. Despite initial improvement, erythroderma further worsened, an increase of clonal T cells was evidenced and mogamulizumab was ultimately withdrawn due to these adverse events (AE). Grade 3 CD3<sup>+</sup>CD4<sup>+</sup> lymphopenia was also reported. Overall, blood responses (complete, N=2 or partial, N=2) and a decrease in AEC were reported in all cases (Figure 2).



**Figure 1. Histologic findings, antibody-dependent cellular cytotoxicity results, and lymph node response to mogamulizumab.** (A) Lymph node biopsy showing a benign infiltration of CCR4<sup>+</sup>CD4<sup>+</sup> T cells. Left: hematoxylin and eosin staining x400 magnification, scale bar=50  $\mu$ m. Right: immunostaining x100 magnification, scale bar=200  $\mu$ m, anti-CD4 (upper panel), anti-CD8 (middle panel) and anti-CCR4 (lower panel). (B) Ability of mogamulizumab to induce antibody-dependent cellular cytotoxicity (ADCC) on sorting CD3<sup>+</sup>CD4<sup>+</sup> T cells by conducting an ADCC *in vitro* assay in 2 lymphocytic-variant hypereosinophilic syndrome (L-HES) patients using sorted CD3<sup>+</sup>CD4<sup>+</sup> T cells as targeted cells (T) and homologous sorted natural killer (NK) cells as effector cells (E). NK cells kill CD3<sup>+</sup>CD4<sup>+</sup> T cells coated with mogamulizumab (10  $\mu$ g/mL) in a dose-dependent manner. No significant lysis was observed without mogamulizumab (*data not shown*). (C) Positron emission tomography/computed tomography scan showing a large lymph node enlargement (arrows) in case #2: 8 weeks (W8) before starting mogamulizumab (left), at baseline (middle) and W8 after treatment onset (right). E/T: effector/target ratio.

In terms of clinical response, two patients experienced lymph node enlargement, which subsequently improved rapidly. Despite substantial tapering in OCS doses, all cases showed clinical response. Although prolonged blood and clinical responses have been observed after discontinuation of mogamulizumab, relapses still occurred suggesting that mogamulizumab has a suspensive effect. In terms of safety, mogamulizumab was discontinued in two patients due to AE. CD3<sup>+</sup>CD4<sup>+</sup> T-cell lymphopenia was reported in three of four cases but was pre-existing in three cases. Safety profile was in line with published data in patients treated with mogamulizumab for mycosis fungoides.<sup>12</sup> Here, infectious events were reported in case 4, who otherwise had additional risk factors for infection e.g., treatment with high doses of OCS and multiple skin ulcerations. She also presented a serious AE related to tumor lysis syndrome (likely triggered by NK-mediated ADCC induced by mogamulizumab) leading to the massive release of IL-5 and subsequent rebound of AEC. Hence lower doses of mogamulizumab, transient use of OCS and/or mepolizumab should be considered in future patients with very high number of CD3<sup>+</sup>CD4<sup>+</sup> T

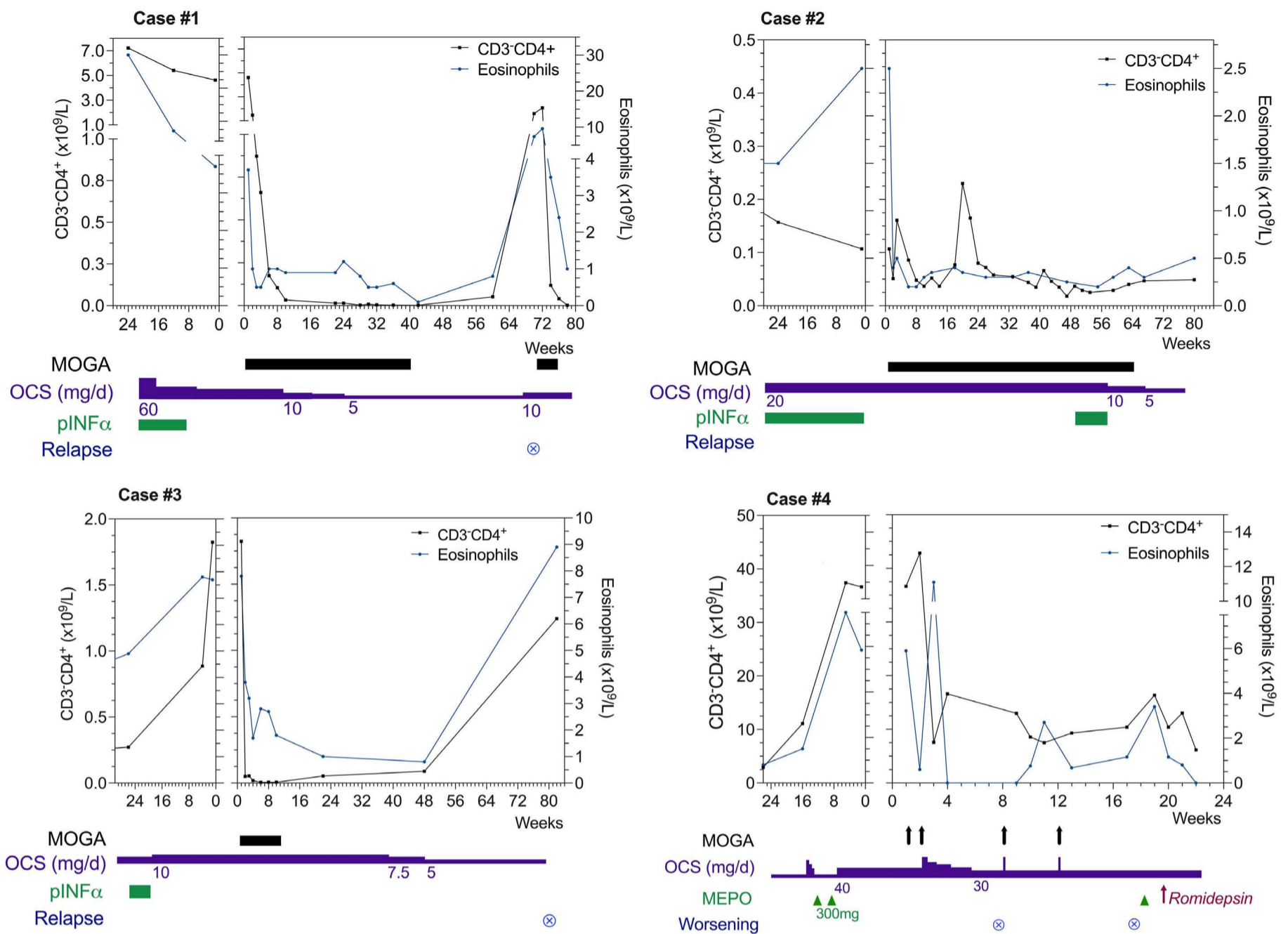
cells which are about to start mogamulizumab.

Overall, we suggest that in L-HES patients the first OCS-sparing agent should remain pINF- $\alpha$  (i.e., the drug with the most available evidence; starting with a low weekly dose to improve tolerability)<sup>11,12</sup> or mepolizumab (i.e., the only drug licensed in *FIP1L1::PDGFRA*-negative HES; 300 mg subcutaneously every 4 weeks),<sup>6,13,14</sup> bearing in mind that failures have been reported with both drugs and that comparative data are lacking. Janus kinase inhibitors are other promising therapies for treating HES-related symptoms.<sup>15</sup> Bearing in mind the risk of both tumoral lysis syndrome and infections (as well as the fact that relapses may occur after discontinuation of the drug), mogamulizumab represents a new therapeutic option for the subgroup of patients with severe multi refractory-treatment disease, especially with clonal T-cell-related symptoms or earlier in cases of significant tumor syndrome and/or large or rapidly increasing clonal T-cell count. In patients who achieve complete remission under mogamulizumab, whether fix or on-demand (e.g., tailored by circulating CD3<sup>+</sup>CD4<sup>+</sup> T cells and/or AEC maintenance infusions could be beneficial to prevent

**Table 1.** Patient baseline characteristics at the time of refractory lymphocytic-variant hypereosinophilic syndrome diagnostic.

Case	Sex	Age in years	AEC x10 <sup>9</sup> /L	CD3 <sup>+</sup> CD4 <sup>+</sup> cells, % (x10 <sup>9</sup> /L)	TCR rear.	NGS <sup>#</sup>	Biopsy <sup>*</sup>	Organ involvement	Drugs received
#1	F	60	30.0	67.0 (4.624)	+	<i>STAT1</i> exon 17 c.1360C>G: p.P454A (VAF 5%)	Skin	Pruritus	OCS pINF- $\alpha$
#2	M	59	2.0	30.7 (0.336)	+	<i>DNMT3A</i> exon 15 c.1814T>C: p.L605P (VAF 1.41%)	Lymph node	Pruritus Lymph node enlargement Splénomegaly	OCS pINF- $\alpha$
#3	F	41	18.0	15.1 (0.231)	+	No mutation	Lymph node	Episodic angioedema Pruritus Lymph node enlargement Splénomegaly	OCS pINF- $\alpha$
#4	F	47	1.5	61.0 (1.921)	+	<i>DNMT3A</i> exon 14 c.1667+1G>A (VAF 2%) <i>DNMT3A</i> exon 22 c.2578T>C: p.W860R (VAF 2%) <i>SMC1A</i> exon 4 c.571A>T: p.N191Y (VAF 56%)	Skin Medullar Lymph node BAL	Urticaria Erythroderma Skin ulceration Arthralgia Lymph node enlargement Splénomegaly Interstitial lung disease	OCS pINF- $\alpha$ Omalizumab Mepolizumab

<sup>#</sup>Next generation sequencing (NGS) panel: *ABL1, ANKRD26, ARID1A, ASXL1, ASXL2, ATM, ATRX, B2M, BAX, BCL2, BCOR, BCORL1, BIRC3, BRAF, BRCA1, BRCA2, BTK, CALR, CARD11, CBL, CCND1, CD274, CD28, CD58, CD79A, CD79B, CDKN2A, CEBPA, CHEK2, CIITA, CREBBP, CRLF2, CSF2RA, CSF2RB, CSF3R, CUX1, CXCR4, DDX3X, DDX41, DHX15, DHX34, DNMT3A, EGR2, EP300, ETNK1, ETV6, EZH2, FBXW7, FGFR1, FLT3, FOXO1, GATA1, GATA2, GNA13, GNAS, GNB1, HRAS, ID3, IDH1, IDH2, IKZF1, IL2RG, IL3RA, IL5RA, IL7R, IRF4, ITPKB, JAK1, JAK2, JAK3, KDM6A, KIT, KLF2, KMT2A, KMT2D, KRAS, LUC7L2, MAP2K1, MAP3K14, MBD4, MEF2B, MPL, MSC, MYC, MYD88, NF1, NFE2, NIPBL, NOTCH1, NOTCH2, NPM1, NRAS, NSD2, PAX5, PDGFRA, PDGFRB, PHF6, PIGA, PIM1, PLCG1, PLCG2, PPM1D, PRDM1, PRPF8, PTEN, PTPN11, PTPRD, RAD21, RB1, RHOA, RIT1, RPS15, RUNX1, SAMD9, SAMD9L, SETBP1, SETD2, SF3B1, SH2B3, SMC1A, SMC3, SOCS1, SPI1, SRP72, SRSF2, STAG2, STAT1, STAT3, STAT5A, STAT5B, STAT6, TBL1XR1, TCF3, TCL1A, TERC, TERT, TET2, TNFAIP3, TNFRSF14, TP53, TYK2, U2AF1, UBA1, UBTF, VAV1, WT1, XPO1, ZBTB7A, ZRSR2. <sup>\*</sup>All biopsies showed an infiltration of eosinophils and CCR4<sup>+</sup>CD4<sup>+</sup> T cells. AEC: absolute eosinophil count; BAL: bronchoalveolar lavage; F: female; pINF- $\alpha$ : pegylated-interferon  $\alpha$ ; M: male; OCS: oral corticosteroids; TCR rear.: clonal T-cell receptor rearrangement in blood; VAF: variant allele frequency.*



**Figure 2. Hematological response to mogamulizumab in four refractory lymphocytic-variant hyper eosinophilic syndrome patients.** pINF- $\alpha$ : pegylated interferon  $\alpha$ ; MEPO: mepolizumab; MOGA: mogamulizumab; OCS: oral corticosteroids, d: day.

relapses and transformation to high-grade lymphoma remains to be investigated.

## Authors

Emmanuel Ledoult<sup>1,2</sup>, Matthieu Groh<sup>2,3</sup>, Bertrand Meresse,<sup>2</sup> Romain Dubois,<sup>4</sup> Jacques Trauet,<sup>2,5</sup> Elise Toussaint,<sup>6</sup> Marie Delbeke,<sup>2</sup> Eric Hachulla,<sup>1,2</sup> Louis Terriou,<sup>1</sup> Adèle De Masson,<sup>7</sup> Michele Vasseur,<sup>8</sup> Myriam Labalette,<sup>2,5</sup> David Launay,<sup>1,2</sup> Jean-Emmanuel Kahn<sup>9</sup> and Guillaume Lefevre<sup>1,2,5</sup>

<sup>1</sup>Service de Médecine Interne et d'Immunologie Clinique, Centre de Référence des Syndromes Hyperéosinophiliques (CEREO), CHU Lille, Lille; <sup>2</sup>INFINITE - Institute for Translational Research in Inflammation, Université de Lille, Lille; <sup>3</sup>Service de Médecine Interne, Centre de Référence des Syndromes Hyperéosinophiliques (CEREO), Hôpital Foch, Suresnes; <sup>4</sup>Institut de Pathologie, CHU Lille, Lille; <sup>5</sup>Laboratoire d'Immunologie, CHU Lille, Lille; <sup>6</sup>Service d'Hématologie, Institut de Cancérologie

Strasbourg Europe, Strasbourg; <sup>7</sup>INSERM U976, Service de Dermatologie, Hôpital Saint-Louis, Paris; <sup>8</sup>Pharmacie Centrale, CHU Lille, Lille and <sup>9</sup>Université Paris Saclay, Service de Médecine Interne, Hôpital Ambroise Paré, APHP, Boulogne Billancourt, France

Correspondence:

E. LEDOULT - emmanuel.ledoult2@chu-lille.fr

<https://doi.org/10.3324/haematol.2023.284429>

Received: October 9, 2023.

Accepted: January 31, 2024.

Early view: February 8, 2024.

©2024 Ferrata Storti Foundation

Published under a CC BY-NC license

## Disclosures

No conflicts of interest to disclose.

**Contributions**

EL, MG, J-EK and GL designed the research and wrote the paper. BM and MD performed ADCC *in vitro* assay. RD analyzed tissues from the patient. JT performed flow cytometry phenotyping. EL, MG, ET, EH, LT, AD, MV, ML, DL, J-EK and GL collected and

analyzed data. EL made the figures.

**Data-sharing statement**

For original data, please contact the corresponding author.

**References**

---

1. Lefèvre G, Copin M-C, Staumont-Sallé D, et al. The lymphoid variant of hypereosinophilic syndrome: study of 21 patients with CD3-CD4+ aberrant T-cell phenotype. *Medicine (Baltimore)*. 2014;93(17):255-266.
2. Valent P, Klion AD, Roufosse F, et al. Proposed refined diagnostic criteria and classification of eosinophil disorders and related syndromes. *Allergy*. 2023;78(1):47-59.
3. Carpentier C, Verbanck S, Schandené L, et al. Eosinophilia associated with CD3-CD4+ T cells: characterization and outcome of a single-center cohort of 26 patients. *Front Immunol*. 2020;11:1765.
4. Shi Y, Wang C. What we have learned about lymphocytic variant hypereosinophilic syndrome: a systematic literature review. *Clin Immunol*. 2022;237:108982.
5. Lefevre G, Copin MC, Roumier C, Aubert H, 2015. CD3-CD4+ lymphoid variant of hypereosinophilic syndrome: nodal and extranodal histopathological and immunophenotypic features of a peripheral indolent clonal T-cell lymphoproliferative disorder. *Haematologica*. 2015;100(8):1086-1095.
6. Kuang FL, Fay MP, Ware J, et al. Long-term clinical outcomes of high-dose mepolizumab treatment for hypereosinophilic syndrome. *J Allergy Clin Immunol Pract*. 2018;6(5):1518-1527.
7. Roufosse F, Leval L de, Krieken H van, Deuren M van. Lymphocytic variant hypereosinophilic syndrome progressing to angioimmunoblastic T-cell lymphoma. *Leuk Lymphoma*. 2015;56(6):1891-1894.
8. Ledoult E, Groh M, Kahn JE, et al. Assessment of T-cell polarization on the basis of surface marker expression: diagnosis and potential therapeutic implications in lymphocytic variant hypereosinophilic syndrome. *J Allergy Clin Immunol Pract*. 2019;8(3):1110-1114.
9. Kim YH, Bagot M, Pinter-Brown L, et al. Mogamulizumab versus vorinostat in previously treated cutaneous T-cell lymphoma (MAVORIC): an international, open-label, randomised, controlled phase 3 trial. *Lancet Oncol*. 2018;19(9):1192-1204.
10. Beylot-Barry M, Quereux G, Nardin C, et al. Effectiveness of mogamulizumab in patients with Mycosis Fungoides or Sézary syndrome: a multicentre, retrospective, real-world French study. *J Eur Acad Dermatol Venereol*. 2023;37(9):1777-1784.
11. Choi C, Moller D, Tan J, et al. Pegylated interferon alpha 2a is an effective and well-tolerated treatment option for lymphocyte-variant hypereosinophilic syndrome. *Br J Haematol*. 2020;188(5):e68-72.
12. Groh M, Rohmer J, Etienne N, et al. French guidelines for the etiological workup of eosinophilia and the management of hypereosinophilic syndromes. *Orphanet J Rare Dis*. 2023;18(1):100.
13. Roufosse F, Lavarelle A de, Schandené L, et al. Mepolizumab as a corticosteroid-sparing agent in lymphocytic variant hypereosinophilic syndrome. *J Allergy Clin Immunol*. 2010;126(4):828-835.
14. Rothenberg ME, Klion AD, Roufosse FE, et al. Treatment of patients with the hypereosinophilic syndrome with mepolizumab. *N Engl J Med*. 2008;358(12):1215-1228.
15. Faguer S, Groh M, Vergez F, et al. JAK inhibition for CD3- CD4+ lymphocytic-variant hypereosinophilic syndrome. *Clin Immunol*. 2023;251:109275.