



HAL
open science

Efficacy and safety of mammalian target of rapamycin inhibitors in systemic mastocytosis: A nationwide French pilot study.

Josquin Moraly, Julien Rossignol, Claire Rouzaud, Thomas Gabas, Hassiba Bouktit, Ludovic Lhermitte, Danielle Canioni, Sylvie Fraitag, Julie Bruneau, Stephane Barete, et al.

► To cite this version:

Josquin Moraly, Julien Rossignol, Claire Rouzaud, Thomas Gabas, Hassiba Bouktit, et al.. Efficacy and safety of mammalian target of rapamycin inhibitors in systemic mastocytosis: A nationwide French pilot study.. American Journal of Hematology, 2024, American Journal of Hematology, 99 (6), pp.1095-1102. 10.1002/ajh.27323 . hal-04691823

HAL Id: hal-04691823

<https://hal.univ-lille.fr/hal-04691823v1>

Submitted on 9 Sep 2024

HAL is a multi-disciplinary open access archive for the deposit and dissemination of scientific research documents, whether they are published or not. The documents may come from teaching and research institutions in France or abroad, or from public or private research centers.

L'archive ouverte pluridisciplinaire **HAL**, est destinée au dépôt et à la diffusion de documents scientifiques de niveau recherche, publiés ou non, émanant des établissements d'enseignement et de recherche français ou étrangers, des laboratoires publics ou privés.



Distributed under a Creative Commons Attribution - NonCommercial - NoDerivatives 4.0 International License

RESEARCH ARTICLE

Efficacy and safety of mammalian target of rapamycin inhibitors in systemic mastocytosis: A nationwide French pilot study

Josquin Moraly^{1,2}  | Julien Rossignol^{2,3,4} | Claire Rouzaud¹ | Thomas Gabas¹ | Hassiba Bouktit² | Ludovic Lhermitte^{2,5} | Danielle Canoni^{2,6} | Sylvie Fraitag^{2,6} | Julie Bruneau⁷ | Stéphane Barete⁸ | Felipe Suarez⁴ | Thomas Ballul^{2,3,4} | Cécile Meni^{2,9} | Laura Polivka^{2,3,9} | Louis Terriou¹⁰ | David Launay¹⁰ | Laurence Bouillet¹¹ | Caroline Gaudy-Marqueste¹² | Marie Gousseff¹³  | Edwige Le Mouel¹⁴ | Antoine Neel¹⁵ | Dana Ranta¹⁶ | Roland Jaussaud¹⁷ | Philippe Guilpain¹⁸ | Laurent Frenzel^{2,3,4} | Julie Agopian¹⁹ | Patrice Dubreuil¹⁹ | Céline Greco^{2,20} | Sophie Dimicoli-Salazar²¹ | Mael Heiblig²² | Clément Gourguechon²³ | Olivier Tournilhac²⁴ | Rose-Marie Javier²⁵ | Florence Castelain²⁶  | Quentin Cabrera²⁷ | Marie Pierre Gourin²⁸ | Ewa Wierzbicka-Hainaut²⁹ | Jose Miguel Torregrosa-Diaz³⁰ | Cristina Bulai³¹ | Christian Lavigne³²  | Cyrille Hoarau³³ | Michel Arock³⁴ | Gandhi Damaj³⁵  | Olivier Lortholary^{1,2} | Olivier Hermine^{2,3,4} | on behalf the CEREMAST network

Correspondence

Julien Rossignol, CEREMAST, Necker Hospital,
149 Rue de Sevres, F-75015, Paris, France.
Email: julien.rossignol@aphp.fr

Abstract

Systemic mastocytosis (SM) corresponds to a rare and heterogeneous spectrum of diseases characterized by the accumulation of atypical mast cells (MCs). Advanced mastocytosis (Adv-SM) is associated with poor survival; in contrast, patients with non-advanced SM (non-Adv-SM) usually have a normal life expectancy but may experience poor quality of life. Despite recent therapeutic progress including tyrosine kinase inhibitors, new treatment options are needed for refractory and/or intolerant patients with both severely symptomatic and Adv-SM. In vitro, the mTOR pathway is activated in MCs from patients bearing the *KIT* D816V mutation. Furthermore, rapamycin induces the apoptosis of *KIT* D816V MCs selectively. In this nationwide study, we report the outcomes of patients diagnosed with SM and treated with a mammalian target of rapamycin inhibitor (imTOR) within the French National Reference

Abbreviations: ASM, aggressive systemic mastocytosis; CMML, chronic myelomonocytic leukemia; imTOR, mTOR pathway inhibitor; ISM, indolent systemic mastocytosis; MC, mast cell; MCL, mast cell leukemia; MDS, myelodysplastic syndrome; MR, major response; ORR, overall response rate; PMF, primary myelofibrosis; PR, partial response; SM, systemic mastocytosis; SM-AHN, systemic mastocytosis associated with a hematological neoplasm; SSM, smoldering systemic mastocytosis; TKI, tyrosine kinase inhibitor; WHO, World Health Organization.

Olivier Lortholary, Olivier Hermine, Josquin Moraly, and Julien Rossignol contributed equally to this study.

For affiliations refer to page 1101

This is an open access article under the terms of the [Creative Commons Attribution-NonCommercial-NoDerivs](https://creativecommons.org/licenses/by-nc-nd/4.0/) License, which permits use and distribution in any medium, provided the original work is properly cited, the use is non-commercial and no modifications or adaptations are made.

© 2024 The Authors. *American Journal of Hematology* published by Wiley Periodicals LLC.

Center for mastocytosis (CEREMAST). All patients registered were relapsing, treatment-refractory, or ineligible for other cytoreductive therapy. Non-Adv-SM patients received imTOR as a monotherapy (rapamycin/everolimus), and Adv-SM patients received imTOR as a monotherapy or in combination with cytarabine. The objective response rate (ORR) in non-Adv-SM was 60% (partial response in 40% and major response in 20%), including reductions in skin involvement, mediator release symptoms, and serum tryptase. In the Adv-SM group, the ORR was 20% (including one major response and one partial response, both in patients with a *KIT* D816V mutation), which enabled a successful bridge to allogeneic stem cell transplantation in one patient. Our results suggest that imTOR treatment has potential benefits in patients with SM harboring a *KIT* D816V mutation.

1 | INTRODUCTION

Mastocytosis encompasses a group of myeloid disorders characterized by the accumulation of atypical mast cells (MCs). According to the World Health Organization (WHO)'s classification, mastocytosis includes cutaneous mastocytosis (CM), MC sarcoma, and systemic mastocytosis (SM).^{1,2} The latter has a broad clinical spectrum, ranging from non-advanced forms (indolent SM [ISM], bone marrow mastocytosis, and smoldering SM [SSM]) to advanced forms (aggressive SM [ASM], SM with associated hematological neoplasm [SM-AHN], and MC leukemia [MCL]).²

Although the life expectancy of most patients with ISM is normal, uncontrolled disease-related symptoms may dramatically impair their quality of life.³ Cytoreductive therapy (cladribine) for ISM is highly effective, but the median duration of a response is 44.5 months; iterative courses of treatment are required, which are associated with cumulative toxicity.⁴ The tyrosine kinase inhibitor (TKI) masitinib was efficacious and safe in a randomized prospective study but has not yet been approved for marketing.⁵ Avapritinib, a selective *KIT* D816V TKI, is active against MC activation symptoms and cutaneous mastocytosis lesions and showed a significant reduction of MC burden in 54% of patients with ISM.⁶ In contrast, advanced SM (Adv-SM) is associated with a very poor prognosis.¹ Although midostaurin has significantly lengthened survival times, 40% of patients are refractory to treatment. Furthermore, the majority of responders show disease progression after a median treatment duration of 24.0 months.⁷ Avapritinib is the gold-standard second-line treatment for these patients with progressing Adv-SM; the drug gives a high objective response rate (ORR) in all subtypes of advanced mastocytosis (Adv-SM) and a complete response in up to 36% of patients.⁸ However, some patients are not eligible because of a low platelet count. Thus, new treatment options for both severely symptomatic non-advanced SM (non-Adv-SM) and relapse-refractory Adv-SM are still needed.

In human MCs isolated from patients with SM, the *KIT* kinase domain D816V mutation and mutations affecting the juxtamembrane and extracellular domains constitutively activate the *KIT* signaling pathway. This abnormal signaling activation includes the serine-threonine kinase mammalian target of rapamycin (mTOR). The results

of our previous seminal work and subsequent studies by other groups have shown that in vitro, the mTOR inhibitor (imTOR) rapamycin specifically induces the apoptosis of D816V-mutated MCs.⁹ Adv-SMs are frequently characterized by additional mutations, which modify the mastocytosis phenotype and may be associated with a poor prognosis (particularly *SRSF2*, *RUNX1*, and *ASXL1*). *TET2* is the additional mutation most frequently found in SM-AHN.¹⁰ Mechanistically, *TET2* and *KIT* co-mutations induced aggressive MPN-like disease in a mouse model by inducing activation of the mTOR pathway.¹¹ This constitutive activation has also been demonstrated in vitro in humans, and the use of phosphatidylinositol 3-kinase inhibitors induced proliferation arrest in primary *KIT/TET2*-mutated cells.

Based on these findings and the known toxicity profile of imTORs, a number of patients with indolent or Adv-SM and who were ineligible for, refractory to, or relapsing after cytoreductive therapy or TKIs have been treated with imTOR in the network of hospitals comprising the French National Reference Center for Mastocytosis (CEREMAST). We investigated the treatment response and the molecular status (*KIT* and *TET2* mutation) of the responder patients.

2 | METHODS

2.1 | Patients

We conducted a French, nationwide, observational, open-label, non-interventional, retrospective pilot study in CEREMAST between January 1, 2006, and December 31, 2019 (Figure S1). All the treated patients had been enrolled in the prospective AFIRMM study. Written informed consent was obtained from the patients for the publication of any potentially identifiable data included in this article. The AFIRMM study had been approved by the local investigational review board (CPP Ile-de-France, France; reference: 93-00) and was carried out in compliance with the principles of the Declaration of Helsinki. The study data were collected by the CEREMAST's medical staff, using an electronic case report form. Patients were eligible for inclusion if they were aged 18 or over and suffered from mastocytosis (as defined in the WHO 2016 criteria). *KIT* mutations were assessed

TABLE 1 Characteristics of the study population.

	Total (n = 22)	Non-Adv-SM (n = 11)	Adv-SM (n = 11)
Age, median (years)	54	54	68
Sex (%)			
Male	45%	18%	73%
Female	55%	82%	27%
Mediator release symptoms			
Fatigue	95.5%	90.9%	100%
Flush	54.5%	81.8%	27.3%
Pruritus	72.7%	90.9%	54.4%
Syncope/anaphylaxis	13.6%	27.3%	9.1%
Gastrointestinal symptoms	68.2%	72.7%	63.6%
Neuropsychiatric symptoms	50.0%	72.7%	27.3%
Chronic pain	72.7%	81.8%	63.6%
Symptoms related to mast cell infiltration			
Maculopapular cutaneous lesions	72.3%	100%	54.5%
Bone involvement	52.6%	66.7%	36.4%
B-findings			
Hepatomegaly	50.0%	9.1%	90.9%
Splenomegaly	50.0%	9.1%	90.9%
Lymphadenopathy	18.2%	9.1%	27.3%
C-findings			
Ascites	18.2%	-	36.4%
Cytopenia	45.5%	-	90.9%
Weight loss with hypoalbuminemia	42.9%	-	75%
Tryptase			
Abnormal at diagnosis	85.7%	72.7%	100%
Median tryptase level at diagnosis	-	27.6 (12–94)	184.5 (64–850)
WHO classification			
ISM	45.5%	90.9%	-
SSM	4.5%	9.1%	-
SM-AHN	27.3%	-	54.4%
CMML	4.5%	-	9.1%
Multiple myeloma	4.5%	-	9.1%
MDS	13.6%	-	27.3%
PMF	4.5%	-	9.1%
ASM	4.5%	-	9.1%
MCL	18.2%	-	36.4%
KIT mutation			
D816V	95.5%	100%	72.7%
D816V Exon 9	86.4%	100%	54.5%
D816I	4.5%	0%	9.1%
D816I Exon 9	4.5%	0%	9.1%
Other mutations (N = 8 patients)			
ASXL1	-	-	75.0%
TET2	-	-	12.5%
JAK2 V617F	-	-	50.0%
SF3B1	-	-	12.5%
SRSF2	-	-	12.5%

(Continues)

TABLE 1 (Continued)

	Total (n = 22)	Non-Adv-SM (n = 11)	Adv-SM (n = 11)
<i>RUNX1</i>			12.5%
Previous treatments	86%	81.8%	90.9%
Lines of treatment, median	2 (0–4)	2	2
Interferon alpha	27.3%	36.4%	18.2%
Cladribine	54.5%	72.7%	36.4%
Imatinib/dasatinib	18.2%	18.2%	18.2%
Thalidomide	18.2%	18.2%	18.2%
Masitinib	36.4%	54.5%	18.2%
Midostaurin	27.3%	0%	54.5%
Gemtuzumab ozogamicin	4.5%	0%	9.1%

Abbreviations: ASM, aggressive systemic mastocytosis; CMML, chronic myelomonocytic leukemia; ISM, indolent systemic mastocytosis; MCL, mast cell leukemia; MDS, myelodysplastic syndrome; PMF, primary myelofibrosis; SM, systemic mastocytosis; SM-AHN: systemic mastocytosis associated with a hematological neoplasm; SSM, smoldering systemic mastocytosis.

with droplet digital PCRs or Sanger sequencing. The *TET2* mutation was assessed with next-generation sequencing.

2.2 | Treatments and outcomes

Treatment consisted of imTOR monotherapy in 17/22 patients (Figure S1). 15 patients received sirolimus at a starting dose of 2 mg/day (targeting levels of 5–15 ng/mL), and two patients received everolimus at a starting dose of 0.75 mg/12 h. Furthermore, five patients with Adv-SM received temsirolimus at a dose of 25 mg/m² on days 1, 8, 15, and 21, together with high-dose cytarabine (2000 mg/m²/day for 1 or 2 days); this was defined as one course of treatment. All patients were closely monitored with regard to creatinine levels, lipid profile, plasma imTOR levels, BST (basal serum tryptase) levels, and clinical signs and symptoms. Efficacy and safety data were recorded in the CEREMAST database and analyzed retrospectively. All patients were included in the safety analysis, whereas only patients who have received either at least one course of temsirolimus + cytarabine or 28 days of imTOR monotherapy were included in the efficacy analysis (Figure S1). Responses were assessed according to previously described criteria.¹²

2.3 | Statistical analyses

Statistical analyses were performed using GraphPad Prism software (version 6.0; GraphPad Software, Inc, La Jolla, CA). Data were expressed as the mean or median (range).

3 | RESULTS AND DISCUSSION

Overall, 22 patients were eligible for the study: 11 with non-Adv-SM (10 with ISM and 1 with SSM) and 11 with Adv-SM (6 SM-AHN,

4 MCL, and 1 ASM) (Table 1). The associated hematological neoplasms were chronic myelomonocytic leukemia (*n* = 1), myelodysplastic syndromes (*n* = 3), primary myelofibrosis (*n* = 1), and multiple myeloma (*n* = 1). The median age in the non-Adv-SM and Adv-SM groups was 54 and 68, respectively. As expected, symptoms were frequent in the non-Adv-SM group, including MC activation symptoms: 82% had flushes, 91% had pruritus, 73% had gastrointestinal symptoms, and all patients had maculopapular cutaneous mastocytosis lesions. In the Adv-SM, all 11 patients presented at least one C-finding (including 91% of the patients with cytopenia and 75% with weight loss and hypoalbuminemia). The BST level was elevated in 73% of the patients with non-Adv-SM (median: 28 ng/mL) and high in all the patients in the Adv-SM group (median [range]: 185 (64–850) ng/mL). The *KIT* D816V mutation was found in all patients with non-Adv-SM and in 55% of the patients with Adv-SM (37% of whom were wild type for *KIT*). Additional mutations were found in 72% of the patients with Adv-SM: *TET2* mutations were the most frequent (43%), followed by high-risk mutations (*ASXL1* in one patient, *RUNX1* in another patient, and two patients with *SRSF2* mutation) and *JAK2* in a patient with primary myelofibrosis (Table 1).

Overall, 91% of the patients with non-Adv-SM and 82% of the patients with Adv-SM had already received cytoreductive therapy or TKI(s) with a median of two previous lines of treatment. Cladribine was the most frequent treatment prior to imTOR initiation in patients with non-Adv-SM, whereas 55% of the patients with advanced SM had received midostaurin. Patients who had not been previously treated were not eligible for both cytoreductive therapy and TKI(s) available at that time. None of the patients had previously received allogeneic bone marrow transplant. The median duration of treatment with an imTOR was 2.9 months (range: 0.4–37.3). Two patients withdrew early (due to an adverse drug reaction) and so were excluded from our efficacy analysis. In non-Adv-SM patients treated with imTOR monotherapy, the ORR was 60%: 4/10 of the patients had a partial response (PR), and 2/10 had a major response (MR). Decreases in skin involvement and mediator release symptoms were the features

TABLE 2 Selected illustrative cases of non-advanced mastocytosis (Adv-SM) or Adv-SM response.

Cases	SM subtype	Treatment	Response according to consensus criteria	Response features	Duration of treatment	Cause of treatment withdrawal
Case 4	ISM	Rapamycin	Partial response	Decrease in neuropsychological symptoms and fatigue Decrease in BST (–68%)	8 months	Progression
Case 5	ISM	Rapamycin	Partial response	Decrease in skin involvement and inflammation Disappearance of Darier's sign Decrease in BST (–31%)	21+ months	On treatment at last follow-up
Case 6	ISM	Rapamycin	Partial response	Decrease in skin involvement and inflammation Baseline and post-treatment BST <20 ng/mL	37 months	Progression
Case 8	SSM	Rapamycin	Major response	Decrease in skin involvement (>50%) and splenomegaly Disappearance of pruritus, flushes, and diarrhea Decrease in BST (–90%)	91+ months	On treatment at last follow-up
Case 9	ISM	Rapamycin	Partial response	Decrease in skin involvement, inflammation, and flushes Decrease in BST (–73%)	32+ months	On treatment at last follow-up
Case 10	ISM	Everolimus	Major response	Disappearance of recurrent laryngeal edema, flushes, and diarrhea Decrease in skin involvement Baseline and post-treatment BST <20 ng/mL	6 months	ND
Case 12	SM-AHN (MDS)	Temsirolimus Cytarabine	Partial response	Transfusion independence Decrease in BST (–50%) and mediator release symptoms	4 courses	Progression
Case 15	SM-AHN (PMF)	Everolimus	No response	Decrease in skin involvement Decrease (>50%) in hepatomegaly and splenomegaly BST: no data	8 months	Metastatic cancer
Case 17	ASM	Rapamycin	No response	Decrease in skin involvement BST: no data	5 months	ND
Case 18	MCL	Temsirolimus Cytarabine	Major response	Complete resolution of ascites, hyperleukocytosis, and % mast cells on a blood smear Decrease in organomegaly and bone marrow infiltrates Decrease in BST (–88%)	3 courses	Allo-BMT
Case 19	MCL	Temsirolimus Cytarabine	No response	Tumor lysis syndrome Decrease in % mast cells on a bone marrow smear from 50% to 20% No decrease in BST (+18.5%)	1.5 courses	Progression

Note: “+” indicates that the patient is still being treated.

Abbreviations: ASM, aggressive systemic mastocytosis; ISM, indolent systemic mastocytosis; MCL, mast cell leukemia; MDS, myelodysplastic syndrome; ND, no data; PMF, primary myelofibrosis; SM, systemic mastocytosis; SM-AHN, systemic mastocytosis associated with a hematological neoplasm.

that responded best to treatment (Table 2 and Figure 1). In non-Adv-SM responders, BST levels showed a >30% decrease after treatment in 4/4 patients with baseline BST > 20 ng/mL (Table 2). The

median time to best response was 5.5 months, and five of 10 patients with non-Adv-SM experienced long-term responses (>10 months, Table 2). As an example, the first ISM patient treated with imTOR was

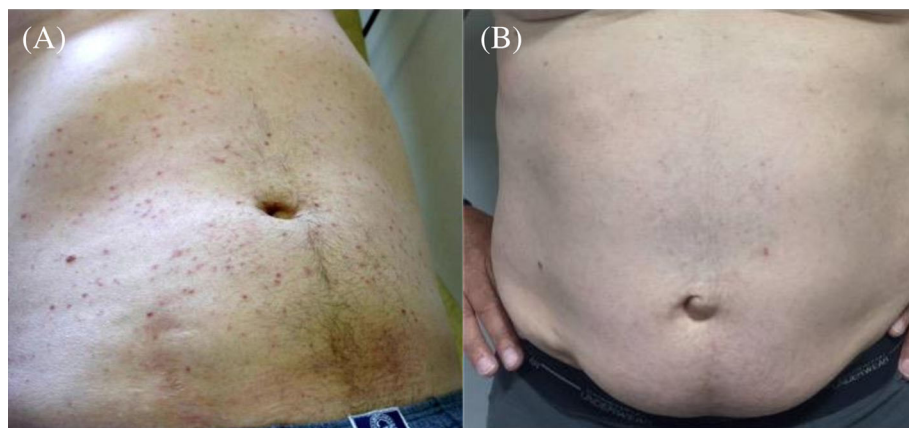


FIGURE 1 A patient with indolent systemic mastocytosis and maculopapular cutaneous mastocytosis (case 9) before mTOR pathway inhibitor (imTOR) treatment (A) and after imTOR treatment (B). [Color figure can be viewed at wileyonlinelibrary.com]

suffering from refractory laryngeal edema, which led to a requirement for frequent subcutaneous injections of adrenalin and a recommendation of tracheotomy. This patient was successfully treated for more than 2 years: all the signs and symptoms resolved, with no need for additional treatment and no tracheotomy. In the Adv-SM group, the ORR was 20% according to the consensus criteria with one PR and one MR, in two patients treated with the combination of temsirolimus and cytarabine. Five additional patients showed objective response features (decreases in organomegaly, skin involvement, or the percentage of MCs on a bone marrow smear) but did not meet the stringent criteria (Table 2). The median overall survival time of patients with Adv-SM was 40.1 months (Figure 2). A patient with midostaurin refractory MCL achieved a major response after three courses of temsirolimus and cytarabine, which enabled successful haplo-identical allogeneic stem cell transplantation. No response was observed among the three patients without a *KIT* D816 mutation. In the Adv-SM group, the two patients who responded significantly to imTOR therapy had *KIT* D816V mutation, but only one had *TET2* mutations.

In the monotherapy group ($n = 17$), the most common adverse event was dyslipidemia, followed by diarrhea and leg edema. Diabetes mellitus was found in one patient after 41 months of treatment. Acute reversible kidney injury was observed in two patients with pre-existing chronic kidney failure. In the combination therapy group ($n = 5$), the most common adverse event was cytopenia: febrile neutropenia occurring in four patients. Two patients experienced acute renal dysfunction with several causes. Lastly, we observed one case of reversible interstitial pneumonitis.

The objective of the present study was to investigate the efficacy and safety of imTOR in patients with mastocytosis. Preclinical data suggested that imTOR are active against human MCs with a *KIT* D816V mutation and are perhaps effective in Adv-SM with *KIT/TET2* mutations.^{9–11} ImTORs showed clinical efficacy in a subset of patients with non-Adv-SM or Adv-SM having failed to respond to at least two lines of treatment or ineligible for other treatments. Reductions in skin lesions, mediator release symptoms, and BST were particularly noted in the non-Adv-SM group following imTOR monotherapy. In the Adv-SM group, responses to imTORs were only observed in combination with cytarabine. As expected from the preclinical studies, patients who

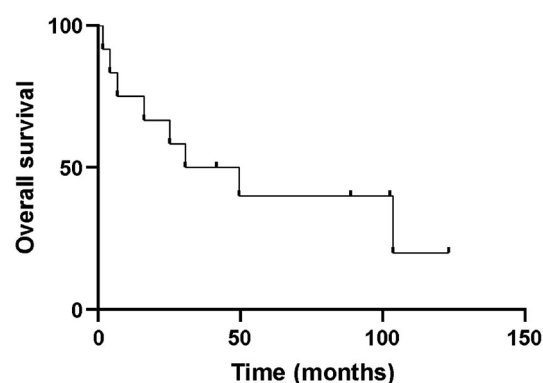


FIGURE 2 Overall survival of mTOR pathway inhibitor-treated patients with advanced systemic mastocytosis.

lacked the *KIT* D816V mutation did not respond to imTORs. *TET2* mutation might not be associated with response as only 1/4 patient with *TET2* mutated SM responded to therapy and in the two Adv-SM patients who responded, *TET2* mutation was found in only one patient. In 2010, Parikh et al. reported on everolimus treatment at the MD Anderson Cancer Center: all the symptoms improved in 4/7 patients with ISM.¹³ Given the lack of significant reductions in the BST level and MC infiltration, Parikh et al. concluded that imTORs were of no benefit—in contrast to our own experience. In line with the report of Parikh et al., we only observed a decrease in the BST level in the combination therapy in Adv-SM. However, in patients with Adv-SM, a combination of an imTOR with high-dose cytarabine might constitute a bridge to allogeneic stem cell transplantation in patients with *KIT*-mutated SM. Furthermore, we have found that the safety profile of imTOR (rapamycin and everolimus) monotherapy (in 15 of 17 patients) was better than that reported by Parikh et al. with everolimus and therefore enabled treatment with the imTOR for longer periods.¹²

Despite the small study population and the study's retrospective design, we conclude that imTORs might constitute a treatment option for mastocytosis. Further prospective studies are urgently needed to confirm this efficacy and probe potential synergism with cytoreductive therapies.

AFFILIATIONS

- ¹Infectious and Tropical Diseases Department, Necker-Pasteur Infectiology Center, Necker-Enfants Malades Hospital, AP-HP, Paris, France
- ²Reference Center for Mastocytosis (CEREMAST), Necker-Enfants Malades Hospital, AP-HP, Paris, France
- ³INSERM U1163, Imagine Institute, Paris-Cite University, Necker-Enfants Malades Hospital, AP-HP, Paris, France
- ⁴Department of Hematology, Necker-Enfants Malades Hospital, AP-HP, Paris, France
- ⁵Laboratory of Onco-Hematology, Necker-Enfants Malades Hospital, AP-HP, Paris, France
- ⁶Department of Pathology, Necker-Enfants Malades Hospital, AP-HP, Paris, France
- ⁷Department of Pathology, Necker-Children's Hospital, AP-HP, Paris Centre University, Paris, France
- ⁸Department of Dermatology, Pitié-Salpêtrière Hospital, AP-HP, Paris, France
- ⁹Department of Dermatology, Necker-Enfants Malades Hospital, AP-HP, Paris, France
- ¹⁰Department of Internal Medicine and Clinical Immunology, Claude Huriez Hospital, CHRU Lille, Lille, France
- ¹¹Clinical Immunology/Internal Medicine Department, National Reference Center for Angioedema, Grenoble University Hospital, Grenoble, France
- ¹²Department of Dermatology, Aix-Marseille University, CHU Timone, Marseille, France
- ¹³Department of Internal Medicine, Centre Hospitalier Bretagne Atlantique, Vannes, France
- ¹⁴Department of Internal Medicine and Clinical Immunology, Rennes University Hospital, Rennes, France
- ¹⁵Department of Internal Medicine, Hôtel-Dieu University Hospital, Nantes, France
- ¹⁶Department of Hematology, Nancy University Hospital, Nancy, France
- ¹⁷Department of Internal Medicine and Clinical Immunology, Nancy University Hospital, Vandoeuvre-lès-Nancy, France
- ¹⁸Department of Internal Medicine-Multi-Organ Diseases, Saint-Eloi University Hospital, Montpellier University, Montpellier, France
- ¹⁹INSERM, U1068, Centre de Recherche en Cancérologie de Marseille (CRCM), Paoli-Calmettes Institute, Marseille, France
- ²⁰Department of Pain and Palliative Care Unit, Necker-Children's Hospital, AP-HP, Paris Centre University, Paris, France
- ²¹Department of Hematology, CHU de Bordeaux, Bordeaux, France
- ²²Department of Hematology, Lyon-Sud Hospital, Hospices Civils de Lyon, Pierre-Bénite, France
- ²³Department of Hematology, Amiens University Hospital, Amiens, France
- ²⁴Adult Clinical Hematology, CHU Clermont-Ferrand, INSERM CIC501, EA 7453 - Clermont Auvergne University, Clermont-Ferrand, France
- ²⁵Department of Rheumatology, Strasbourg University Hospital, Strasbourg, France

- ²⁶Department of Dermatology, Allergology Unit, University Hospital of Besançon, Besançon, France
- ²⁷Department of Hematology, Sud Reunion University Hospital, Saint Pierre, La Réunion, France
- ²⁸Department of Hematology, CHU Dupuytren, Limoges, France
- ²⁹Department of Dermatology, CHU de Poitiers, Poitiers, France
- ³⁰Department of Hematology, CHU de Poitiers, Poitiers, France
- ³¹Department of Dermatology, Hôpital Larrey, CHU Toulouse, Toulouse, France
- ³²Department of Internal Medicine and Clinical Immunology, University Hospital, Angers, France
- ³³Department of Clinical Immunology and Allergology, Centre Hospitalier Régional Universitaire, Tours, France
- ³⁴Laboratory of Hematology, Pitié-Salpêtrière Hospital, AP-HP, Paris, France
- ³⁵Hematology Institute, Normandy University School of Medicine, Caen, France

CONFLICT OF INTEREST STATEMENT

The authors declare that they do not have any conflicts of interest with regard to this work.

DATA AVAILABILITY STATEMENT

All data generated or analyzed during this study are included in this published article.

ORCID

- Josquin Moraly  <https://orcid.org/0000-0002-8551-9658>
- Marie Gousseff  <https://orcid.org/0000-0003-1806-7986>
- Florence Castelain  <https://orcid.org/0000-0003-0334-8486>
- Christian Lavigne  <https://orcid.org/0000-0002-2538-0076>
- Gandhi Damaj  <https://orcid.org/0000-0002-4689-3882>

REFERENCES

- Valent P, Akin C, Metcalfe DD. Mastocytosis: 2016 updated WHO classification and novel emerging treatment concepts. *Blood*. 2017; 129:1420-1427. doi:10.1182/blood-2016-09-731893
- Arber DA, Orazi A, Hasserjian R, et al. The 2016 revision to the World Health Organization classification of myeloid neoplasms and acute leukemia. *Blood*. 2016;127:2391-2405. doi:10.1182/blood-2016-03-643544
- Hermine O, Lortholary O, Leventhal PS, et al. Case-control cohort study of patients' perceptions of disability in mastocytosis. *PLoS One*. 2008;3:e2266. doi:10.1371/journal.pone.0002266
- Barete S, Lortholary O, Damaj G, et al. Long-term efficacy and safety of cladribine (2-CdA) in adult patients with mastocytosis. *Blood*. 2015; 126:1009-1016. doi:10.1182/blood-2014-12-614743
- Lortholary O, Chandesris MO, Livideanu CB, et al. Masitinib for treatment of severely symptomatic indolent systemic mastocytosis: a randomised, placebo-controlled, phase 3 study. *Lancet*. 2017;389: 612-620. doi:10.1016/S0140-6736(16)31403-9
- Gotlib J, Castells M, Elberink HO, et al. Avapritinib versus placebo in indolent systemic mastocytosis. *NEJM Evid*. 2023;2:2. doi:10.1056/EVIDoa2200339
- Gotlib J, Kluin-Nelemans HC, George TI, et al. Efficacy and safety of midostaurin in advanced systemic mastocytosis. *N Engl J Med*. 2016; 374:2530-2541. doi:10.1056/NEJMoa1513098

8. DeAngelo DJ, Radia DH, George TI, et al. Safety and efficacy of avapritinib in advanced systemic mastocytosis: the phase 1 EXPLORER trial. *Nat Med*. 2021;27:2183-2191. doi:[10.1038/s41591-021-01538-9](https://doi.org/10.1038/s41591-021-01538-9)
9. Gabillot-Carre M. Rapamycin inhibits growth and survival of D816V-mutated c-kit mast cells. *Blood*. 2006;108:1065-1072. doi:[10.1182/blood-2005-06-2433](https://doi.org/10.1182/blood-2005-06-2433)
10. Jawhar M, Schwaab J, Schnittger S, et al. Additional mutations in SRSF2, ASXL1 and/or RUNX1 identify a high-risk group of patients with KIT D816V+ advanced systemic mastocytosis. *Leukemia*. 2016;30:136-143. doi:[10.1038/leu.2015.284](https://doi.org/10.1038/leu.2015.284)
11. Palam LR, Mali RS, Ramdas B, et al. Loss of epigenetic regulator TET2 and oncogenic KIT regulate myeloid cell transformation via PI3K pathway. *JCI Insight*. 2018;3:e94679. doi:[10.1172/jci.insight.94679](https://doi.org/10.1172/jci.insight.94679)
12. Valent P, Akin C, Escribano L, et al. Standards and standardization in mastocytosis: consensus statements on diagnostics, treatment recommendations and response criteria. *Eur J Clin Invest*. 2007;37:435-453. doi:[10.1111/j.1365-2362.2007.01807.x](https://doi.org/10.1111/j.1365-2362.2007.01807.x)
13. Parikh SA, Kantarjian HM, Richie MA, Cortes JE, Verstovsek S. Experience with everolimus (RAD001), an oral mammalian target of rapamycin inhibitor, in patients with systemic mastocytosis. *Leuk Lymphoma*. 2010;51:269-274. doi:[10.3109/10428190903486220](https://doi.org/10.3109/10428190903486220)

SUPPORTING INFORMATION

Additional supporting information can be found online in the Supporting Information section at the end of this article.

How to cite this article: Moraly J, Rossignol J, Rouzaud C, et al. Efficacy and safety of mammalian target of rapamycin inhibitors in systemic mastocytosis: A nationwide French pilot study. *Am J Hematol*. 2024;99(6):1095-1102. doi:[10.1002/ajh.27323](https://doi.org/10.1002/ajh.27323)